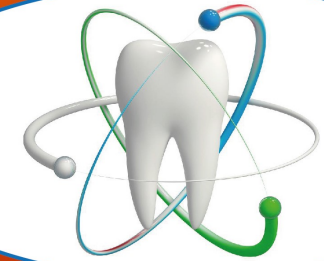



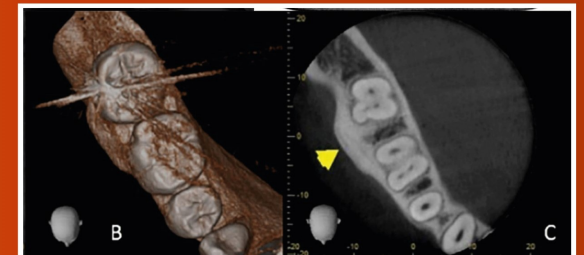
CUMHURİYET



DENTAL JOURNAL

The Official Journal of Sivas Cumhuriyet University Faculty of Dentistry

**Editor-in-Chief**  
İhsan Hubbezoğlu  
**Co-Editor-in-Chief**  
Burak Buldur



Volume : 23  
ISSN : 1302-5805

Issue : 1  
e-ISSN : 2146-2852

2020

## Cumhuriyet Dental Journal

The Official Journal of the Sivas Cumhuriyet University Faculty of Dentistry. The first issue was published in 1998 and journal's name was changed as Cumhuriyet Dental Journal in 2010. Issues are published quarterly since 2018.

### Aims and Scope

Cumhuriyet Dental Journal (CDJ) is an international journal dedicated to the latest advancement of dentistry. The aim of this journal is to provide a platform for scientists and academicians all over the world to promote, share, and discuss various new issues and developments in different areas of dentistry.

CDJ publishes original research papers, reviews, and case reports within clinical dentistry, on all basic science aspects of structure, chemistry, developmental biology, physiology and pathology of relevant tissues, as well as on microbiology, biomaterials and the behavioral sciences as they relate to dentistry.



Please visit <http://dergipark.gov.tr/cumudj> to see homepage and related information about CDJ.

ISSN 1302-5805

e-ISSN 2146-2852

Volume/23- Issue/1-2020

### Owner/Editor-in-Chief

Ihsan Hubbezoğlu Department of Restorative Dentistry, Faculty of Dentistry, Cumhuriyet University, Sivas, Turkey

### Co -Editor-in-Chief

Burak Buldur Department of Pediatric Dentistry, Faculty of Dentistry, Sivas Cumhuriyet University, Sivas, Turkey

### Associate Editors

Gulce Cakmak Department of Prosthetic Dentsity, Mexico Unam University,Ciudad de México, Mexico  
Mine Koruyucu Department of Pediatric Dentistry, Faculty of Dentistry, Istanbul University, Sivas, Turkey  
Derya O. Doğan Department of Prosthetic Dentsity, Faculty of Dentistry, Sivas Cumhuriyet University, Sivas,Turkey  
Recai Zan Department of Endodontics, Faculty of Dentistry, Sivas Cumhuriyet University, Sivas, Turkey  
Oguzhan Gorler Department of Prosthetic Dentsity, Faculty of Dentistry, Sivas Cumhuriyet University, Sivas, Turkey

### Statistical Editor

Ziynet Cinar Department of Biostatistics, Faculty of Dentistry, Sivas Cumhuriyet University, Sivas, Turkey

### Editorial Board

John Nicholson Queen Mary University of London, United Kingdom  
Alessandro Cavalcanti State University of Paraiba, Grande, Brazil  
Marco Tatullo Tecnologica Research Institute, Crotone, Italy  
Zafer Cehreli Hacettepe University, Ankara, Turkey  
Satyawan Damle Maharishi Markandeshwar University, Mullana, India  
Mutlu Ozcan University of Zurich,Zurich, Switzerland  
M. Hossein Nekoofar Tehran University of Medical Sciences, Tehran, Iran  
Marc Saadia Tufts University, Boston, USA  
Kaan Orhan University of Leuven, Leuven, Belgium  
Wei Cheong Ngeow University of Malaya, Kuala Lumpur, Malaysia

### Writing Manager

Vildan Bostancı Department of Periodontology, Faculty of Dentistry, Sivas Cumhuriyet University, Sivas, Turkey

### Secretary

Serap Bekis Editorial Office, Faculty of Dentistry, Sivas Cumhuriyet University, 58140, Sivas, Turkey

e-mail: [cdj@cumhuriyet.edu.tr](mailto:cdj@cumhuriyet.edu.tr) Phone: +90 346 2191010 / 2730 (ext)

### INDEXING



## CUMHURIYET DENAL JOURNAL

### AUTHOR GUIDELINE

Cumhuriyet Dental Journal (CDJ) is the Official Publication of the Cumhuriyet University, Faculty of Dentistry. CDJ accepts original experimental investigations and review articles concerning topics of clinical relevance to the general dental practitioner. Case reports and technique articles will be very critically reviewed in terms of interest to the general dental practitioner and the supporting data provided.

**CDJ accepts articles in English. Submitting a paper to CDJ is free of charges. In addition, CDJ has not have article processing charges.**

**Frequency: Four times a year (March, June, September, and December)**

CDJ is published using an open access publication model, meaning that all interested readers are able to freely access the journal online without the need for a subscription. Manuscripts will be reviewed by the editor, and at least two reviewers with expertise within the scope of the article. In addition, CDJ use double-blind review process (every effort is made to prevent the identities of the authors and reviewers from being known to each other)

#### **Review Process**

##### ***Double-Blind Peer Review Process***

CDJ uses double-blind review, which means that both the reviewer and author identities are concealed from the reviewers, and vice versa, throughout the review process. Within this aim, the authors need to ensure that their manuscripts are prepared in a way that does not give away their identity. Editors will email selected Reviewers the title and abstract of the submission, as well as an invitation to log into the journal web site to complete the review. Reviewers enter the journal web site to agree to do the review, to download submissions, submit their comments, and select a recommendation.

The typical period of time allowed for reviews: 6 weeks which can be modified during the editorial process.

Reviewers will have access to the submission file only after agreeing to review it.

#### **Language**

**The publication language is English.** Authors whose native language is not English should obtain the assistance of an expert in English and scientific writing before submitting their manuscripts. Manuscripts that do not meet basic language standards will be returned pre-review. Authors are requested to submit their original manuscript and figures via the online submission and editorial system for Cumhuriyet Dental Journal. Using this online system, authors may submit manuscripts and track their progress through the system to publication. Reviewers can download manuscripts and submit their opinions to the editor. Editors can manage the whole submission/review/revise/publish process.

#### **Manuscript Format and Style**

##### ***General***

Manuscript length depends on manuscript type. Paper dimensions should be 8.5 × 11 inches with 2.5 cm margins on all sides. Please use normal, plain font (12-point Times New Roman), justified and number all pages consecutively. Indent or space paragraphs.

##### ***Manuscript Types Accepted***

**Original Research Article:** Title, Abstract, Introduction, Materials and Methods, Results, Discussion, Conclusions, Acknowledgements, References, Tables and Figure Legends

**Review Articles:** Although a Review article (particularly following a systematic review) may adhere to the format of the Original Research Article, both Review and Focus Articles need not contain Materials and Methods, Results or Discussion sections, and may instead employ other headings as relevant for the topic addressed.

**Case Report:** Title, Abstract, Introduction, Case Report, Discussion, Conclusions, Acknowledgements, References, Tables and Figure Legends

#### **Manuscript Submission Procedure**

##### **Submission site**

Manuscripts should be submitted online through <http://dergipark.gov.tr/cumudj>. Full instructions and support are available on the website, and a *user ID* and *password* can be obtained at the first visit. All parts of the manuscript (Main Document, Tables, Figures and Supplemental Information) must be available in an electronic format: Microsoft Word or generic RTF are recommended for text and tables; and TIFF or EPS for graphics (see under Figures).

## **ELEMENTS OF a MANUSCRIPT**

### **1. Title Page**

- **Title page must be uploaded apart from manuscript and should include;**
- -Title
- -Authors (first name, middle initial, surname) e.g. Burak Buldur, DDS, PhD,<sup>a</sup>
- -Authors' addresses (abbreviated) e.g.
- <sup>a</sup> Associate Professor Dr., Department of Pediatric Dentistry, Faculty of Dentistry, Cumhuriyet University, Sivas, Turkey.
- **ALL AUTHORS' ORCID NUMBERS** must be included
- A running title, not exceeding 50 letters and spaces
- Corresponding Author details including name, complete address, phone, fax, and e-mail must be added.

### **Main Document**

The main document includes, in a single electronic file (Word/text file, not pdf).

### **2. Abstract**

- Should not exceed 300 words and should be presented under the following subheadings:

Research Articles: Objectives, Materials and Methods; Results; Conclusions

Reviews and Case Reports: Provide a short, nonstructured, 1-paragraph abstract that briefly summarizes the study.

### **3. Keywords**

- Up to 5 keywords should be supplied according to **MESH**.

### **4. Introduction**

- This must be presented in a structured format, covering the following subjects, although not under subheadings: succinct statements of the issue in question; the essence of existing knowledge and understanding pertinent to the issue; and the aims and objectives of the research being reported.

### **5. Materials and methods**

- The authors should describe the procedures and analytical techniques and identify names and sources of all commercial products e.g. magnetic attachment (Hyper Slim 5513, Hitachi Metals, Tokyo, Japan )

### **6. Results**

- The authors should refer to appropriate tables and figures and report statistical findings.

### **7. Discussion**

- The authors should discuss the results of the study also state the agreement with other studies and identify the limitations of the present study and suggest areas for future research.

### **8. Conclusions**

- The authors should concisely list conclusions that may be drawn from the research and do not simply restate the results.

### **9. Acknowledgements**

- If the work was supported by a grant or any other kind of funding, supply the name of the supporting organization and the grant number.

### **10. Conflicts of Interest statement**

- Specify any potential conflict of interests, or state no conflicts of interest.

### **11. References**

- References must be identified in the body of the article with superscript Arabic numerals after punctuation marks.
- The complete reference list must be double spaced and in numerical order and should start on a separate page. Only references cited in the text should appear in the reference list.
- Unpublished data or personal communications are not accepted.

Examples for Journal reference style: (Author. Title. Journal Abbrev Year;Volume:Pages)

Buldur B, Oznurhan F, Kayabasi M, Sahin F. Shear bond strength of two calcium silicate-based cements to compomer. Cumhuriyet Dent J 2018;21:18-23

Examples for Book reference style:

Hilton TJ. Direct posterior composite restorations. In: Schwartz RS, Summitt JB, Robbins JW (eds). *Fundamentals of Operative Dentistry*. Chicago: Quintessence 1996:207-228.

### **12. Tables**

- All tables must be thoroughly discussed in the text of the manuscript.
- The authors should put one table to a page, each with a title and -number tables in order of mention using Arabic numerals.
- Tables must be uploaded at the end of the main text and for explanatory footnotes, symbols (\*, #, \*\*, ##) must be used.

### **13. Figures**

- The authors should do not import the figures into the text and should be saved in jpeg format.
- All graphs, drawings, and photographs are considered Figures and should be numbered in sequence with Arabic numerals.
- Figures should be planned to fit the proportions of the printed page (width 17 cm) or one column (width 8 cm) and be legible at this size.
- Figures grouped together should have similar dimensions and be labelled "A, B, C", etc.
- Colour and black-and-white photographs should be created and saved at a minimum of 300 dots per inch (dpi).
- Please name each electronic image file. For example, a Figure 1 in jpeg format should be named fig 1. Multipart figures must be clearly identifiable by the file names: fig 1A, fig 1B, fig 1C, etc.

### **14. Figure legends**

- The authors should list together on a separate page and include key for symbols or abbreviations used in Figures.

### **COPYRIGHT TRANSFER AGREEMENT**

Cumhuriyet Dental Journal provides free access to and allows free download of its contents from the journal's website (<http://dergipark.gov.tr/cumudj>). Both anonymous or registered users can read and/or download articles. Unless otherwise indicated, the articles and journal content are licensed under Creative Commons Attribution-Gayriticari-NoDerivs 3.0 Unported Licence. International (CC BY-NC-ND 3.0) license <https://creativecommons.org/licenses/by-nc-nd/3.0/>.

### **OPEN ACCESS POLICY**

An old tradition and a new technology have converged to make possible an unprecedented public good. The old tradition is the willingness of scientists and scholars to publish the fruits of their research in scholarly journals without payment, for the sake of inquiry and knowledge. The new technology is the internet. The public good they make possible is the world-wide electronic distribution of the peer-reviewed journal literature and completely free and unrestricted access to it by all scientists, scholars, teachers, students, and other curious minds. Removing access barriers to this literature will accelerate research, enrich education, share the learning of the rich with the poor and the poor with the rich, make this literature as useful as it can be, and lay the foundation for uniting humanity in a common intellectual conversation and quest for knowledge.

For various reasons, this kind of free and unrestricted online availability, which we will call open access, has so far been limited to small portions of the journal literature. But even in these limited collections, many different initiatives have shown that open access is economically feasible, that it gives readers extraordinary power to find and make use of relevant literature, and that it gives authors and their works vast and measurable new visibility, readership, and impact. To secure these benefits for all, we call on all interested institutions and individuals to help open up access to the rest of this literature and remove the barriers, especially the price barriers, that stand in the way. The more who join the effort to advance this cause, the sooner we will all enjoy the benefits of open access.

The literature that should be freely accessible online is that which scholars give to the world without expectation of payment. Primarily, this category encompasses their peer-reviewed journal articles, but it also includes any unreviewed preprints that they might wish to put online for comment or to alert colleagues to important research findings. There are many degrees and kinds of wider and easier access to this literature. By "open access" to this literature, we mean its free availability on the public internet, permitting any users to read, download, copy, distribute, print, search, or link to the full texts of these articles, crawl them for indexing, pass them as data to software, or use them for any other lawful purpose, without financial, legal, or technical barriers other than those inseparable from gaining access to the internet itself. The only constraint on reproduction and distribution, and the only role for copyright in this domain, should be to give authors control over the integrity of their work and the right to be properly acknowledged and cited.

While the peer-reviewed journal literature should be accessible online without cost to readers, it is not costless to produce. However, experiments show that the overall costs of providing open access to this literature are far lower than the costs of traditional forms of dissemination. With such an opportunity to save money and expand the scope of dissemination at the same time, there is today a strong incentive for professional associations, universities, libraries, foundations, and others to embrace open access as a means of advancing their missions. Achieving open access will require new cost recovery models and financing mechanisms, but the significantly lower overall cost of dissemination is a reason to be confident that the goal is attainable and not merely preferable or utopian.

To achieve open access to scholarly journal literature, we recommend two complementary strategies.

**I. Self-Archiving:** First, scholars need the tools and assistance to deposit their refereed journal articles in open electronic archives, a practice commonly called, self-archiving. When these archives conform to standards created by the Open Archives Initiative, then search engines and other tools can treat the separate archives as one. Users then need not know which archives exist or where they are located in order to find and make use of their contents.

**II. Open-access Journals:** Second, scholars need the means to launch a new generation of journals committed to open access, and to help existing journals that elect to make the transition to open access. Because journal articles should be disseminated as widely as possible, these new journals will no longer invoke copyright to restrict access to and use of the material they publish. Instead they will use copyright and other tools to ensure permanent open access to all the articles they publish. Because price is a barrier to access, these new journals will not charge subscription or access fees, and will turn to other methods for covering their expenses. There are many alternative sources of funds for this purpose, including the foundations and governments that fund research, the universities and laboratories that employ researchers, endowments set up by discipline or institution, friends of the cause of open access, profits from the sale of add-ons to the basic texts, funds freed up by the demise or cancellation of journals charging traditional subscription or access fees, or even contributions from the researchers themselves. There is no need to favor one of these solutions over the others for all disciplines or nations, and no need to stop looking for other.

Open access to peer-reviewed journal literature is the goal. Self-archiving (I.) and a new generation of open-access journals (II.) are the ways to attain this goal. They are not only direct and effective means to this end, they are within the reach of scholars themselves, immediately, and need not wait on changes brought about by markets or legislation. While we endorse the two strategies just outlined, we also encourage experimentation with further ways to make the transition from the present methods of dissemination to open access. Flexibility, experimentation, and adaptation to local circumstances are the best ways to assure that progress in diverse settings will be rapid, secure, and long-lived.

The Open Society Institute, the foundation network founded by philanthropist George Soros, is committed to providing initial help and funding to realize this goal. It will use its resources and influence to extend and promote institutional self-archiving, to launch new open-access journals, and to help an open-access journal system become economically self-sustaining. While the Open Society Institute's commitment and resources are substantial, this initiative is very much in need of other organizations to lend their effort and resources.

We invite governments, universities, libraries, journal editors, publishers, foundations, learned societies, professional associations, and individual scholars who share our vision to join us in the task of removing the barriers to open access and building a future in which research and education in every part of the world are that much more free to flourish. Submitting a paper to CDJ is free of charges. In addition, CDJ has not have article processing charges.

### ***PLAGIARISM and ETHICS***

CDJ aims to the highest standards with regard to research integrity and in particular the avoidance of plagiarism, including self-plagiarism. It is therefore essential that authors, before they submit a paper, particular attention should be paid. When submitting a paper on CDJ, authors will be prompted as to whether they have read and agree to these guidelines before proceeding further with their submission. They will be asked specifically for an assurance that the paper contains no element of data fabrication, data falsification or plagiarism (including unacknowledged self-plagiarism). Authors are reminded that, where they draw upon material from another source, they must either put that material in the form of a quote OR write it entirely in their own words (i.e. there is no 'middle way'). In both cases, they must explicitly cite the source, including the specific page number in the case of a quote or a particular point. **CDJ uses Ithenticate: Plagiarism Detection Software.**

For the experimental, clinical and drug human studies, approval by ethical committee and statement on the adherence of the study protocol to the international agreements (Helsinki Declaration revised 2008) are required. In experimental animal studies, the authors should indicate that the procedures followed were in accordance with animal rights and they should obtain animal ethic committee approval. The Ethic Committee approval document should be submitted to the Cumhuriyet Dental Journal together with the manuscript.

The approval of the ethic committee, statement on the adherence to international guidelines mentioned above and that the patients' informed consent is obtained should be indicated in the "Materials and Methods" section and is required for case reports whenever data/media used could reveal identity of the patient. The declaration of the conflict of interest between authors, institutions, acknowledgement of any financial or material support, aid is mandatory for authors submitting manuscript and the statement should appear at the end of manuscript. Reviewers are required to report if any potential conflict of interest exists between reviewer and authors, institutions.

## CONTENTS

### **EDITORIAL**

- 1-3**      **Guest Editorial: The Regenerative Dentistry: Current Approaches and Future Insights**  
Marco Tatullo
- 4**        **The Editor-in-Chief's Recommendation of this Issue's Article to Readers;**  
Burak Buldur

### **ORIGINAL RESEARCH**

- 5-12**      **Evaluation of Penetration Depth of Sodium Hypochlorite Into Dentinal Tubules After Passive Ultrasonic Irrigation Compared to Er;Yag Laser Activation. An In-Vitro Study**  
Abdullah R. Raies, Khetam Almarrawi, Salma F. Al Nesser
- 13-21**     **Using a Dental Operating Microscope in the Treatment of Reversible Pulpitis in Primary Teeth**  
Maya Rashkova, Nadezhda Mitova, Zornitsa Lazarova, Natalia Gateva
- 22-31**     **Investigation of the Clinical and Microbiological Effects of Different Toothpastes: In-Vivo Study**  
*Farklı Diş Macunlarının Klinik ve Mikrobiyolojik Etkilerinin İncelenmesi: In Vivo Çalışma*  
Mine Koruyucu, Sinem Birant, Nursen Topcuoglu, Güven Külekci, Figen Seymen
- 32-37**     **Radiographic Features and Treatment Strategies of Impacted Maxillary Canines**  
*Gömülü Maksillar Kanin Dişlerin Radyografik Özellikleri ve Tedavi Stratejileri*  
Ahmet ALTAN, Sefa ÇOLAK, Nihat AKBULUT, Halenur ALTAN
- 38-44**     **Comparison of Oral Health Status and Behaviors Between Children with Autistic Spectrum Disorder and Healthy Children in Rasht City, Iran**  
Seyedeh Hadiyah Daneshvar, Alaleh Kavianfar, Seyed Hossein Masoomi, Mir Mahdi Daneshvar
- 45-51**     **Evaluation of Long-Term Results of Two Different Calcium Silicate Based Materials in Primary Molar Teeth Vital Pulpotomies: An In vivo Study**  
*İki Farklı Kalsiyum Silikat Bazlı Materyalin Süt Dişi Vital Pulpotomilerinde Uzun Dönem Değerlendirilmesi: İn vivo Çalışma*  
Fatih Öznurhan, Mevlut Kayabaşı, Büşra Kesküş

---

**52-59 Comparison of Periodontitis Diagnoses According to 1999 and 2017 Classifications: An Original Article**

*İrrigasyon Solüsyon Sıcaklıklarının Dental İmplantların Osseointegrasyonu Üzerine Olan Etkisi*

Doğukan Yılmaz, Halit Furuncuoğlu, Osman Varol, Hakan Akın

**60-67 The Relationship Between the Mandibular Bone Quality Assessed by Digital Panoramic Radiography and Serum Biological Parameters in Patients Planning Dental Implant Surgery**

*Dental İmplant Cerrahisi Planlanan Hastalarda Dijital Panoramik Radyografi ile Değerlendirilen Mandibular Kemik Kalitesi ile Serum Biyolojik Parametreler Arasındaki İlişki*

Kaan Orhan, Mehmet Özgür Özemre, Mediha Nur Nişancı Yılmaz, Cansu Köseoğlu Seçgin, Şule Bulut

**CASE REPORT**

**68-71 Traumatic Ulcerative Granuloma with Stromal Eosinophilia (TUGSE)-A Precursor of Oral Squamous Cell Carcinoma?**

Mathangi Kumar, Ravindranath Vineetha, Keerthilatha M Pai, Abhay T Kamath, Chetana Chandrashekar

**72-75 Unusual Appearance of Multiple Exostosis: Case Report**

Livia Sonia Zambrano-De La Peña, David Aristizabal, Luis E Arriola-Guillén, Yalil Rodríguez-Cárdenas, Aron Aliaga-Del Castillo, Maria Eugenia Guerrero





## THE REGENERATIVE DENTISTRY: CURRENT APPROACHES AND FUTURE INSIGHTS

 Marco Tatullo<sup>1,2,3,4</sup>

ORCID ID: 0000-0001-7340-0708

- 1 Department of Basic Medical Sciences, Neurosciences and Sense Organs, University of Bari “Aldo Moro”, Italy
- 2 Marrelli Health - Tecnologica Research Institute, Biomedical Section, Street E. Fermi, Crotona, Italy
- 3 Department of Therapeutic Dentistry, Sechenov University Russia, Moscow, Russia
- 4 Honorary Senior Lecturer, Dundee University, Dundee, UK

Regenerative medicine typically aims to promote and improve the healing of tissues and organs of the human body, to restore the physiological architecture and the main functions lost.<sup>1</sup>

The combination of several scientific fields, including tissue engineering and cell biology, has led to the development of novel regenerative therapies that claim to obtain a better repairing, regenerating and replacing of tissues and organs damaged by chronic and acute diseases, or by severe traumatic injuries. In this landscape, the mesenchymal stem cells (MSCs) have been widely reported to self-regenerate and differentiate towards different tissues, under specific conditions and stimuli.<sup>2</sup> Nowadays, MSCs are routinely used in autologous transplantation: the use of specific molecular effectors and biomimetic scaffolds populated with such MSCs has shown promising results both *in vitro* and *in vivo* experiments aimed to achieve a time-effective tissue reconstruction and a functional regeneration of complex organs.

Besides, studies on the extracellular matrix (ECM) and its interaction with cells have improved the knowledge of stem cell behavior and tissue growth and differentiation on different

surfaces. Recent studies on novel 3D-cultured cell models have investigated specific pathways in “living functional conditions”, combining ECM-based scaffolds, growth factors (GFs) and stem cells (SCs). Nevertheless, the last debates in the scientific community are discussing the usefulness of the traditional concept of scaffolds in modern regenerative procedures.<sup>3</sup>

This critical review aims to discuss the more inspiring and promising approaches with the novel biomimetic scaffolds, and about the last techniques used to regenerate tissues without the need to use the scaffolds.

The current regenerative procedures can recognize two main approaches: scaffold-based and scaffold-free.

The promising results achieved by regenerative procedures have significantly influenced various medical fields, including dentistry, and specifically the endodontics.

Regenerative dentistry aims to translate the latest discoveries in stem cell research, to regenerate and repair both soft and hard oral tissues.<sup>3</sup>

In the early ‘90s, the regenerative techniques have started to use autologous matrices, like the

platelet concentrates and growth factors, to improve tissue regeneration and to speed the healing process. In the last decades, the development of new biomaterials has allowed scientists to combine the oral-derived mesenchymal stem cells (MSCs) and novel biomimetic scaffolds in dental repairing, so to induce not only a reparative process but also an immunomodulatory activity, improving the reparative process and the support of scaffolds to the dental implants.<sup>4</sup>

The regenerative procedures have been simplified thanks to the discovery of several MSC sources easily obtainable from the oral tissues; more in detail, the human teeth seem to have several structures rich in stem cells, characterized by easy harvesting and high efficiency during the isolation and culture stages, compared to other MSCs found in other tissues of human body.<sup>5</sup>

Undoubtedly, the most investigated oral-derived MSCs are the dental pulp stem cells (DPSCs).<sup>6</sup>

Several studies have well demonstrated the important contribution of such stem cells towards the regenerative procedures and immunomodulation in dentistry.<sup>7-10</sup>

In 2003, MSCs from human exfoliated deciduous teeth (SHED) were suggested as a regenerative tool able to treat different gingival damages and to regenerate both dental and bone tissues.<sup>11</sup> Furthermore, the human periodontal ligament stem cells (PDLSC) have been shown to have the ability to differentiate into cells similar to cementoblasts, to regenerate structures similar to dental cement that bind the periodontal ligament, thus contributing to the repairing of the whole periodontal organ.<sup>12</sup>

The discovery of MSCs in dental structures has created also interest in the anatomical tissues surrounding teeth: the fibrous/connective envelope around the developing tooth, the dental follicle, hosts MSCs named progenitor cells of the dental follicle (DFPC).<sup>13</sup> Similarly, the apical gingival papilla surrounding the human teeth has a rich population of stem cells (SCAP).<sup>14</sup> DFPC and SCAP can both differentiate towards odontogenic

and osteogenic lineages, as well as adipose and neuron-like cells.<sup>15</sup>

In this landscape, Marrelli, Tatullo, and Paduano worked on a new concept of oral-derived stem cells, by investigating the biological properties of the discarded tissues harvested during the surgical removal of decayed and inflamed teeth. This novel approach was based on the reusing of biological wastes in regenerative medicine. In fact, the authors found that the inner layer of human periapical cysts (hPCy-MSC) were rich of MSCs, able to differentiate towards the classic osteo-/adipo-/condro-genic lineages; such hPCy-MSCs were also compared with DPSCs, showing a stronger commitment towards the bone reconstruction, similarly to the bone marrow stem cells BMSCs.<sup>16-18</sup>

Stem cells have shown significant potential in regenerative dentistry, not only for their proliferative and differentiating ability but also for the powerful events induced by specific factors secreted during their lifetime. Stem cells are, moreover, strategic players able to modulate the inflammatory response when they are engrafted in tissues, in combination with scaffolds or not. In the last few years, scientists are focusing their attention on the interaction between stem cells and the biological site of implantation: this interaction is mediated by several co-factors that work to reproduce a more “friendly” microenvironment, also called “stem cell niche”. The establishment of these conditions is now considered fundamental to ensure successful engraftment of the newly implanted tissue/organ. The improvement of such conditions has developed a new concept of scaffold-free approach, which is different compared with the scaffold-based procedures. The use of human periapical cysts (hPCy-MSC) has been largely described: the impact of such novel and easy-to-obtain oral-/dental-derived MSCs has triggered the research on novel biomaterials and on innovative strategies for optimizing and translate in vivo the researches related to tissue engineering in dental applications.

## REFERENCES

1. Mao AS, Mooney DJ. Regenerative medicine: Current therapies and future directions. *Proc Natl Acad Sci USA* 2015;112:14452–14459.
2. Tatullo M, Codispoti B, Pacifici A, Palmieri F, Marrelli M, Pacifici L, Paduano F. Potential use of human periapical cyst-mesenchymal stem cells (hpcy-mscs) as a novel stem cell source for regenerative medicine applications. *Front Cell Dev Biol* 2017;5:103.
3. Amrollahi P, Shah B, Seifi A, Tayebi L. Recent advancements in regenerative dentistry: A review. *Mater. Sci Eng C Mater Biol Appl* 2016;69:1383–1390.
4. Tatullo M, Marrelli M, Scacco S, Lorusso M, Doria S, Sabatini R, Auteri P, Cagiano R, Inchingolo F. Relationship between oxidative stress and "burning mouth syndrome" in female patients: a scientific hypothesis. *Eur Rev Med Pharmacol Sci* 2012;16:1218-1221.
5. Tatullo M, Codispoti B, Pacifici A, Palmieri F, Marrelli M, Pacifici L, Paduano F. Potential use of human periapical cyst-mesenchymal stem cells (hpcy-mscs) as a novel stem cell source for regenerative medicine applications. *Front Cell Dev Biol* 2017;5:103.
6. Gronthos S, Mankani M, Brahim J, Robey PG, Shi S. Postnatal human dental pulp stem cells (DPSCs) in vitro and in vivo. *Proc Natl Acad Sci USA* 2000;95:13625-13630.
7. Reynolds AJ, Jahoda CA. Cultured human and rat tooth papilla cells induce hair follicle regeneration and fiber growth. *Differentiation* 2004;2:566-575.
8. Barry M, Pearce H, Cross L, Tatullo M, Gaharwar AK. Advances in Nanotechnology for the Treatment of Osteoporosis. *Curr Osteoporos Rep* 2016;14:87-94.
9. Tatullo M. About stem cell research in dentistry: many doubts and too many pitfalls still affect the regenerative dentistry. *Int J Med Sci* 2018;15:1616-1618.
10. Kerativitayanan P, Tatullo M, Khariton M, Joshi P, Perniconi B, Gaharwar AK. Nanoengineered Osteoinductive and Elastomeric Scaffolds for Bone Tissue Engineering. *ACS Biomaterials Science & Engineering* 2017;27:95–104.
11. Miura M, Gronthos S, Zhao M, Lu B, Fisher LW, Robey PG, Shi S. SHED: stem cells from human exfoliated deciduous teeth. *Proc Natl Acad Sci USA* 2003;100:5807-5812.
12. Seo BM, Miura M, Gronthos S, Bartold PM, Batouli S, Brahim J, Young M, Robey PG, Wang CY, Shi S. Investigation of multipotent postnatal stem cells from human periodontal ligament. *Lancet* 2004;364:149-155.
13. Morsczeck C, Götz W, Schierholz J, Zeilhofer F, Kühn U, Möhl C, Sippel C, Hoffmann KH. Isolation of precursor cells (PCs) from human dental follicle of wisdom teeth. *Matrix Biol* 2005;24:155-165.
14. Sonoyama W, Liu Y, Fang D, Yamaza T, Seo BM, Zhang C, Liu H, Gronthos S, Wang CY, Wang S, Shi S. Mesenchymal stem cell-mediated functional tooth regeneration in swine. *PloS One* 2006;1:e79.
15. Yang B, Qiu Y, Zhou N, Ouyang H, Ding J, Cheng B, Sun J. Application of Stem Cells in Oral Disease Therapy: Progresses and Perspectives. *Front Physiol* 2017;8:197.
16. Marrelli M, Paduano F, Tatullo M. Cells isolated from human periapical cysts express mesenchymal stem cell-like properties. *Int J Biol Sci* 2013;9:1070-1078.
17. Tatullo M, Falisi G, Amantea M, Rastelli C, Paduano F, Marrelli M. Dental Pulp Stem Cells and Human Periapical Cyst Mesenchymal Stem Cells in Bone Tissue Regeneration: Comparison of Basal and Osteogenic Differentiated Gene Expression of a Newly Discovered Mesenchymal Stem Cell Lineage. *J Biol Regul Homeost Agents* 2015;29:713-718.
18. Ballini A, Cantore S, Scacco S, Coletti D, Tatullo M. Mesenchymal Stem Cells as Promoters, Enhancers, and Playmakers of the Translational Regenerative Medicine 2018. *Stem Cells Int* 2018;2018:6927401.

**The Editor's recommendation of this issue's article to readers**

**INVESTIGATION OF THE CLINICAL AND MICROBIOLOGICAL EFFECTS OF  
DIFFERENT TOOTHPASTES: *IN-VIVO* STUDY**

I am pleased to inform you that I have chosen this article by Koruyucu *et al.*<sup>1</sup> as Editor's Choice for first issue of 2020.

Biofilm control is an important procedure for the removal of microbial dental biofilm to prevent tooth decay and periodontal disease and to prevent the accumulation of teeth and adjacent gingival surfaces. Toothpastes with antimicrobial effects have an important effect on the removal of both dental biofilm and gingivitis.

This article shows that all tested toothpastes including fluoride-free, chlorite-containing and fluoride-containing, proved to be safe and significantly effective clinical and microbiological features

Happy readings and have a great year with increasing academic interest in 2020!

Assoc. Prof. Burak Buldur  
Co-Editor-in-Chief

**REFERENCE:**

1. Koruyucu M, Birant S, Topcuoglu S, K ulekci G, Seymen F. Investigation of The Clinical and Microbiological Effects of Different Toothpastes: In-Vivo Study. Cumhuriyet Dent J 2020;23:1;22-31.



## EVALUATION OF PENETRATION DEPTH OF SODIUM HYPOCHLORITE INTO DENTINAL TUBULES AFTER PASSIVE ULTRASONIC IRRIGATION COMPARED TO ER;YAG LASER ACTIVATION. AN IN-VITRO STUDY

### ABSTRACT




**Objectives:** The aim of this study was to compare penetration depth of sodium hypochlorite into dentinal tubules after passive ultrasonic agitation and ER; YAG activation.

**Materials and methods:** Twenty-four single rooted human mature mandibular premolars were decoronated and accessed. After locating the apex and determining the working length, preparation of root canal was done up to #35 file using Mtwo system and with 5.25%NaOCl irrigation. Teeth were then sealed apically with wax and submerged in a crystal violet dye for 48 hours to stain dentin. NaOCl Irrigation was activated with either Ultrasonic or ER;YAG laser. Specimens were sectioned longitudinally and depth of bleached zone was evaluated under a stereomicroscope 40X.

**Results:** Penetration depth was significantly higher in overall root canal in ultrasonic group than ER;YAG laser group ( $P=.000$ ). In ER;YAG Laser group, the highest penetration depth was in the coronal third followed by middle and apical, with significant difference between apical third and both middle and coronal thirds ( $P=.009$ ,  $.003$  respectively), and no significant difference between middle and coronal thirds ( $P=.083$ ). Highest penetration depth was seen in the middle third, followed by coronal and apical, with no significant difference in penetration depth between the three sections of the root canal activated with Ultrasonic ( $P=.664$ ).

**Conclusion:** ultrasonic activation can lead to more NaOCl penetration into dentinal tubules than activation with ER;YAG.

**Key words:** Sodium Hypochlorite, Ultrasonics, ER;YAG Laser

 Abdullah R. RAIES<sup>1</sup>  
 Khetam ALMARRAWI<sup>1</sup>  
 Salma F. AL NESSER<sup>2</sup>

ORCID IDs of the authors:

A.R.R. 0000-0002-3693-2438

K.A. 0000-0003-4041-1923

S.F.A.N.0000-0002-9492-3599

<sup>1</sup> Department of Endodontics, Faculty of Dentistry, Hama University, Hama, Syria.

<sup>2</sup> Department of Pediatric Dentistry, Faculty of Dentistry, Damascus University, Damascus, Syria

**Received** : 25.11.2019

**Accepted** : 06.02.2020

## **INTRODUCTION**

Successful endodontic treatment is dependent on the proper cleaning and shaping of canals to eliminate the remnants of vital and necrotic tissues, microorganisms and their toxins, and accumulated dentinal debris resulting from instrumentation. Mechanical instrumentation alone is insufficient to disinfect the whole root canal system.<sup>1</sup> A study conducted by Peters *et al.*<sup>2</sup> showed that 35% of the root canal remained untouched after instrumentation. Thus, chemical irrigation has an important complementary role in disinfecting root canals, which allows the penetration to dentinal tubules, isthmus, lateral canals, and apical ramifications.<sup>3,4</sup>

Sodium hypochlorite has been introduced to endodontics as the main and most common irrigant due to its antibacterial effect, the ability to dissolve organic tissues and pulpal residuals, and the penetration of lateral canals, which is attributed to its low viscosity.<sup>5-7</sup>

Traditional irrigation with a syringe and needle has limited penetration into lateral canals.<sup>8</sup> Activating endodontic irrigants has been deemed to increase the disinfecting properties of irrigants through the enhancement of its chemical and physical actions.<sup>9</sup>

Ultrasound was first introduced to Endodontics in 1957.<sup>10</sup> Passive Ultrasonic Irrigation (PUI) can disinfect root canal through the improvement of irrigant contact to the root canal walls, and its cavitation and acoustic streaming effects.<sup>11</sup> A review of the literature described the antibacterial effect of the PUI system, and its efficacy in better removal of the smear layer, facilitating cleaning the isthmus from curved root canals.<sup>12</sup> The rapid movement of this device enhances the shear stress of tissue remnants and biofilm.<sup>13</sup>

More Recently, Laser activated irrigant (LAI) has gained attention in root canal irrigation.<sup>14</sup> LAI has the ability to enhance root canal debridement by its photoacoustic wave shocks in the irrigating which results in vaporization of the irrigant, creating vapor bubbles that can expand and explode with cavitation effect. Expansions cause

high pressures which leads to the rupture of bubbles.<sup>15</sup>

The literature yielded conflicting results regarding the most effective way in enhancing the penetration of NaOCl into dentinal tubules. While some studies reported that laser activation is better than ultrasonic devices<sup>14,16</sup>, others stated opposite results<sup>17,18</sup>. Thus, the aim of this study was to compare PUI and ER:YAG (LAI) in penetration depth of NaOCl into dentinal tubules.

## **MATERIALS AND METHODS**

This study was carried out at the department of Operative Dentistry, Faculty of Dentistry, Hama University, and an approval of the Scientific Research Committee of Hama University with the ID: 307 has been obtained on 14/2/2018 before the initiation of the study.

Sample size calculation was done using G\*power program v.3.1 (Heinrich-Hein-Universität Düsseldorf, Germany; <http://www.gpower.hhu.de/>), and 24 freshly extracted human mature single-rooted mandibular premolars were determined as the total specimens. Teeth were extracted due to orthodontic reasons.

Tooth selection criteria were as follows: single canal, no external or root internal resorption, lack of tooth caries, cracks or developmental anomalies under 20X magnification, and no previously endodontically treated canals, with canal curvature of no more than 5° according to Schneider.<sup>19</sup>

Teeth were debrided using CK6 hand instrument (Zeffiro-Lascod, Florence, Italy) to remove all tissue debris attached to the root surface after extraction. Then, teeth were stored in a plastic container with 0.5% chloramine T for 1 week to sterilize the specimens, before they were moved to another plastic container with 0.9% saline and kept in a refrigerator at 4°C until used.

### ***Sample preparation***

The crown of teeth were shortened using a diamond disk (Edenta, Switzerland) to standardize the length at 19 mm using a digital caliper.

Conventional access cavity was done using a 2mm round bur, and the roof of the pulp chamber

was removed with Endo-Z bur (Dentsply, Switzerland). The pulp of each tooth was extirpated with barbed broaches (VDW, Germany). The working length was measured after locating the apex with a 15# K-file until the tip of the file was observed from the apical foramen, then subtracting 1mm from the canal length.

### ***Root canal preparation***

Canals were prepared with Mtwo system (VDW; Germany) following the basic instrument sequence until #35 along the entire working length using a gentle in and out motions. Preparation was done according to manufacturer's instruction regarding the speed and torque. 2 ml of 5.25% NaOCl was irrigated after each instrument and a final rinse with 5ml NaCl was done before drying specimens with paper points.

The root surface of each tooth was covered with two layers of nail varnish, and the apical foramen was sealed in order to prevent the dye from leakage outside the canals.

A preliminary study was conducted in order to determine the most appropriate period for the type of sectioning (cross sectional vs. longitudinal), and the pigmentation process in which teeth were submerged in the crystal violet dye for 12 or 24 or 48 hours, and the final period was found to be the appropriate one to stain the hole root canal.

Specimens were submerged in a plastic container with crystal violet dye for 48 hours in 37°C temperature. Teeth were then washed with running water to flush away the dye.

### ***Study groups and irrigation protocols***

Specimens were randomly distributed into two groups based on the activation method as follows:

Group A (n=12): activation using ultrasonic device (Varios 350, NSK, Japan).

Group B (n=12): activated using ER:YAG laser (Kavo Key Laser III 1243, Germany).

In each group, 2 ml of 5.25% NaOCl was introduced for 60 seconds using a 30-Gauge open ended needle 1 mm shorter of the apical foramen.

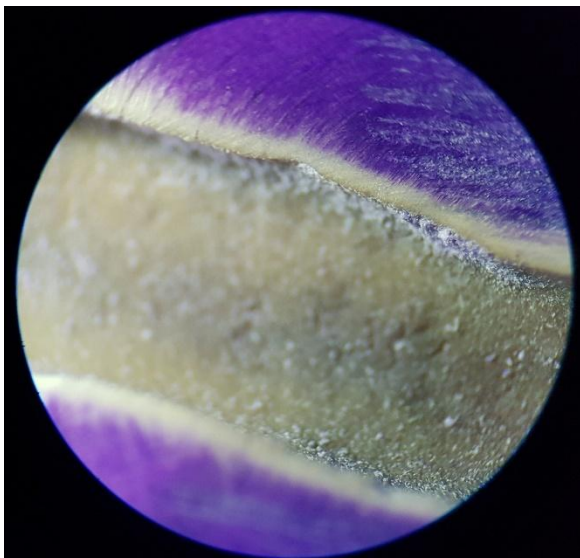
In group A: 2 ml of 5.25% NaOCl was introduced for 60 seconds using a 30-Gauge open ended needle 1 mm shorter of the apical foramen. Ultrasonic activation was performed by inserting a stainless steel #22 U file into E11 Ultrasonic tip (Varios, NSK, Japan) at E4 power to agitate irrigant for 60s and 1 mm above the apical foramen. Root canal was irrigated then with 2 ml of 5.25% NaOCl for another 60s and a final rinse was accomplished with saline for 60s. A final rinse with saline solution was applied for 60 seconds.

In group B: 2 ml of 5.25% NaOCl was introduced for 60 seconds using a 30-Gauge open ended needle 1 mm shorter of the apical foramen. ER:YAG laser was used for activation with a special fiber head designed for endodontic usage (100 mill joules, 2 watts, frequency: 20 Hz) for 60s. Root canal was irrigated then with 2 ml of 5.25% NaOCl for another 60s and a final rinse was accomplished with saline for 60s. A final rinse with saline solution was applied for 60 second.

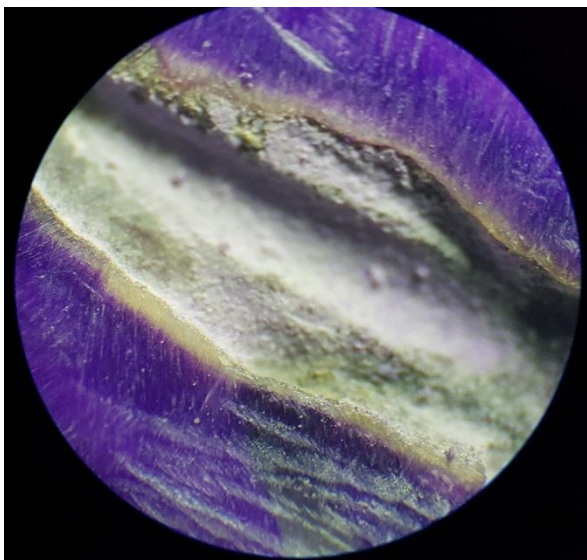
### ***Teeth sectioning and measuring the depth of NaOCl penetration***

Teeth were sectioned longitudinally after creating a groove of 1 mm depth on the mesial and distal surface of the root under an endodontic microscope with 30x magnification. Then, each tooth was put on a polyvinyl siloxane model in order to separate the two sections with a chisel and a mallet.<sup>20</sup>

Two parallel lines, 3 mm apart, were drawn on the surface of each section to calibrate the image. Each section was captured with a digital camera (Samsung NX500, Samsung; USA) under a stereomicroscope (Meiji; Japan) at 40X. The depth of sodium hypochlorite penetration was measured using Microdicom Program by evaluating the whitened areas inside the dentinal tubules in each third (coronal, middle, apical) of the tooth, where the dye was removed due to the oxidization effect of sodium hypochlorite. (Fig1 and 2).



**Figure 1** Shows the whiten bleached area that indicates penetration depth of NaOCl in PUI



**Figure 2** Shows the whiten bleached area that indicates penetration depth of NaOCl in LAI

### Statistical Analysis

Normality of distribution was checked with Kolmogorov-Smirnov test. Data showed normal distribution. Thus, independent T test was used to determine if there was a statistically significant difference in NaOCl penetration depth between group A and group B in each third (coronal, middle, third), and ANOVA test to determine if there was a statistically significant difference in the depth of penetration between the three sections of the root surface within each group

Data were analyzed using SPSS V.23 (IBM; CORP., ARMONK, USA). The level of the P value was set 5%, and the level of confidence was set at 95%.

### RESULTS

Descriptive results including minimum, maximum, mean, and standard deviation of NaOCl penetration depth in each third of the root surface and overall root canal surface are shown in (Table 1). Group A activated with ultrasonic showed more penetration depth in the three thirds of the root canal compared to group B activated with ER:YAG laser.

**Table 1.** Shows descriptive results of the Independent T test regarding the penetration depth of NaOCl between PUI and LAI within each level of the root canal (coronal, middle, and apical third) in (mm)

Levels	Activation type	min	max	mean±SD	P Value
Apical third	PUI	0.17	0.62	0.45±0.13	.002*
	LAI	0.1	0.62	0.25±0.14	
Middle third	PUI	0.25	0.86	0.62±0.18	.003*
	LAI	0.26	0.65	0.41±0.12	
Coronal third	PUI	0.32	1.03	0.59±0.24	.076
	LAI	0.28	0.8	0.44±0.16	
Overall	PUI	0.17	1.03	0.55±0.20	.000*
	LAI	0.1	0.8	0.37±0.16	

\*significant difference  
SD- Standard Deviation

Independent T test showed significantly higher penetration depth in the apical, middle third, and overall root canal length in Ultrasonic group compared to ER:YAG laser group (P=

0.002, 0.003, 0.000 respectively). No significant difference in penetration depth in the coronal third between the two groups (P=0.076) (Table 1).



Descriptive results showed higher penetration depth in the middle third, followed by coronal, and apical third in group A. However, in group B,

highest penetration depth was seen in coronal third followed by middle and apical thirds. (Table 2)

**Table 2.** Shows descriptive results of the ANOVA test regarding the penetration depth of NaOCl between each level of the root canal (coronal, middle, and apical third) in PUI and LAI groups (mm)

groups	Levels	min	max	mean±SD	P Value
PUI	Apical third	0.17	0.62	0.45±0.13	.0006*
	Middle third	0.25	0.86	0.62±0.18	
	Coronal third	0.32	1.03	0.59±0.24	
LAI	Apical third	0.1	0.62	0.25±0.14	.083
	Middle third	0.26	0.65	0.41±0.12	
	Coronal third	0.28	0.8	0.44 ±0.16	

\*significant difference  
SD- Standard Deviation

ANOVA test showed no significant difference in penetration depth of NaOCl between the three thirds of the root canal within group A (activation with Ultrasonic) (P=0.083). However, significant difference in penetration depth between the three thirds of the root canal within group B (activation with ER:YAG Laser) (P=0.006) (Table 2).

LSD Post hoc test for pairwise comparison in group B (activation with ER:YAG Laser) showed significant difference between apical third and both middle and coronal thirds (P= 0.009, 0.003 respectively). No significant difference was observed between middle and coronal thirds (P=0.0664) (Table 3).

**Table 3.** LSD pairwise comparison between the three Levels of root canal in LAI group in (mm)

group	Levels	Difference in means	SE	P Value	
LAI	Apical third	Coronal third	-0.18	0.06	.003*
		Middle third	-0.16	0.06	.009*
	Middle third	Coronal third	-0.02	0.06	.664

\*significant difference  
SE -Standard Error

## DISCUSSION

Bacteria of severely infected root canal can invade smear layer along the root canal into dentinal tubules in lateral canals and as a result be responsible of treatment failure.<sup>21</sup> Smear layer can interfere with the penetration of irrigants and antimicrobial agents into dentinal tubules.<sup>22</sup> Nair *et al.*<sup>23</sup> showed residual infection in mesial root canals of mandibular molars after instrumentation, irrigation with NaOCl alone, and obturation. Therefore, enhancement of irrigation by devices is important to allow irrigants to disinfect these inaccessible areas.<sup>22</sup>

It has been declared that the presence of smear layer can impede the penetration of NaOCl into dentinal tubules.<sup>24</sup>

Olivi.<sup>25</sup> explained the effect of Er:YAG laser on dentinal debris and smear layer removal,

besides its ability to enhance the action of NaOCl. This enhancement has been related to the shockwaves of lasers that can be absorbed through NaOCl creating vapor bubbles that can expand and implode reducing smear layer.<sup>26</sup>

On the other hand, Hazar *et al.*<sup>27</sup> showed high efficacy of ultrasonic agitation in triple antibiotic paste removal from the apical portion of the root canal, which was related to the high velocity of irrigant flow, while Uzunoglu *et al.*<sup>28</sup> showed that some ultrasonic dependent devices can have good effect in removing CaOH from root canal. In addition, ultrasonic can enhance irrigation through disinfection and smear layer removal through bubbles generated by cavitation and acoustic streaming effects.<sup>22</sup> Therefore, this study aimed to compare activation of Er:YAG laser, and Ultrasonic in penetration depth of NaOCl.

Crystal violet dye was chosen in this study due to its high ability in pigment dentine so it can be easily seen under a stereomicroscope, and since NaOCl is an antioxidant it can whiten the purple color of the dye revealing the normal color of dentine.

This study assessed the penetration depth after sectioning teeth longitudinally with a chisel and a mallet, in order to maintain the inside portion of the root canal intact and preserve it from damage that could be attributed due to diamond disc sectioning.

Studies showed that bacteria can penetrate dentinal walls and lateral canals into different depths.<sup>29,30</sup> In 62% of cases, bacteria can invade dentinal tubules and reach the surface of cementum.<sup>31</sup> This bacteria can be responsible of endodontic treatment failure.<sup>32</sup>

With regards to activation with Er;YAG laser, this study showed highest penetration depth in the coronal third, followed by middle and apical third. Significant difference was seen between apical third and both middle and coronal thirds. This was consistent with Rajakumaran *et al.*<sup>33</sup> and Ghorbanzadeh *et al.*<sup>16</sup> study that showed highest penetration depth with laser activated irrigant in coronal third followed by middle and apical thirds. Highest penetration depth in coronal third could be attributed to the large and densely packed dentinal tubules seen in the coronal third of the root canal followed by middle third, while narrower tubules are located more in the apical thirds, and as a result can limit the ability of irrigant penetration.<sup>34</sup> Both groups demonstrated minimum penetration depth in the apical third of the root canal, this was in agreement with Ghorbanzade *et al.*<sup>16</sup>, Macias *et al.*<sup>35</sup>, and Vandrangi.<sup>36</sup>

However, interesting findings were observed in Ultrasonic activation, where the highest penetration depth was in middle third, followed by coronal and apical with no significant differences between the three thirds. This finding was in agreement with Vandrangi.<sup>36</sup> Macias *et al.*<sup>35</sup> also showed highest penetration of Chinese ink in the middle third of the root canal when ultrasonic was

used. In contrast, Baz *et al.*<sup>37</sup> showed lower penetration depth in middle third than coronal. However, different irrigation protocols were used with up and down motions in activation, while in this study the PUI was set at one position.

This study showed that penetration depth of ultrasonic was significantly higher compared to Er;YAG laser in overall root canal length. Therefore, within the confines of this study, the use of expensive laser devices is not necessary. Moor *et al.*<sup>17</sup> revealed that laser devices could be replaced with ultrasonic devices in order to remove smear layer, on condition that activation of ultrasonic should be for 60 seconds in total, which was similar time in the present study. Although Deleu and Meire<sup>18</sup> revealed better smear layer removal in LAI than PUI, no significant difference was observed between the two groups.

This study was not consistent with Ghorbanzade *et al.*<sup>16</sup> study which revealed that laser activation is better than ultrasonic with regards to penetration depth. However, this could be attributed to the different type of laser activation (Nd; YAG) used in their studies, and less activation times. Schlichting and Widbiller.<sup>14</sup> showed better penetration when PIPS was used compared to ultrasonic, but this difference could be related to the irrigation regimen used in their study, where NaOCl was preheated in conjunction to the use of EDTA as a final irrigation protocol.

## **CONCLUSIONS**

Passive ultrasonic agitation can be an effective irrigant activation method through enhancing the penetration depth of NaOCl into dentinal tubules more than ER;YAG laser.

## **ACKNOWLEDGMENT**

This study has been carried out at the department of Operative Dentistry, Faculty of Dentistry, Hama University, Syria, which deserves a great appreciation for all academic and financial support.

## **CONFLICTS OF INTEREST**

The authors declare no conflicts of interest.

## REFERENCES

1. Maciel Filho M, Zotarelli-Filho I, Linhares de Castro F. Main Predictors of Root Canal Endodontical Treatment: Systematic Review. *Int J Dent Oral Sci* 2018;5:595-600.
2. Peters OA, Schonenberger K, Laib A. effects of Ni-Ti preparation technique on root canal geometry assessed by micro computed tomography. *Int Endod J* 2001;34:221-230.
3. Jena A, Sahoo SK, Govind S. Root canal irrigants: a review of their interactions, benefits, and limitations. *Compend Contin Educ Dent* 2015;36:256-261.
4. Ramachandra JA, Nihal NK, Nagarathna C, Vora MS. Root canal Irrigants in Primary Teeth. *World J Dent* 2015;6:229-234.
5. Ismail S, Adyanthaya A, Sreelakshmi N. Intracanal irrigants in pediatric endodontics : A review. *Int J Appl Dent Sci* 2017;3:246-251.
6. He L, Zhong J, Gong Q, Kim SG, Zeichner SJ, Xiang L, Ye L, Zhou X, Zheng J, Liu Y, Guan C, Cheng B, Ling J, Mao JJ. Treatment of Necrotic Teeth by Apical Revascularization: Meta-analysis. *Sci Rep* 2017;7:1-11.
7. Kuştarıcı A, Oktay EA, Kılıç A, Özcan Ü, Altunbaş D. Evaluation of antimicrobial efficacy of sodium hypochlorite, propolis, octenidinedihydrochloride and chlorhexidine on microorganisms. *Cumhur Dent J* 2011;14:183-190.
8. Buldur B, Kapdan A. Comparison of the EndoVac System and Conventional Needle Irrigation on Removal of the Smear Layer in Primary Molar Root Canals. *Niger J Clin Pract* 2017;20:1168-1174.
9. Walsh LJ. Activation of Alkaline Irrigation Fluids in Endodontics. *Materials (Basel)* 2017;10:1-10.
10. Plotino G, Pameijer CH, Grande NM. Ultrasonics in Endodontics : A Review of the Literature. *J Endod* 2007;33:81-95.
11. Wright PP, Walsh LJ. Optimizing Antimicrobial Agents in Endodontics. In: Kumavath RN, (eds). *Antimicrobial Agents. Croatia: InTech; 2017:87-107.*
12. van der Sluis L, Versluis M, Wu M, Wesselink P. Passive ultrasonic irrigation of the root canal: a review of the literature. *Int Endod J* 2007;40:415-426.
13. Bryce G, MacBeth N, Gulabivala K. The efficacy of supplementary sonic irrigation using the EndoActiva- torâ system determined by removal of a collagen film from an ex vivo model. *Int Endod J* 2018;51:489-497.
14. Schlichting R, Widbiller M. Penetration depth of irrigants into root dentine after sonic , ultrasonic and photoacoustic activation. *Int Endod J* 2019;52:1210-1217.
15. Plotino G, Cortese T, Grande NM, Leonardi DP, Di Giorgio G, Testarelli L, Gambarini G. New technologies to improve root canal disinfection. *Braz Dent J* 2016;27:3-8.
16. Ghorbanzadeh A, Aminsobhani M, Chiniforush N, Shamshiri AR. Penetration Depth of Sodium Hypochlorite in Dentinal Tubules after Conventional Irrigation, Passive Ultrasonic Agitation and Nd:YAG Laser Activated Irrigation. *Laser Appl Med Sci Res Cent* 2016;7:105-111.
17. Moor RJG De, Meire M, Goharkhay K. Efficacy of Ultrasonic versus Laser-activated Irrigation to. *J Endod* 2010;36:1580-1583.
18. Deleu E, Meire MA. Efficacy of laser-based irrigant activation methods in removing debris from simulated root canal irregularities. *Laser Med Sci* 2013;30:831-835.
19. Schneider SW. A comparison of canal preparations in straight and curved root canals. *Oral Surg Oral Med Oral Pathol* 1971;32:271-275.
20. Sabins RA, Johnson JD, Hellestein JW. A comparison of the cleaning efficacy of short- term sonic and ultrasonic passive irrigation after hand instrumentation in molar root canals. *J Endod* 2003;29:647-648.
21. William S, Goldman M. penetrabilty of the smeared layerby a strain of *Proteus vulgaris*. *J Endod* 1985;11:385-388.
22. Zehnder M. Root Canal Irrigants. *J Endod* 2006;32:389-398.
23. Nair B, Reddy K. Advances in root canal disinfection. *J Pharm Biomed Sci* 2011;5:1-3.
24. Fogel H, Pashley D. Dentine pwemeability: effects of endodontic procedures on root slabs. *J Endod* 1990;16:442-445.
25. Olivi G. Laser Use in Endodontics : Evolution from Direct Laser Irradiation to Laser-Activated Irrigation. *J Laser dent* 2013;21:58-71.
26. George R, Walsh LJ. Apical Extrusion of Root Canal Irrigants When Using Er : YAG and Er , Cr : YSGG Lasers with Optical Fibers : An In Vitro Dye Study. *J Endod* 2008;34:706-708.

- 27.** Hazar E, Sağlam BC, Koçak S, Koçak MM. Efficacy of XP-Endo Finisher and Passive Ultrasonic iRRIGATION on Modified Triple Antibiotic Paste Removal. *Cumhur Dent J* 2019;22:108-113.
- 28.** Uzunoglu E, Gorduysus M, Nagas E. Efficacy of different devices in removing calcium hydroxide from the root canal. *Cumhur Dent J* 2015;18:318-326.
- 29.** Schafer E, Bossmann K. antimicrobial efficacy of chlorohexidine and two calcium hydroxide formulations against *Enterococcus fecalis*. *J Endod* 2005;31:53-56.
- 30.** Siqueira JF, Rocas I, Lopez H. patterns of microbial colonization in primary root canal infections. *Oral Surgery, Oral Med Oral Pathol Oral Radiol Endodontology* 2002;93:174-178.
- 31.** Peters L, Wesselink P, Buijs J, Winkelhof A. viable bacteria in root dentinal tubules of teeth with apical periodontitis. *Int Endod J* 2001;27:76-81.
- 32.** Haapasalo M, Qrastavik D. in vitro infection and disinfection of dentinal tubules. *J Dent Res* 1987;66:1375-1379.
- 33.** Rajakumaran A, Ganesh A. Comparative Evaluation of Depth of Penetration of Root Canal Irrigant After Using Manual, Passive Ultrasonic, and Diode Laser-Assisted Irrigant Activation Technique. *J Pharm Bioallied Sci* 2019;11:216-220.
- 34.** Paqué F, Luder HU, Sener B, Zehnder M. Tubular sclerosis rather than the smear layer impedes dye penetration into the dentine of endodontically instrumented root canals. *Int Endod J* 2006;39:18-25.
- 35.** Macías D, Bravo V, Echeverri D. Effect of sonic versus ultrasonic activation on aqueous solution penetration in root canal dentin. *J oral Res* 2018;7:24-29.
- 36.** Vandurangi P. Evaluating Penetration Depth of Treatment Fluids into Dentinal Tubules Using the GentleWave® System. *Dentistry* 2016;6:3-7.
- 37.** Castelo-baz P, Cantatore G, Ru M. In Vitro Comparison of Passive and Continuous Ultrasonic Irrigation in Simulated Lateral Canals of Extracted Teeth. *J Endod* 2012;38:688-691.



## USING A DENTAL OPERATING MICROSCOPE IN THE TREATMENT OF REVERSIBLE PULPITIS IN PRIMARY TEETH

### ABSTRACT





**Objectives:** The author reports on a study of the application of the magnifying method with a digital operating microscope (DOM) in combination with controlled excavation using fluorescent method (Proface) in the treatment of asymptomatic closed pulpitis in primary molars treated with the indirect pulp capping technique.

**Materials and methods:** Subject of the study were 40 primary molars (19 first and 21 second molars) of children (20 girls and 20 boys) 4-7 years old with cavitated carious lesions in the dentin suspected for asymptomatic closed pulpitis. All cases were excavated with an identical clinical protocol (conventional excavation). The excavation was controlled using the *fluorescent method (Proface)*. An assessment of the residual dentin, with and without microscope (DOM), at three levels of magnification, was made at each stage.

**Results:** The use of DOM shows a larger diversity in the colors and nuances of the carious dentin, with lighter shades being predominant. DOM gives an opportunity for a better precision in determining the speed of the carious process, which is in direct relation to the defensive ability of the pulp-dentin complex.

**Conclusions:** In the biological treatment of asymptomatic closed pulpitis in primary teeth, the use of DOM magnifying technology gives the opportunity for a precise and accurate assessment during the course of excavation

**Keywords:** Dental operating microscope, FACE, reversible pulpitis.

 Maya RASHKOVA<sup>1</sup>  
 \*Nadezhda MITOVA<sup>1</sup>  
 Zornitsa LAZAROVA<sup>1</sup>  
 Natalia GATEVA<sup>1</sup>

ORCID IDs of the authors:

M.R. 0000-0001-8236-1085

N.M. 0000-0003-4716-7724

Z.L. 0000-0003-0116-259X

N.G. 0000-0002-2584-7983

<sup>1</sup> Department of Pediatric Dentistry, Faculty of Dental Medicine, Medical University-Sofia.

Received : 07.11.2019

Accepted : 06.02.2020

## **INTRODUCTION**

The microinvasive approach in the treatment of caries and its complications is a new paradigm in dental medicine. If the inflammatory changes to the pulp are still reversible (in asymptomatic pulpitis), this approach gives the opportunity to preserve the integrity of the pulp and beneficially influence the healing process.<sup>1-5</sup> Clinically, an asymptomatic closed pulpitis is accompanied by deep carious lesions in the dentin and its treatment requires a non-invasive controlled excavation. The aim of this is to preserve the reversibly damaged dentin capable of internal remineralization and to also arrest the carious process, to stimulate tertiary dentinogenesis and the healing process in the dental pulp.<sup>2-4</sup> A precise controlled excavation can be achieved through the use of the appropriate magnifying tools, among which is the dental operating microscope (DOM) combined with caries-detector using laser fluorescence for precise assessment of the degree of demineralization and microbial invasion of the dentin.<sup>6-8</sup>

Three strategies can be found in scientific literature in regard to the microinvasive approach in controlled excavation with both deep caries and treatment of reversible pulpitis. The first is non-selective excavation down to hard dentin, i.e. removal of all the soft dentin until healthy, hard, non-carious dentin is reached.<sup>10-12</sup> In primary teeth the non-selective excavation of carious dentin down to hard dentin carries a big risk of exposing the pulp and it stands in contradiction to the microinvasive approach which is applied for the treatment of reversible pulpitis. The second strategy is selective excavation down to affected dentin. This is applied in cases of deep dentin caries when the caries has reached the inner third of the dentin.<sup>3-5,9,13</sup> The third is selective removal of partially infected dentin. This method of excavation is recommended for teeth with asymptomatic closed pulpitis where the inflammation is still reversible. In this case the intention is to avoid unwanted exposure of the pulp and endodontic treatment which is risky for primary teeth with advanced root resorption.<sup>11-16</sup> Comparative studies have been carried out over the last years on the precision, sensitivity and

specificity of various methods for assessing the residual dentin during cavity preparation. Its features play a crucial role in the healing process. The results favor the contemporary fluorescent methods which best objectivize the infected dentin.<sup>17-20</sup> Light-induced fluorescence has gradually turned into a concept for control of the excavation, thus the problem with the subjective assessment of the operator has been overcome. Combining FACE (Fluorescence-Aided Caries Excavation) technology with digital magnifying technology is a new approach which improves precision in selective excavation of reversible pulpitis in children.<sup>19,20</sup>

In this study, the authors reports of the application of the magnifying method by use of a digital operating microscope (DOM) in combination with controlled excavation with fluorescent method (Proface) in the treatment of asymptomatic closed pulpitis in primary molars treated through an indirect pulp capping.

## **MATERIALS AND METHODS**

This study was conducted from February 2019 to August 2019 at the Faculty of Dental Medicine, Medical University of Sofia. The children were included in the study after explaining its purpose to their parents/guardians and obtaining their written consent. An ethical approval from KENIMUS – Ethical commission of Medical University of Sofia – 24/07.12.2018 was obtained. The study protocol and design was approved by the KENIMUS.

Subject of the study were 40 primary molars (19 first and 21 second molars) of children (20 girls and 20 boys) 4-7 years old, with deep cavitated carious lesions in the dentin, diagnosed as asymptomatic closed pulpitis. The primary molars with diagnosis asymptomatic pulpitis (lack of spontaneous and night pain), included in the study, were selected randomly according to CONSORT guideline and according to the following criteria:

- *in approximal lesions* - over 2/3 of the approximal surface is affected, presence of a cusp destroyed by caries.

- *in occlusal lesions* - the lines of the lesion reach the middle of the distance between the deepest point of the fissure and the top of the closest cusp, no reddening or pain during gingival palpation, no pulp communication, no pain during percussion.

For the purposes of this study a comparative diagnostic with and without DOM (8x, 16x, 23x) was carried out. All cases of asymptomatic closed pulpitis were excavated with an identical clinical protocol (conventional excavation). An assessment of the residual dentin, with and without microscope, was made at each stage. Each stage of the excavation was described in a purpose-made medical card.

The excavation was controlled with the *fluorescent method (Proface)*. In this method of control the tooth is illuminated with violet light up to 405 nm. Glasses with a filter with permeability of up to 500 nm of the optical spectrum are used. The infected dentin is seen in red, while healthy structures have a greenish color. We applied criteria for fluorescent control with (*Proface*) for dentin at different stages of destruction: <sup>21</sup>

- *infected dentin*: the fluorescence is with an intensive red or dark red color and completely encompasses the carious dentin;

- *partially infected dentin*: pink fluorescence with the presence of some localized limited red spots in the area of the dentin above the pulp;

- *affected dentin*: pale pink fluorescence localized only in various spots at the bottom of the cavity (the area of the dentin above the pulp), with no fluorescence present in the rest of the cavity;

- *healthy dentin*: no red fluorescence localized in the dentin-enamel junction and 1-2 mm from the walls of the cavity.

At each stage of excavation, after reaching the respective fluorescent criterion, the visual-tactile characteristics of the residual dentin were registered, both the ones visible to the naked eye and those with DOM, at three levels of magnification. The visual-tactile method of Bjørndal *et al.*<sup>22</sup> was used (Table 1).

**Table 1.** Visual-tactile method of Bjørndal *et al.*<sup>22</sup>

Visual criteria – dentin color	Tactile criteria (with probe) -dentin consistency
black	Code 1 (very soft) – the probe penetrates and peels parts of it away easily; Code 2 (soft dentin) – probe can easily penetrate and exit the dentin; Code 3 (moderately hard) – slight resistance during probing; Code 4 (hard dentin) – the probe moves over the dentin with a slight resistance, and leaves a white trail; Code 5 (hard non-carious) – soft squeaking and resistance during probing.
dark brown	
light brown	
yellow	
light yellow	

**Clinical Protocol**

- **Stage 1:** exposing the carious lesion and excavation down to healthy dentin along the dentin-enamel junction (DEJ) and gingival base;

- control with *Proface* down to no presence of red fluorescence;

- description of visual-tactile characteristics of dentin (visible to the naked eye, with DOM with three levels of magnification (8x, 16x, 23.3x); photo documentation;

- **Stage 2:** excavation of carious dentin down to fluorescent criteria for partially infected dentin with *Proface*;

- control with *Proface* – pale pink fluorescence of the dentin above the pulp with limited spots of red fluorescence in the deepest areas;

- description of visual-tactile characteristics of the partially infected dentin (visible to the

naked eye, with DOM with the same three levels of magnification; photo documentation;

- calcium hydroxide cement application (caviLINE – AHL) and temporary filling with glass ionomer cement (GIC) (GC FUJI TRIAGE White) for three months;

- X-ray control (bitewing) allowing reproducibility of the image at the subsequent control radiographic examination in childhood.

**- Stage 3: monitoring**

- *after one month:* clinical monitoring and evaluation of the integrity of the GIC filling and the symptoms present;

- *in the third month:* X-ray control - assigned radiography with the same exposure parameters as the diagnostic one;

- revision of the cavity: if necessary, an excavation is carried out (if there are fluorescent

red areas at the bottom of the cavity), calcium hydroxide liner (caviLINE - AHL) is re-applied, and a definitive filling with a compomer is carried out (Dyract® XP - Dentsplay Siron).

Later results will be subject to a subsequent publication.

For the statistical processing of the results a statistical program SPSS (version 19, SPSS inc. USA) was used. A 95 confidence interval ( $p < 0.05$ ) was chosen for a level of plausibility at which the null hypothesis is to be rejected.

**RESULTS**

**1. Description of the carious dentin after exposing the lesion with and without DOM**

The results from the visual-tactile description of the carious dentin with and without DOM are presented Table 2.

**Table 2.** Consistency of the carious dentin during lesion exposure

Consistency localization	Very soft		soft		total		
	N	% ± sp	N	% ± sp	N	100%	
occlusal	13	81.3 ± 9.76	3	18.7 ± 9.76	16	100%	T=4.53 p<0.05
approximal	19	79.2 ± 8.29	5	20.8 ± 8.29	24	100%	T=4.98 p<0.05
		T=0.16 p>0.05					T=0.16 p>0.05

Pearson Chi Square = 0.417 Sig = 0.519

The consistency of the carious dentin during lesion exposure is predominantly very soft regardless of the localization of the lesions. The differences are supported by statistical plausibility ( $p < 0.5$ ).

Table 3 presents the results of the determination of the color characteristics of the dentin upon exposing of the carious lesion.

**Table 3.** Color of the dentin during carious lesion exposure without and with the use of a DOM<sup>i</sup> with 8x, 16x and 23.3x magnification

Color	Dark brown		Light brown		Dark yellow		total	
	N	% ± sp	N	% ± sp	N	% ± sp	N	100%
No microscope	16	40.0 ± 7.75	24	60.0 ± 7.75	0	0 ± 0	40	100%
With micro. – 8x	14	35.0 ± 7.54	16	40.0 ± 7.75	10	25.0 ± 6.85	40	100%
With micro. – 16x	14	35.0 ± 7.54	16	40.0 ± 7.75	10	25.0 ± 6.85	40	100%
With micro. – 23.3x	14	35.0 ± 7.54	16	40.0 ± 7.75	10	25.0 ± 6.85	40	100%
		T=0.46 p>0.05					T=1.83 p>0.05	

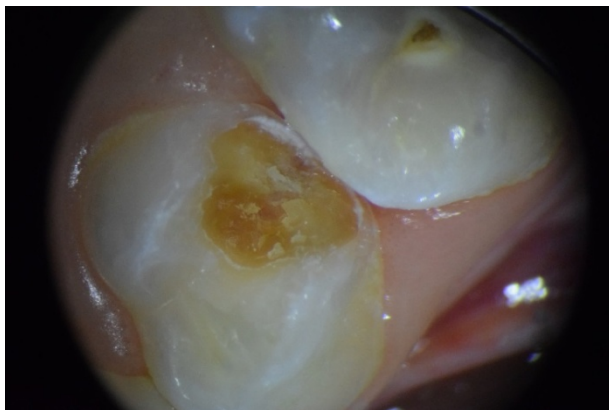
Pearson Chi Square = 12.470 Sig = 0.002

The data shows, that when a DOM with 8x magnification is used, a larger diversity of colors

can be seen, with lighter shades of carious dentin being predominant, compared to the clinical-



visual assessment with no magnification apparatus (fig.1).



**Figure 1.** Photo of the approximal lesion of the left maxillary first primary molar (DOM 8x). Carious dentin with a soft and moist texture is observed during lesion exposure.

No plausible differences in the registered color of the dentin between the various degrees of magnification are observed when using a DOM ( $p>0.05$ ).

## 2. Description of the carious dentin in the DEJ area after excavation with and without DOM

In the DEJ area, after controlled excavation down to non-carious, healthy dentin (lack of

fluorescence with *Proface*), the consistency of the dentin is code 5 by Bjørndal *et al.*<sup>22</sup> – hard dentin, matching the description of non-carious, observed in all clinical cases.

In all clinical cases, when excavating down to healthy dentin and when assessing with and without DOM, a light-yellow dentin is observed matching the characteristics of a healthy structure, with no difference in the assessment being observed with and without DOM.

## 3. Description of the residual carious dentin in the area at the bottom of the cavity observed with and without DOM

After excavation of the DEJ, carious dentin remains at the bottom of the lesion which with *Proface* fluoresces in red.

The consistency of the residual carious dentin is predominantly soft regardless of the localization of the lesion (approximal or occlusal).

The comparative results regarding the color of the infected dentin are presented in Table 4.

**Table 4.** Color of the infected dentin at the bottom of the lesion without and with the use of a microscope with 8x, 16x and 23.3x magnification

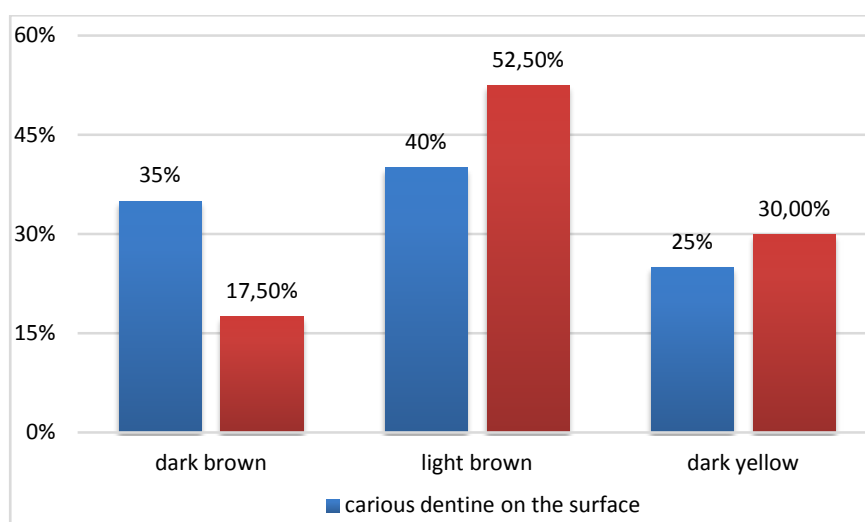
Color \ Magnification	Dark brown		Light brown		Dark yellow		total	
	N	% ± sp	N	% ± sp	N	% ± sp	N	100%
No microscope	16	40.0 ± 7.75	24	60.0 ± 7.75	0	0 ± 0	40	100%
With microscope – 8x magnification	7	17.5 ± 6.01	21	52.5 ± 7.90	12	30.0 ± 7.25	40	100%
With microscope – 16x magnification	7	17.5 ± 6.01	21	52.5 ± 7.90	12	30.0 ± 7.25	40	100%
With microscope – 23x	7	17.5 ± 6.01	21	52.5 ± 7.90	12	30.0 ± 7.25	40	100%
	T=2.30 p<0.05		T=0.68 p>0.05		T= 4.140 p<0.05			

Pearson Chi Square = 13.611 Sig = 0.001

The color of the carious dentin at the bottom of the lesion, observed under a DOM with 8x magnification displays statistical plausibility, greater diversity of colors, and a stronger predominance of the lighter shades in comparison with the color of the same dentin when observed without a microscope ( $p<0.05$ , Table 4). No

difference can be seen in the various levels of magnification.

Here is a comparison of the carious dentin observed with DOM on the surface of the lesion before excavation, and the one at the bottom of the cavity after DEJ excavation. The results are presented in the Figure 1.



**Figure 1.** Comparison of the color of the surface carious dentin (before excavation) with the one at the bottom of the lesion, with DOM<sup>ii</sup> 8x

Predominant on the surface is the dark carious dentin. At the bottom there is a greater diversity, with dark and light brown dentin being evenly distributed in about half of the lesions, while lighter shades are observed in a third to a quarter of the cases.

#### 4. Description of the partially infected circumpulpal dentin, capable of internal remineralization – observed with and without DOM

In clinical cases of asymptomatic closed pulpitis, in the partially infected dentin, which can be preserved, has been shown to be able to stimulate

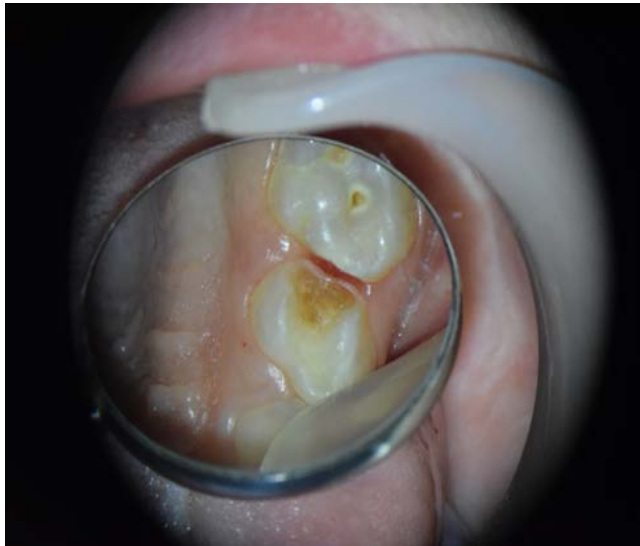tertiary dentinogenesis and a healing process in the area of the underlying pulp horn, affected by the initial pulp inflammation. The results regarding the color of the partially infected circumpulpal dentin are presented in the Table 5.

Cases with a dark yellow circumpulpal dentin color are predominant, both with DOM and to the naked eye ( $p < 0.05$ ). In two thirds of the cases the color of the dentin studied is yellowish and in the rest of the cases it is light brown, and in only three of the cases it is with darker shades, the ratio between the colors being preserved with and without DOM ( $p > 0.05$ , Table 5).

**Table 5.** Color of the partially infected circumpulpal dentin without and with the use of a DOM<sup>1</sup> with 8x, 16x and 23.3x magnification

Color	Dark brown		Light brown		Dark yellow		total	
	N	% ± sp	N	% ± sp	N	% ± sp	N	100%
No microscope	3	7.5 ± 4.16	13	32.5 ± 7.41	24	60.0 ± 7.75	40	100%
With micro. – 8x	3	7.5 ± 4.16	11	27.5 ± 7.06	26	65.0 ± 7.54	40	100%
With micro. – 16x	3	7.5 ± 4.16	11	27.5 ± 7.06	26	65.0 ± 7.54	40	100%
With micro. – 23.3x	3	7.5 ± 4.16	11	27.5 ± 7.06	26	65.0 ± 7.54	40	100%
			T=4.490 p>0.05		T= 3.650 p>0.05			

The consistency of the partially infected dentin was assessed as averagely hard in all clinical cases studied – with code 3 (moderately hard dentin offering light resistance during probing under the *Bjørndal et al.*<sup>22</sup>) (Fig.2).



**Figure 2.** Photograph of an approximal carious lesion of a maxillary first left primary molar made with DOM at magnification 8x. Presence of partially infected dentine at the bottom of the cavity that may be preserved.

The use of DOM enables a more precise assessment of the partially infected dentin, with the aim being to preserve the dentin and arrest the carious process.

## DISCUSSION

In our study we found that when using a DOM with magnification 8x, a larger diversity of colors can be seen, with lighter shades of carious dentin being predominant, in comparison with the clinical-visual assessment with no magnification apparatus. Lighter shades of carious dentin are an indicator of faster developing caries lesions, with faster advancement towards the pulp and a weaker immune reaction on part of the odontoblasts. In such cases, slowing down the process is one of the aims of the treatment. It is achieved through limiting the microbial invasion. In our study we found, that no plausible differences in the registered color of the dentin between the various degrees of magnification were observed when using a DOM ( $p > 0.05$ ).

We found that the color of the carious dentin at the bottom of the lesion, observed under a DOM with magnification 8x, displays statistical

plausibility, greater diversity of colors, and a stronger predominance of the lighter shades in comparison with the color of the same dentin, when observed without a microscope ( $p < 0.05$ , Table 4). No difference can be seen in the various levels of magnification. The color of the carious dentin is related to the speed of development and progression of the carious process, which depends on the effectiveness of the defense reaction of the pulp-dentin complex, as well as on the severity of the inflammatory reaction in the pulp, and, to a degree, the reversibility of the inflammatory process.<sup>9-12,14,23</sup> The possibility of a more accurate assessment of the color characteristics of carious dentin when using DOM, regardless of the degree of magnification, provides an opportunity for a more accurate prognostic of the healing process.

In our study the dark carious dentin is predominant on the surface dentin. At the bottom, there is a greater diversity, with dark and light brown dentin being evenly distributed in about half of the lesions, while lighter shades were observed in a third to a quarter of the cases. Using DOM provides a greater accuracy and precision in the clinical visual assessment of the dentin present and it allows us to register some visible lightening of the carious dentin in its deep layers, which still corresponds to red fluorescence under the caries-detector. This fluorescence indicates an irreversible destruction and a strong microbial invasion, as well as faster advancement of the process towards the pulp.<sup>19,21</sup>

In clinical cases of asymptomatic closed pulpitis, the partially infected dentin which can be preserved, has been shown to be able to stimulate tertiary dentinogenesis and a healing process in the area of the underlying pulp horn, affected by the initial pulp inflammation. This dentin meets the Proface criterion: pink fluorescence with the presence of localized limited red spots in the area above the pulp. This fluorescence is an indicator of irreversible destruction of the dentin and strong microbial invasion, which favors a faster progressing of the inflammation towards the pulp.<sup>9,11,14</sup> In our study the results regarding the color of the partially infected circumpulpal dentin

are presented in the Table 5. Predominant are the cases with a dark yellow circumpulpal dentin color, visible both with DOM and to the naked eye ( $p < 0.05$ ).

A correct and precise assessment of this dentin is particularly important, considering the small volumes of dental structures found in primary teeth. The use of magnifying technology is an important condition for the correct treatment, the preservation of integrity of the pulp and for applying the biological approach. The use of DOM enables a more precise assessment of the partially infected dentin, with the aim being to preserve the dentin and arrest the carious process. The use of magnifying technology is an excellent diagnostic method for applying the microinvasive approach in the biological treatment of reversible pulpitis. DOM-assisted assessment gives more opportunities for preserving the partially infected dentin, which ensures the integrity of the pulp chamber and thus we try to stimulate internal remineralization, tertiary dentinogenesis, as well as the healing process in the pulp. Specialized literature offers no researches on the use of DOM as an assistance to selective excavation in the treatment of reversible pulpitis, although there are various authors reporting on their studies aimed at seeking and developing a number of methods for biological treatment of reversible pulpitis.<sup>12-14</sup> This study shows, that the use of DOM is an asset to controlled excavation with a view to the clinical assessment of the changes of the color of the dentin, and it provides a more accurate overall assessment compared to conventional visual-tactile diagnosis (Tables 3,4,5). Assessment of changes in the color characteristics of the dentin is an important diagnostic indicator for a non-invasive and precise approach in the biological treatment of pulpitis in primary teeth.<sup>11,14</sup> Differentiating the infected dentin at various degrees of demineralization is particularly important in reversible pulpitis, mostly with a view to applying indirect pulp cupping as a method of treatment.<sup>11,13,14,23</sup>

## CONCLUSIONS

- In the biological treatment of asymptomatic closed pulpitis in primary teeth, the use of DOM

magnifying technology gives the opportunity for a precise and accurate assessment during the course of excavation.

- The use of DOM shows a: larger diversity in the colors and nuances of the carious dentin, with lighter shades being predominant. DOM gives an opportunity for a better precision in determining the speed of the carious process, which is in direct relation to the defensive ability of the pulp-dentin complex;
- The use of fluorescent control with *Proface* is recommended during the course of excavation, and the use of magnifying technology complements the objective assessment in the area of the circumpulpal dentin which, in reversible pulpitis of primary teeth, must be preserved and used for the stimulation of the healing process.

## ACKNOWLEDGEMENT

This work was supported by the Council of Medical Science at Medical University of Sofia, Bulgaria under Infrastructure Project with Contract No. 207 / 12.12.2018.

## CONFLICT OF INTEREST STATEMENT

The authors declare that they have no competing interests.

## REFERENCES

1. Peneva M, Kabakchieva R, Rashkova M, Gateva N, Doychinova L, Zhegova G, editors. Clinic of pediatric dentistry. 1<sup>st</sup> ed. Sofia: Bedemot; 2018.
2. Mitova N, Rashkova M, Uzunov T, Kosturkov D, Petrunov V. Controlled excavation for cavitated dentinal caries with visual-tactile method and fluorescence with Proface W&H. Problems of dental medicine 2014; 40: 13-21.
3. Mitova N, Rashkova M, Zhegova G, Uzunov T, Kosturkov D, Ishkitiev N. Comparison of different methods of excavation control for minimally invasive caries treatment. STOMAEDUJ 2016; 3: 98-106.
4. Mitova N. Minimally invasive approach to dentine caries of permanent teeth in children. PhD Thesis. Sofia; 2016. [In Bulgarian].
5. Mitova N, Rashkova M, Gergova R, Jegova G, Nocheva Hr, Krastev D. Treatment of deep dentinal caries with micro-invasive technique - clinical and

microbiological evaluation. SYLWAN 2015; 159: 498-511.

6. Schwendicke F, Jäger AM, Paris S, Hsu LY, Tu YK. Treating pit-and-fissure caries: a systematic review and network meta-analysis. *J Dent Res* 2015; 94: 522-523.

7. Murgel C. Microdentistry: Concepts, Methods, And Clinical Incorporation. *Int J MicroDent* 2010; 2: 56-63.

8. Fanibunda U, Meshram G, Warhadpande M. Evolutionary Perspectives On The Dental Operating Microscope: A Macro Revolution At The Micro Level. *Int J MicroDent* 2010; 2: 15-19.

9. Ricketts D, Lamont T, Innes NP, Kidd E, Clarkson JE. Operative caries management in adults and children. *Cochrane Database Syst Rev* 2013; 28:CD003808.

10. Schwendicke F, Paris S, Tu Y. Effects of using different criteria and methods for caries removal: a systemic review and network meta-analysis. *J Dent*. 2015; 43: 1-15.

11. Schwendicke F *et al.* Managing caries removal: consensus recommendations on carious tissue removal. *Adv Dent Res* 2016; 28: 58-67.

12. Schwendicke F, Frenken J, Innes N. Caries Excavation Evolution of Treating Cavitated Carious Lesions. *Removing Carious Tissue: Why and How?* *Adv Dent Res* 2016; 28: 56-65.

13. Innes NP *et al.* Managing caries lesion: consensus recommendations on terminology. *Adv Dent Res* 2016; 28: 49-57.

14. Smaïl-Faugeron V, Glenny AM, Courson F, Durieux P, Muller-Bolla M, Fron Chabouis H. Pulp treatment for extensive decay in primary teeth. *Cochrane Database of Systematic Reviews* 2018; DOI: 10.1002/14651858.CD003220.pub3.

15. Arslan I, Aydınoglu S, Baygin O, Tuzuner T, Sirin M. Comparative Analysis of Manual, Rotary and Reciprocal Systems on Primary Teeth Root Canals: An In Vitro Scanning Electron Microscopy Study. *Cumhuriyet Dent J* 2019; 22: 299-309.

16. Ziya M, Yüksel BN, Sarı Ş. Root Canal Morphology of Mandibular Primary Molars: A Micro-CT Study. *Cumhuriyet Dent J* 2019; 22:24.

17. Santamaria RM, Innes NP, Machiulskiene V, Evans DJ, Splieth CH. Caries management strategies for primary molars: 1-yr randomized control trial results. *J Dent Res* 2014; 93: 1062-1069.

18. Iwami Y, Shimizu A, Narimatsu M, Hayashi M, Takeshige F, Ebisu S. Relationship between bacterial infection and evaluation using a laser fluorescence device, DIAGNOdent. *Eur J Oral Sci* 2004; 112: 419-423.

19. Lai G1, Zhu L, Xu X, Kunzelmann KH. An in vitro comparison of fluorescence-aided caries excavation and conventional excavation by microhardness testing. *Clin Oral Investig* 2014; 18: 599-605.

20. Lennon A *et al.* Fluorescence-aided caries excavation (face) caries detector and conventional caries excavation in primary teeth. *Pediatric Dentistry*. 2009; 31: 316-319.

21. Mitova N, Rashkova M. Clinical protocol for microinvasive treatment of deep dentine caries of permanent teeth in children. *Problems of dental medicine*. 2017; 43: 35-42.

22. Bjørndal L, Larsen T, Thylstrup A. A clinical and microbiological study of deep carious lesions during stepwise excavation using long treatment intervals. *Caries Res* 1997; 31: 411-417.

23. Schwendicke F, Dorfer CE, Paris S. Incomplete caries removal: a systemic review and meta-analysis. *J Dent Res* 2013; 92: 306-314.



## INVESTIGATION OF THE CLINICAL AND MICROBIOLOGICAL EFFECTS OF DIFFERENT TOOTHPASTES: *IN-VIVO* STUDY

### ABSTRACT

**Objectives:** The purpose of this study is to compare the clinical, antibacterial and microbiological effects of the non-fluoride and fluoride toothpastes.

**Materials and Methods:** In this study eighty children (3 to 12 years old) were randomly divided into four groups and followed for four weeks. The first and second groups (40 children, 6-12 years) used different fluoride containing toothpastes; the third and fourth groups (40 children, 3-5 years) used non-fluoride toothpastes. The halitosis score, plaque index, gingival index, bleeding index, buffering capacities, *Mutans Streptococci*, *Lactobacilli* and yeast counts were recorded on 1<sup>st</sup> day, 7<sup>th</sup> day, 15<sup>th</sup> day and 30<sup>th</sup> day. The first and second groups; the third and fourth groups were compared with each other. Data were analyzed statistically by using Mann Whitney U tests, Wilcoxon Sign Test, Fisher Freeman Halton Exact Test and Mc Nemar Test with a significance level of  $p < 0.05$ .

**Results:** Statistically significant association was not found in the mean scores of halitosis, gingival index, plaque index, bleeding index, buffering capacity, *Mutans Streptococci*, *Lactobacilli* and yeast ( $p > 0.05$ ), between groups on the first day. All four toothpastes produced statistically significant reductions from 1st day to 30th days in scores of halitosis, plaque index, gingival index, bleeding index and buffering capacity ( $p < 0.01$ ;  $p < 0.05$ ), within groups. Statistically significant reductions were found according to in *Mutans Streptococci*, counts from 1st day to 30th day for group I, II and III ( $p < 0.05$ ); but was not found statistically significant changes in Group IV on the 30th days ( $p > 0.05$ ).

**Conclusions:** All tested toothpastes proved to be safe and significantly effective clinical and microbiological features.

**Key Words:** Child, fluoride, toothpaste, mutans streptococci, saliva.

\*Mine KORUYUCU<sup>1</sup>  
Sinem BİRANT<sup>2</sup>  
Nursen TOPCUOĞLU<sup>3</sup>  
Güven KÜLEKÇİ<sup>3</sup>  
Figen SEYMEN<sup>1</sup>

ORCID IDs of the authors:

M.K. 0000-0002-2077-5095

S.B. 0000-0002-3990-7270

N.T. 0000-0002-5041-1129

G.K. 0000-0002-7391-1310

F.S. 0000-0001-7010-2035

<sup>1</sup> Istanbul University, Faculty of Dentistry, Department of Pedodontics, Istanbul, Turkey

<sup>2</sup> Private Practice, Istanbul, Turkey

<sup>3</sup> Istanbul University, Faculty of Dentistry, Department of Microbiology, Istanbul, Turkey

Received : 25.09.2019

Accepted : 18.12.2019

**INTRODUCTION**

Periodontal diseases and dental caries are the two most common oral infections worldwide. Endogenous oral bacterial species and their metabolites play an important role in the initiation and progression of these infections.<sup>1,2</sup> Apart from this, caries is a multifactorial disease, so it can be affected by factors such as dental biofilm, sugar, host and time.<sup>3,4</sup> It is caused by impairment of the balance between the microflora in the mouth and the host biology.<sup>5</sup>

Acid-producing and tolerating microorganisms such as *Mutans Streptococci (MS)*, *Lactobacilli (LB)* and yeast, are seen as organisms that are responsible for the formation of caries.<sup>6,7</sup> Therefore, managing the mechanism of caries by controlling or removing the acidogenic bacteria has an important place in modern non-invasive treatment model of caries treatment with antibacterial approach.<sup>8,9</sup>

Biofilm control is an important procedure for the removal of microbial dental biofilm to prevent tooth decay and periodontal disease and to prevent the accumulation of teeth and adjacent gingival surfaces.<sup>6,10</sup>

It is thought that toothbrushing habit has a potential to removal dental biofilm and prevent caries with the fluoride toothpaste, one of these protective and preventive applications.<sup>11,12</sup>

Toothbrushing is one of the easiest individual practices used to ensure good oral hygiene. Regular toothbrushing habits that are effectively done with the selected toothpaste help to remove the dental plaque, one of the factors that play a role in the formation of tooth decay. Today, there are various toothbrushes and toothpastes, specially designed for children on the market.<sup>13,14</sup>

Toothpastes with antimicrobial effects have an important effect on the removal of both dental biofilm and gingivitis.<sup>15</sup> Studies on the use of antimicrobials in the prevention of caries have been going on for over 5 years.<sup>16,17</sup>

The fluoride-containing toothpastes are useful and the easiest way to maintain oral health by controlling the caries mechanism used with individual applications in the provision and development of oral hygiene.<sup>4,9,13,16</sup> Fluoride is to be an important source of material in the prevention and treatment of caries due to its cariostatic and remineralization properties.<sup>5,18,19,20</sup> Fluoride has a direct effect on MS biofilm formation, possibly due to the weakening of water-insoluble glucan production associated with the suppressed release of GtfB and GtfC from the bacterial cell membrane.<sup>21</sup>

The aimed of this study to investigate and compare the clinical and microbiological effects of sodium chlorite and fluoride-containing toothpastes *in-vivo*. The fluoride-containing toothpaste, the fluoride and sodium chlorite containing toothpaste, sodium chlorite containing and fluoride-free toothpaste were selected as the experimental groups. The null hypothesis of the study is that the efficacy of fluoride-containing toothpastes are better than the fluoride-free and chloride-containing toothpastes.

**MATERIALS AND METHODS**

The study was approved by the Ethics Committee of the Istanbul University Faculty of Dentistry (2013/368) and was carried out in agreement with the Declaration of Helsinki principles. The informed contents were obtained from all participants and the study design followed CONSORT 2010 Statement: Updated guidelines for reporting parallel group randomized trials.<sup>22</sup>

All tested toothpastes and flow chart were shown in Table 1 and Figure 1.

**Table 1.** Materials used in this study

Groups	Product and manufacturer	Content
Group I	Sensodyne Pronamel (GlaxoSmithKline, USA)	1450 ppm NaF containing toothpaste
Group II	Oxyfresh (Oxyfresh, USA)	0.235% NaF and sodium chlorite containing toothpaste
Group III	Nenedent 2-4 (Dentinox, Berlin, Germany)	Fluoride- free toothpaste
Group IV	Oxyfresh (Oxyfresh, USA)	Fluoride-free, sodium chlorite- containing toothpaste

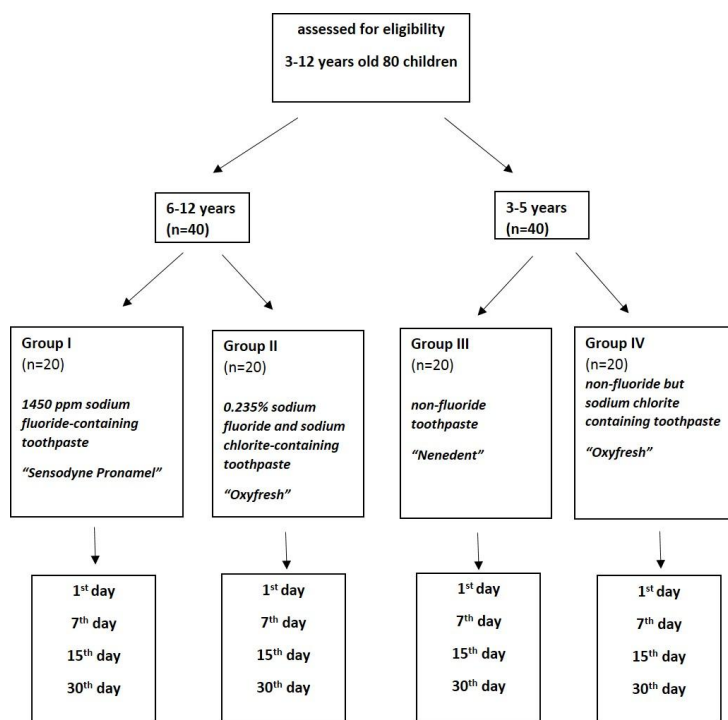


Figure 1. Flow chart of the study

The four commercially available toothpastes were: (1) 1450 ppm sodium fluoride-containing toothpaste (Sensodyne Pronamel 6+); (2) sodium chlorite and 0.235% sodium fluoride-containing toothpaste (Oxyfresh Toothpaste Fluoride); (3) nonfluoride toothpaste (Nenedent 2-4); and (4) nonfluoride toothpaste containing sodium chlorite (Oxyfresh Toothpaste Original). The study population was comprised of 80 healthy children who did not have any systemic problems, did not use regular medication, did not use antibiotics in the last 1 month, familiar with the habit of brushing teeth. 80 children (43 M, 37 F), 3-to 12-year-old (mean age  $7.51 \pm 2.24$ ) divided into four groups, were followed for four weeks. The first group (20 children, 6-12 years) used 1450 ppm sodium fluoride-containing toothpaste (Group I); the second group (20 children, 6-12 years) used 0.235% sodium fluoride and sodium chlorite-containing toothpaste (Group II); the third group (20 children, 3-5 years) used non-fluoride toothpaste (Group III) and the fourth group (20 children, 3-5 years) used non-fluoride but sodium chlorite containing toothpaste (Group IV). Initially, brushing frequency, decayed-missing-filled teeth were recorded clinically. The unstimulated saliva samples were collected in the morning hours and at least 2 hours after the last food or drink in sterile containers and analyzed

within one hour of collection. The Ericsson's method was used to measure the buffering capacity.<sup>23</sup> At the end of each quantitative culture phase, we determined the mean colony forming units (CFUs) for microbiological analysis. The halitosis score (Breath Checker TANITA Slim white HC-212S-WH), Silness & Loe plaque index, Silness & Loe gingival index, bleeding index, salivary buffering capacities, salivary *Mutans Streptococci*, *Lactobacilli* and yeast counts were recorded 1<sup>st</sup> day, 7<sup>th</sup> day, 15<sup>th</sup> day and 30<sup>th</sup> day. The first and second groups; the third and fourth groups were compared with each other.

The sample size calculation resulted in an 80% power at a 5% level of statistical significance and a 10% the difference between the groups, requiring 12 children for each group. In this study, we evaluated 20 children for each group. All measurements were performed by a single specialist (MK).

Statistical analysis was performed using the Statistical Package for the Social Sciences (SPSS, IBM Corporation, Version 21.0; Armonk, NY, USA) software. The differences between the groups were statistically analyzed using the Mann Whitney U tests, Wilcoxon Sign Test, Fisher Freeman Halton Exact Test and Mc Nemar Test with a significance level of  $p < 0.05$ .



**RESULTS**

The mean DMFT (Decayed, Missing, Filled Tooth), DMFS (Decayed, Missing, Filled Surface), dft (decayed, filling tooth) and dfs (decayed, filling surface) are 0.8±1.54; 1.9±4.19; 4.45±3.36; 9±7.43 for 1st group and 1.75±1.92; 3.3±4.40; 4.65±2.91; 10.95±7.29 for 2nd group.

The mean df, dfs are 6.6±5.01; 11.9±8.70 for 3rd group and 8.4±2.98; 17.5±8.17 for 4th group. The mean scores of brushing frequency are in Table 2. No statistically significant difference was found between the brushing frequency and caries scores between the groups (p>0.05) (Table 2).

**Table 2.** Evaluation of brushing frequency, DMFT, DMFs, dft, dfs

	Group I Mean±SD	Group II Mean±SD	p	Group III Mean±SD	Group IV Mean±SD	p
Brushing frequency	0.8±0.77 (1)	1.2±1.5 (1)	<b>0.170</b>	1.35±0.88 (2)	1.5±0.61 (2)	<b>0.795</b>
DMFT	0.8±1.54 (0)	1.75±1.92 (1.5)	<b>0.068</b>	-	-	-
DMFS	1.9±4.19 (0)	3.3±4.40 (1.5)	<b>0.096</b>	-	-	-
dft	4.45±3.36(4)	4.65±2.91 (3.5)	<b>0.774</b>	6.6±5.01 (8)	8.4±2.98 (8)	<b>0.225</b>
dfs	9±7.43 (8)	10.95±7.29 (9)	<b>0.378</b>	11.9±8.70 (12)	17.5±8.17 (14.5)	<b>0.082</b>

*Mann Whitney U Test*

Statistically, significant association was not found the mean scores of halitosis, plaque index, gingival index, bleeding index, buffering capacity, MS, LB and yeast between the groups (p>0.05) (Table 3-10).

The mean scores of halitosis, plaque index, gingival index, bleeding index and buffering capacity were found to be statistically significantly decreased from day 1 to day 30 among all groups (p <0.01; p <0.05) (Table 3- 7).

**Table 3.** Evaluation of halitosis scores

Halitosis score	Group I Mean±SD	Group II Mean±SD	<sup>1</sup> p	Group III Mean±SD	Group IV Mean±SD	<sup>1</sup> p
1st day	0.45±0.83 (0)	0.8±0.70 (1)	<b>0.081</b>	0.8±0.77 (1)	1.3±0.92 (1)	<b>0.063</b>
7th day	0.25±0.44(0)	0.45±0.51 (0)	<b>0.190</b>	0.2±4.10 (0)	0.35±0.67 (0)	<b>0.603</b>
15th day	0±0 (0)	0±0 (0)	<b>1.000</b>	0.5±0.22 (0)	0.05±0.22 (0)	<b>1.000</b>
30th day	0±0 (0)	0±0 (0)	<b>1.000</b>	0±0 (0)	0±0 (0)	<b>1.000</b>
1st-7th day <sup>2</sup> p	0.206	0.008**		0.001**	0.001**	
1st-15th day <sup>2</sup> p	0.024*	0.001**		0.001**	0.001**	
1st-30th day <sup>2</sup> p	0.024*	0.001**		0.001**	0.001**	

<sup>1</sup> Mann Whitney U Test

<sup>2</sup> Wilcoxon Sign Test

\*p<0.05

\*\*p<0.01

**Table 4.** Evaluation of plaque index

Plak index	Group I Mean±SD	Group II Mean±SD	<sup>1</sup> p	Group III Mean±SD	Group IV Mean±SD	<sup>1</sup> p
1st day	0.69±0.58 (0.75)	0.73±0.69 (0.5)	<b>0.935</b>	0.56±0.49 (0.5)	0.78±0.47 (0.75)	<b>0.073</b>
7th day	0.56±0.49 (0.5)	0.41±0.59 (0)	<b>0.200</b>	0.22±0.5 (0)	0.49±0.51 (0.5)	<b>0.076</b>
15th day	0.42±0.40 (0.5)	0.21±0.3 (0)	<b>0.070</b>	0.08±0.23 (0)	0.15±0.32 (0)	<b>0.604</b>
30th day	0.23±0.24 (0.12)	0.08±0.12 (0)	<b>0.048*</b>	0.01±0.06 (0)	0.01±0.06 (0)	<b>1.000</b>
1st-7th day <sup>2</sup> p	0.011*	0.001**		0.001**	0.001**	
1st-15th day <sup>2</sup> p	0.001**	0.001**		0.001**	0.001**	
1st-30th day <sup>2</sup> p	0.001**	0.001**		0.001**	0.001**	

<sup>1</sup> Mann Whitney U Test

<sup>2</sup> Wilcoxon Sign Test

\*p<0.05

\*\*p<0.01

**Table 5.** Evaluation of gingival index

Gingival index	Group I Mean±SD	Group II Mean±SD	<sup>1</sup> p	Group III Mean±SD	Group IV Mean±SD	<sup>1</sup> p
1st day	0.36±0.45 (0.19)	0.38±0.39 (0.39)	<b>0.645</b>	0.23±0.21 (0.25)	0.57±0.27 (0.5)	<b>0.001**</b>
7th day	0.27±0.33 (0.08)	0.16±0.27 (0)	<b>0.299</b>	0.08±0.18 (0)	0.17±0.32 (0)	<b>0.393</b>
15th day	0.18±0.24 (0)	0.08±0.17 (0)	<b>0.090</b>	0.03±0.09 (0)	0.03±0.11 (0)	<b>0.594</b>
30th day	0.11±0.17 (0)	0.03±0.08 (0)	<b>0.065</b>	0.01±0.04 (0)	0.01±0.06 (0)	<b>0.594</b>
1st-7th day <sup>2</sup> p	0.043*	0.001**		0.001**	0.001**	
1st-15th day <sup>2</sup> p	0.005**	0.001**		0.001**	0.001**	
1st-30th day <sup>2</sup> p	0.005**	0.001**		0.001**	0.001**	

<sup>1</sup> Mann Whitney U Test

<sup>2</sup> Wilcoxon Sign Test

\*p<0.05

\*\*p<0.01

Table 6. Evaluation of bleeding index

Bleeding index	Group I	Group II	<sup>1</sup> p	Group III	Group IV	<sup>1</sup> p
	Mean±SD	Mean±SD		Mean±SD	Mean±SD	
1st day	16.88±19.57 (18.8)	24.38±25.8 (25)	<b>0.421</b>	25.63±23.46 (25)	36.25±18.98 (25)	<b>0.042*</b>
7th day	15±15.5 (18.8)	12.5±18.58 (0)	<b>0.432</b>	12.5±20.28 (0)	11.25±20.64 (0)	<b>0.769</b>
15th day	8.13±13.62 (0)	3.75±8.21 (0)	<b>0.270</b>	6.88±15.95 (0)	2.5±11.18 (0)	<b>0.172</b>
30th day	2.5±6.54 (0)	1.88±6.12 (0)	<b>0.655</b>	3.13±7.98 (0)	1.25±5.59 (0)	<b>0.311</b>
1st-7th day <sup>2</sup> p	0.180	0.007**		0.001**	0.001**	
1st-15th day <sup>2</sup> p	0.004**	0.003**		0.001**	0.001**	
1st-30th day <sup>2</sup> p	0.003**	0.003**		0.001**	0.001**	

<sup>1</sup>Mann Whitney U Test

<sup>2</sup>Wilcoxon Sign Test

\*p<0.05

\*\*p<0.01

Table 7. Evaluation of buffering capacity

Buffering capacity		Group I	Group II	<sup>1</sup> p	Group III	Group IV	<sup>1</sup> p
		n (%)	n (%)		n (%)	n (%)	
1st day	High	3 (%15)	5 (%26.3)	<b>0.209</b>	5 (%27.8)	5 (%25)	<b>0.883</b>
	Medium	15 (%75)	9 (%47.4)		11 (%61.1)	14 (%70)	
	Low	2 (%10)	5 (%26.3)		2 (%11.1)	1 (%5)	
7th day	High	3 (%15.8)	1 (%5.9)	<b>0.507</b>	7 (%35)	4 (%20)	<b>0.651</b>
	Medium	12 (%63.2)	14 (%82.4)		11 (%55)	14 (%70)	
	Low	4 (%21.1)	2 (%11.8)		2 (%10)	2 (%10)	
15th day	High	1 (%5)	3 (%15.8)	<b>0.272</b>	3 (%15.8)	1 (%5.3)	<b>0.307</b>
	Medium	13 (%65)	14 (%73.7)		13 (%68.4)	17 (%89.5)	
	Low	6 (%30)	2 (%10.5)		3 (%15.8)	1 (%5.3)	
30th day	High	1 (%5)	2 (%10.5)	<b>0.865</b>	1 (%5.9)	3 (%15.8)	<b>0.605</b>
	Medium	16 (%80)	14 (%73.7)		16 (%94.1)	15 (%78.9)	
	Low	3 (%15)	3 (%15.8)		0 (%0)	1 (%5.3)	
1st-7th day <sup>2</sup> p		0.607	0.135		0.368	0.801	
1st-15th day <sup>2</sup> p		0.097	0.082		0.717	0.172	
1st-30th day <sup>2</sup> p		0.333	0.160		0.180	0.392	

<sup>1</sup>Fisher Freeman Halton Exact Test

<sup>2</sup>Mc Nemar Testi

There was a statistically significant decrease in the number of MS from day 1 to day 30 in Group I,II,III (p <0.05). But for Group IV, statistically

significant difference was not found in the number of MS on day 30 (p>0.05) (Table 8).

Table 8. Evaluation of MS counts

MS		Group I	Group II	<sup>1</sup> p	Group III	Group IV	<sup>1</sup> p
		n (%)	n (%)		n (%)	n (%)	
1st day	High	17 (%85)	15 (%75)	<b>0.695</b>	14 (%70)	14 (%70)	<b>0.488</b>
	Medium	3 (%15)	4 (%20)		4 (%20)	6 (%30)	
	Low	0 (%0)	1 (%5)		2 (%10)	0 (%0)	
7th day	High	11 (%55)	8 (%40)	<b>0.546</b>	14 (%70)	10 (%50)	<b>0.333</b>
	Medium	8 (%40)	9 (%45)		6 (%30)	9 (%45)	
	Low	1 (%5)	3 (%15)		0 (%0)	1 (%5)	
15th day	High	8 (%40)	8 (%40)	<b>1.000</b>	13 (%65)	11 (%55)	<b>0.719</b>
	Medium	10 (%50)	9 (%45)		6 (%30)	6 (%30)	
	Low	2 (%10)	3 (%15)		1 (%5)	3 (%15)	
30th day	High	7 (%35)	8 (%40)	<b>0.852</b>	13 (%65)	12 (%60)	<b>1,000</b>
	Medium	8 (%40)	6 (%30)		5 (%25)	6 (%30)	
	Low	5 (%25)	6 (%30)		2 (%10)	2 (%10)	
1st-7th day <sup>2</sup> p		0.014*	0.046*		0.458	0.025*	
1st-15th day <sup>2</sup> p		0.019*	0.046*		0.572	0.034*	
1st-30th day <sup>2</sup> p		0.019*	0.019*		0.072	0.102	

<sup>1</sup>Fisher Freeman Halton Exact Test

<sup>2</sup>Mc Nemar Testi

\*p<0.05

Statistically significant reductions were not found according to in LBand yeast counts from 1<sup>st</sup> day to 15<sup>th</sup> day, while statistically significant reduction

was found in the 30<sup>th</sup> day for the Group I (p<0.01). Statistically significant reductions were not found according to in LBand yeast count from

1<sup>st</sup> day to 30<sup>th</sup> day for group II, III and IV (p>0.05) (Table 9-10).

**Table 9.** Evaluation of LB counts

LB		Group I	Group II	<sup>1</sup> p	Group III	Group IV	<sup>1</sup> p
		n (%)	n (%)		n (%)	n (%)	
1st day	High	16 (%80)	9 (%45)	<b>0.066</b>	13 (%65)	13 (%65)	<b>0,175</b>
	Medium	3 (%15)	9 (%45)		7 (%35)	4 (%20)	
	Low	1 (%5)	2 (%10)		0 (%0)	3 (%15)	
7th day	High	14 (%70)	8 (%40)	<b>0.079</b>	10 (%50)	14 (%70)	<b>0,122</b>
	Medium	6 (%30)	9 (%45)		9 (%45)	3 (%15)	
	Low	0 (%0)	3 (%15)		1 (%5)	3 (%15)	
15th day	High	12 (%60)	5 (%25)	<b>0.082</b>	9 (%45)	12 (%60)	<b>0,543</b>
	Medium	6 (%30)	10 (%50)		9 (%45)	5 (%25)	
	Low	2 (%10)	5 (%25)		2 (%10)	3 (%15)	
30th day	High	4 (%20)	5 (%25)	<b>1.000</b>	8 (%40)	11 (%55)	<b>0,698</b>
	Medium	11 (%55)	11 (%55)		8 (%40)	6 (%30)	
	Low	5 (%25)	4 (%20)		4 (%20)	3 (%15)	
1st-7th day <sup>2</sup> p		0.564	0.513		0.223	0.317	
1st-15th day <sup>2</sup> p		0.135	0.055		0.115	0.572	
1st-30th day <sup>2</sup> p		0.003**	0.228		0.112	0.223	

<sup>1</sup> Fisher Freeman Halton Exact Test

<sup>2</sup> Mc Nemar Testi

\*p<0.05

**Table 10.** Evaluation of yeast counts

Yeast		Group I	Group II	<sup>1</sup> p	Group III	Group IV	<sup>1</sup> p
		n (%)	n (%)		n (%)	n (%)	
1st day	High	3 (%15)	0 (%0)	<b>0.251</b>	2 (%10)	1 (%5)	<b>0.378</b>
	Medium	10 (%50)	10 (%50)		10 (%50)	6 (%30)	
	Low	7 (%35)	10 (%50)		8 (%40)	13 (%65)	
7th day	High	2 (%10)	1 (%5)	<b>0.028*</b>	1 (%5)	0 (%0)	<b>0.748</b>
	Medium	12 (%60)	5 (%25)		8 (%40)	7 (%35)	
	Low	6 (%30)	14 (%70)		11 (%55)	13 (%65)	
15th day	High	2 (%10)	0 (%0)	<b>0.169</b>	0 (%0)	1 (%5)	<b>0.451</b>
	Medium	8 (%40)	5 (%25)		6 (%30)	3 (%15)	
	Low	10 (%50)	15 (%75)		14 (%70)	16 (%80)	
30th day	High	0 (%0)	0 (%0)	<b><sup>3</sup>0.479</b>	0 (%0)	1 (%5)	<b>0.176</b>
	Medium	7 (%35)	4 (%20)		9 (%45)	4 (%20)	
	Low	13 (%65)	16 (%80)		11 (%55)	15 (%75)	
1st-7th day <sup>2</sup> p		0.368	0.180		0.135	0.135	
1st-15th day <sup>2</sup> p		0.135	0.125		0.069	0.083	
1st-30th day <sup>2</sup> p		0.018*	0.070		0.572	0.317	

<sup>1</sup> Fisher Freeman Halton Exact Test <sup>3</sup> Continuity (Yates) Correction

<sup>2</sup>Mc Nemar Testi

\*p<0.05

## DISCUSSION

Fluoride toothpaste has been reported to be the most important treatment method to reduce the incidence of caries. Topically applied fluoride reduces enamel demineralization in the presence of bacterial plaque acid and then improves natural remineralization processes in the presence of salivary minerals.<sup>12,24</sup>

Several clinical trials have shown that sodium fluoride provides remineralization on demineralized white spot lesions.<sup>12,20</sup> However, based on various mechanisms, fluoride also exhibits some antibacterial and antifungal effects such as metabolic interference and reduction of dental plaque acidogenicity.<sup>10,15</sup>

In the meta-analysis studies of the preschool children, toothbrushing with fluoride toothpaste

significantly reduced the prevalence of caries scores in primary tooth decay.<sup>25,26,33,34,35,36,37,38,39,40</sup>

In our study, statistically significant difference was not found between groups according to brushing frequency. Also, there weren't any differences between groups according to caries scores.

Patil *et al.*<sup>27</sup> examined the effects of different oral hygiene practices on oral malodor *in-vivo* in 120 children aged between 7-15 years. Children were divided into groups according to 4 different oral hygiene categories (tooth brushing with fluoride-containing toothpaste, tongue cleaning, mouth rinsing, combination group). It had been shown that the combined group was even more effective when all oral hygiene procedures resulted in halitosis significantly reduced as a result of the study. In this study, statistically

significant association was not found between groups and the mean scores of halitosis.

Cagetti *et al.*<sup>28</sup> evaluated the effects of two different toothpastes in controlling supragingival dental plaque and bleeding on probing in 48 healthy schoolchildren aged between 8-10 years. The children were selected randomly and divided into two groups, using the two different toothpastes (experimental toothpaste group containing fluoride, triclosan, cetylpyridinium chloride, and essential oils, control toothpaste group containing fluoride without another antibacterial ingredient) twice a day for 2 minutes. There was no statistically significant difference between the two groups regarding bleeding on probing at the end of the 4-weeks, whereas the decrease in plaque index in the experimental group was found to be higher at the statistically significant level than the control group. In the present study, despite all of the toothpaste groups showed statistically significant differences in decreasing scores of halitosis, gingival index, plaque index, bleeding index, buffering capacity, no statistically significant differences were found in the mean scores of these parameters between groups.

In 2007, Magnusson *et al.*<sup>29</sup> found that the amount of MS decreased significantly after 6 months of use of triclosan, aminofluoride and stannous fluoride- containing toothpastes. In this study, it was found that all toothpastes with and without fluoride reduced the number of MS after 30 days.

Patil *et al.*<sup>11</sup> have shown the effects of fluoride-containing toothpastes on oral microorganisms, particularly on the reduction of MS in their study. All toothpastes used in the study have been reported to have antibacterial activity and it is stated that the presence of fluoride provides antimicrobial effects. In our study, there was a decrease in the number of MS in all fluoride and fluoride-free toothpastes. There was no statistically significant difference in the presence of fluoride in toothpastes that was effective in reducing the number of MS.

Carvalho *et al.*<sup>30</sup> evaluated the antimicrobial activity of the toothpastes *in-vitro*. Experimental toothpastes are chosen in cage-based, mango-based, fluoride-free and free of three fluorides, including extracts. As a result of the study, it has been reported that fluoride free toothpastes have inhibitory activity against MS and *Lactobacillus Acidophilus*.<sup>3,11,30</sup>

*In-vitro* studies have shown that the presence of fluoride at constant low concentration allows MS to produce less acid. Fluoride concentrates on the tooth plate, inhibiting carbohydrate metabolism. Thus, lactic acid production is reduced. At the same time, adhesive polysaccharides also affect the production of bacteria.<sup>31</sup> Studies have indicated that fluoride toothpaste results from the combined effect of fluoride-free components on a significant portion of the antimicrobial activity against MS.<sup>32</sup>

## CONCLUSIONS

Considering the limitations of this *in-vivo* study include the differences among individuals, salivary characteristics, and the differences between antimicrobial substances in saliva; the lack of control over the frequency and shape of brushing of participating children. At the beginning of this study, we informed that children should be brushed under the supervision of parents. In both age groups, we did not experience any problems with brushing and appointment timing. However, it should be kept in mind that personal skills may affect the results of the study.

In this study fluoride-free, chlorite-containing and fluoride-containing toothpastes were used. All tested toothpastes proved to be safe and significantly effective clinical and microbiological features.

Therefore, further clinical studies are needed to demonstrate the antimicrobial activity of toothpastes and to standardize differences.

## ACKNOWLEDGMENTS

This research was presented at the 93<sup>rd</sup> General Session & Exhibition of the International Association for Dental Research (IADR), 44<sup>th</sup> Annual Meeting of the American Association for Dental Research (AADR) and the 39<sup>th</sup> Annual

Meeting of the Canadian Association for Dental Research (CADR). March 11-14, 2015, Boston, Mass., USA, 2015. Seymen F, Koruyucu M, Topcuoglu N. Külekçi G. Investigation of the clinical and microbiological effects of different toothpastes.

### CONFLICTS OF INTEREST STATEMENT

The authors declare that there is no competing interest.

### **Farklı Diş Macunlarının Klinik ve Mikrobiyolojik Etkilerinin İncelenmesi: In Vivo Çalışma ÖZ**

**Amaç:** Bu çalışmanın amacı, florür içeren ve içermeyen diş macunlarının klinik, antibakteriyel ve mikrobiyolojik etkilerini karşılaştırmaktır. **Gereç ve Yöntemler:** Bu çalışmada 3-12 yaş arası 80 çocuk dört gruba ayrıldı ve dört hafta boyunca takip edildi. Birinci ve ikinci gruplar (40 çocuk, 6-12 yaş) farklı florürlü diş macunları kullandı; üçüncü ve dördüncü gruplar (40 çocuk, 3-5 yaş) florür içermeyen diş macunları kullandılar. Ağız kokusu skoru, plak indeksi, gingival indeks, kanama indeksi, tamponlama kapasiteleri, Mutans Streptokokları, Lactobacilli ve maya sayıları 1., 7., 15. ve 30. günde kaydedildi. Birinci ve ikinci grup; üçüncü ve dördüncü gruplar birbirleriyle karşılaştırıldı. Veriler istatistiksel olarak Mann Whitney U testi, Wilcoxon Sign Testi, Fisher Freeman Halton Exact Testi ve Mc Nemar Testi kullanılarak  $p < 0,05$  anlamlılık düzeyinde analiz edildi. **Bulgular:** İlk gün; gruplar arasında, ağız kokusu, gingival indeks, plak indeksi, kanama indeksi, tamponlama kapasitesi, S Mutans, Lactobacilli ve maya ortalamaları arasında istatistiksel olarak anlamlı ilişki bulunmadı ( $p > 0,05$ ). Dört diş macununun her biri, gruplar arasında, 1. günden 30. güne ağız kokusu, plak indeksi, gingival indeks, kanama indeksi ve tamponlama kapasitesi skorlarında istatistiksel olarak anlamlı azalma sağlamıştır ( $p < 0,01$ ;  $p < 0,05$ ). Grup I, II ve III'te; S. Mutans değerleri 1. günden 30. güne kadar istatistiksel olarak azalma gösterirken ( $p < 0,05$ ); Grup IV'te 30. günde istatistiksel olarak anlamlı bir değişiklik izlenmemiştir ( $p > 0,05$ ). **Sonuç:** Test edilen tüm diş macunları güvenli ve anlamlı derecede etkili

klinik ve mikrobiyolojik özellikler göstermiştir.

**Anahtar Kelimeler:** Çocuk, florür, diş macunu, mutans streptokok, tükürük.

### REFERENCES

1. Socransky SS, Haffajee AD. Periodontal microbial ecology. Periodontol 2000 2005;38:135-187.
2. Tanzer JM, Livingston J, Thompson AM. The microbiology of primary dental caries in humans. J Dent Educ 2001;65:1028-1037.
3. Al-Ghamdi F, Jari N, Al-Yafi D, Redwan S, Gogandy B, Othman H. Toothbrushing behavior and its prevalence versus Miswak usage among the dental students of the faculty of dentistry at King Abdulaziz University. Int Dent J Stud Res 2015;2:49-56.
4. Barnes VM, Richter R, DeVizio W. Comparison of the short-term antiplaque/antibacterial efficacy of two commercial dentifrices. J Clin Dent 2010;21:101-104.
5. Lima CV, Cury JA, Vale GC, Lima MD, Moura LFAD, Moura MS. Total Fluoride Intake by Children from a Tropical Brazilian City. Caries Res 2015;49:640-646.
6. Ellepola AN, Khan ZU, Chandy R, Philip L. A comparison of the antifungal activity of herbal toothpastes against other brands of toothpastes on clinical isolates of Candida albicans and Candida dubliniensis. Med Prin Pract 2011;20:112-117.
7. Yigit N, Aktas E, Ayyildiz A. Antifungal activity of toothpastes against oral Candida isolates. J Mycol Med 2008;18:141-146.
8. Almas AK, Almas K. Miswak (Salvadora Persica chewing stick) and its role in oral health: an update. J Pak Dent Assoc 2013;22:255-264.
9. Twetman S. Treatment protocols: nonfluoride management of the caries disease process and available diagnostics. Dent Clin North Am. 2010; 54:527-540.
10. Wong MCM, Clarkson J, Glenny AM, Lo ECM, Marinho VCC, Tsang BWK, Walsh T, Worthington HV. Cochrane reviews on the benefits/risks of fluoride toothpastes. J Dent Res 2011;90:573-579.
11. Patil S, Venkataraghavan K, Anantharaj A, Patil SH. Comparison of two commercially available toothpastes on the salivary Streptococcus Mutans count in urban preschool children: An *in vivo* study. Int Dent SA 2010;12:72-82.
12. Walsh T, Worthington HV, Glenny AM, Marinho VC, Jerončić A. Fluoride toothpastes of different concentrations for preventing dental caries in children

and adolescents. *Cochrane Database Syst Rev* 2010;20:CD007868.

13. Basch CH, Hammond R, Guinta A, Rajan S, Basch CE. Advertising of Toothpaste in Parenting Magazines. *J Community Health* 2013;38:911–914.

14. Prasad KV, Sohani R, Tikare S, Yelamalli M, Rajesh G, Javali SB. Anti-plaque efficacy of two commercially available dentifrices. *J Indian Assoc Public Health Dent* 2009;1:12-17.

15. Flisfisch S, Meyer J, Meurman JH, Waltimo T. Effects of fluorides on *Candida albicans*. *Oral Dis* 2008;14:296-301.

16. Do LG, Spencer AJ: Risk-benefit balance in the use of fluoride among young children. *J Dent Res* 2007;86:723–728.

17. Mustafa M, AlJeaidi Z, Al Aajam WH, Dafaalla Mohammed KA. Study of Caries Prevalence among Miswak and Non-Miswak Users: A Prospective Study. *J Contemp Dent Pract* 2016;17:926-929.

18. Guidelines on the use of fluoride in children: EAPD policy document. *Eur Arch Dent* 2009;10:129-135.

19. Lobo PL, de Carvalho CB, Fonseca SG, de Castro RS, Monteiro AJ, Fonteles MC, Fonteles CS. Sodium fluoride and chlorhexidine effect in the inhibition of mutans streptococci in children with dental caries: a randomized, double-blind clinical trial. *Oral Microbiol Immunol* 2008;23:486-491.

20. Lynch RJM, Navada R, Walia R. Low-levels of fluoride in plaque and saliva and their effect on the demineralisation and remineralisation of enamel; role of fluoride toothpastes. *Int Dent J* 2004;54:304-309.

21. Pandit S, Kim JE, Jung KH, Chang KW, Jeon JG. Effect of sodium fluoride on the virulence factors and composition of *Streptococcus Mutans* biofilms. *Arch Oral Biol* 2011;56:643-649.

22. Schulz KF, Altman DG, Moher D. CONSORT 2010 Statement: updated guidelines for reporting parallel group randomised trials. *BMC Med* 2010;24:8-18.

23. Ericsson Y. Clinical investigations of the salivary buffering action. *Acta Odontol Scand* 1959;17:131-165.

24. Dumas ER, Engelman EE, Venell JA. *In-vitro* antibacterial comparison of dentifrices claiming antigingivitis and gum-healing properties. *Oral Health Prev Dent* 2007;12:243-246.

25. American Academy of Paediatric Dentistry: Guideline on fluoride therapy. 2018;40:250-253.

26. Santos APP, Nadanovsky P, Oliveira BH. A systematic review and meta-analysis of the effects of fluoride toothpaste on the prevention of dental caries in the primary dentition of preschool children. *Community Dent Oral Epidemiol* 2013;41:1-12.

27. Patil PS, Pujar P, Subbareddy VV. Effect of different oral hygiene measures on oral malodor in children aged 7-15 years. *J Indian Soc Pedod Prev Dent* 2015;33:218-222.

28. Cagetti MG, Strohmer L, Basile V, Abati S, Mastroberardino S, Campus G. Effect of a toothpaste containing triclosan, cetylpyridinium chloride, and essential oils on gingival status in schoolchildren: A randomized clinical pilot study. *Quintessence Int* 2015;46:437-445.

29. Magnusson K, Petersson LG, Birkhed D. Effect of dentifrices with antimicrobial agents on mutans streptococci in saliva and approximal dental plaque in orthodontic patients. *Oral Health Prev Dent* 2007;5:223-227.

30. Carvalho FG, Negrini Tde C, Sacramento LV, Hebling J, Spolidorio DM, Duque C. The *in-vitro* antimicrobial activity of natural infant fluoride-free toothpastes on oral micro-organisms. *J Dent Child (Chic)* 2011;78:3-8.

31. Malhotra R, Singla S, Shashikiran ND. Comparison of antimicrobial activity of child formula dentifrices at different concentrations: An *in-vitro* study. *Int J Clin Paediatr Dent* 2017;10:131-135

32. Randall JP, Seow WK, Walsh LJ. Antibacterial activity of fluoride compounds and herbal toothpastes on *Streptococcus mutans*; an *in-vitro* study. *Aust Dent J* 2015;60:368- 374.

33. Andruskeviciene V, Milciuviene S, Bendoraitiene E, Saldunaite K, Vasiliauskiene I, Slabsinskiene E et al. Oral health status and effectiveness of caries prevention programme in kindergartens in Kaunas city (Lithuania). *Oral Health Prev Dent* 2008;6:343–348.

34. Whittle JG, Whitehead HF, Bishop CM. A randomised control trial of oral health education provided by a health visitor to parents of pre-school children. *Community Dent Health* 2008;25:28–32.

35. Fan X, Li X, Wan H, Hu D, Zhang YP, Volpe AR et al. Clinical investigation of the anticaries efficacy of a 1.14% sodium monofluorophosphate (smfp) calcium carbonate-based dentifrice: a two-year caries clinical

trial on children in China. *J Clin Dent* 2008;19:134–137.

**36.** Jackson RJ, Newman HN, Smart GJ, Stokes E, Hogan JJ, Brown C et al. The effects of a supervised toothbrushing programme on the caries increment of primary school children, initially aged 5–6 years. *Caries Res* 2005;39:108–115.

**37.** Rong WS, Bian JY, Wang WJ, Wang JD. Effectiveness of an oral health education and caries prevention program in kindergartens in China. *Community Dent Oral Epidemiol* 2003;31:412–416.

**38.** Schwarz E, Lo EC, Wong MC. Prevention of early childhood caries – results of a fluoride toothpaste

demonstration trial on chinese preschool children after three years. *J Public Health Dent* 1998;58:12–18.

**39.** You BJ, Jian WW, Sheng RW, Jun Q, Wa WC, Bartizek RD et al. Caries prevention in Chinese children with sodium fluoride dentifrice delivered through a kindergarten-based oral health program in China. *J Clin Dent* 2002;13:179–184.

**40.** Davies GM, Worthington HV, Ellwood RP, Bentley EM, Blinkhorn AS, Taylor GO et al. A randomised controlled trial of the effectiveness of providing free fluoride toothpaste from the age of 12 months on reducing caries in 5–6 year old children. *Community Dent Health* 2002;19:131–136.



## RADIOGRAPHIC FEATURES AND TREATMENT STRATEGIES OF IMPACTED MAXILLARY CANINES

### ABSTRACT





**Objective:** Treatment of impacted maxillary canines is essential, both aesthetically and functionally. This study aims to define the radiographic features of maxillary impacted canines, evaluate treatment options, and to detect related pathologies.

**Materials and Methods:** In this retrospective study, orthopantomographs, treatment options, and demographic features of the patients were analyzed. Impacted maxillary canines were classified according to the study of Yamamoto *et al.* According to this classification, maxillary canines are evaluated under seven types according to the occlusal plane and their relative location to adjacent teeth. Moreover, the pathologies around impacted canines were detected via panoramic radiographies.

**Results:** 323 impacted maxillary canines of 270 patients were analyzed. Two hundred fifteen of these teeth (66.6%) belonged to females, while the rest 108 (33.4%) belonged to males. It was observed that impacted maxillary canines were bilateral in 53 patients and unilateral in 217 patients. In the classification based on direction and position of impacted maxillary canines, the highest rates was Type 2 (55.42%) which was followed by Type 4 (26.93%), Type 1 (12.38%), Type 7 (2.79%), Type 3 (1.86%) and Type 5 (0.62%), respectively. Twenty-eight patients with cystic lesion related to impacted maxillary canines were detected. Impacted maxillary canines concomitant with odontoma was detected in 4 patients. In 52 of the patients, it was detected that maxilla was edentulous except for the impacted canines, and the extractions of impacted canine teeth were due to prosthetic reasons. Thirty impacted maxillary canines of 24 patients (n=30, 9.28%) were placed buttons for orthodontic maintenance, while surgical tooth extraction was preferred as a treatment option in other patients.

**Conclusions:** Orthodontic, surgical treatments or combinations may be preferred depending on the impact level of the canine. Early diagnosis and correct orientation of the patient is essential for the success of the treatment.

**Keywords:** Impacted, maxilla, tooth, tooth extraction.

 \*Ahmet ALTAN<sup>1</sup>  
 Sefa ÇOLAK<sup>1</sup>  
 Nihat AKBULUT<sup>1</sup>  
 Halenur ALTAN<sup>2</sup>

ORCID IDs of the authors:

A.A. 0000-0003-2041-6364

S.Ç. 0000-0002-0807-9089

N.A. 0000-0001-6950-8214

H.A. 0000-0003-3648-5989

<sup>1</sup> Tokat Gaziosmanpaşa University Faculty of Dentistry, Department of Oral and Maxillofacial Surgery, Tokat, Turkey.

<sup>2</sup> Tokat Gaziosmanpaşa University Faculty of Dentistry, Department of Pediatric Dentistry, Tokat, Turkey.

Received : 09.12.2019

Accepted : 15.01.2020



## INTRODUCTION

Description of impacted teeth comprises teeth that could not take its place on dental arch and impacted partially or wholly in bone or soft tissue.<sup>1</sup> Despite the differences observed among people, third molar teeth are the most impacted teeth in general, and they are followed by canine teeth.<sup>2-4</sup> The impact incidence of maxillary canines varies between 0.8% and 3.6%.<sup>5</sup> Impact incidence of mandibular canines is more rare than maxillary canines and it was reported that this incidence is 20 times lower than of maxillary canines.<sup>6</sup>

Despite some cases where an impacted tooth migrates from its development area to another distance, the tooth stays on the same side of the middle line in general. The rare phenomena in which the tooth passes the middle line is called as "tooth transmigration". Although various terminologies have been used to define this case, the "transmigration" term is widely used to define this phenomenon. Transmigration is more widely observed in mandibular canines than in maxillary canines.<sup>7</sup> Specific etiology of this anomaly has not been known yet; however, causal factors may be traumatic factors, genetic factors, long eruption line of canines, the early loss of deciduous teeth, incompatibility between tooth sizes, inadequate length of dental arch and odontomas.<sup>8,9</sup>

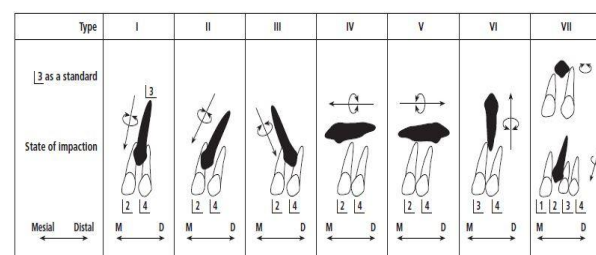
Treatment of impacted teeth is essential, both aesthetically and functionally.<sup>10</sup> Among the treatment options for impacted canines, surgical, and orthodontic treatment options may be evaluated separately or as a combination. In the surgical option, the spontaneous eruption of the tooth may be planned by opening the eruption line. Spontaneous eruption of the tooth may be provided by removing the odontoma or similar pathologies lying on the eruption line. The impacted tooth may be drawn to the dental arch by placing a button on the crown of an impacted tooth and applying orthodontic force. In cases where orthodontic treatment cannot be applied, tooth extraction is evaluated as a general treatment option.<sup>11</sup> In cases where the impacted canines cannot be treated, some phenomena as transmigration between adjacent teeth, loss of

vitality in adjacent teeth, contraction in dental arch, cystic pathologies based on dental follicles, ankylosis, internal and external resorption, recurrent infections, pain and combination of these may be observed.<sup>12,13</sup>

This study aims to define the radiographic features of maxillary impacted canines, evaluate treatment options, and detecting related pathologies.

## MATERIAL AND METHODS

Ethical committee approval was obtained from Ethical Committee of Clinical Researches of Tokat Gaziosmanpaşa University (Project no: 18-KAEK-285). In this retrospective study, orthopantomographs, treatment options, and demographic features of the 270 patients who had admitted to the Department of Oral and Maxillofacial Surgery, Faculty of Dentistry in Tokat Gaziosmanpaşa University due to impacted maxillary canine between March 2013 and January 2019 were analyzed. The study includes the patients above 13 years of age who had no developmental or systemic diseases and whose impacted maxillary canine was placed an extraction indication or who underwent a button application for orthodontic treatment after clinical and radiologic treatment in Department of Oral and Maxillofacial Surgery. The patients who have a genetic disorder causing developmental and eruption problems in the development and eruption of teeth and whose demographic features could not be accessed were excluded from the study. Impacted maxillary canines were classified according to the study of Yamamoto *et al.*<sup>14</sup> According to this classification, maxillary canines are evaluated under seven types according to the occlusal plane and their relative location to adjacent teeth (Figure 1).



**Figure 1.** According to Yamamoto *et al.*<sup>14</sup> classification of impacted maxillary canines

Moreover, the pathologies around impacted canines were detected via panoramic radiographies.

SPSS 19 (IBM SPSS Statistics 19, SPSS inc., an IBM Co., Somers, NY) program was used in the statistical analysis of study data. Variables were recorded and analyzed by descriptive statistics.

**RESULTS**

In this study, 323 impacted maxillary canines of 270 patients (173 females and 97 males) were analyzed. Two hundred fifteen of these teeth (66.6%) belonged to females, while the rest 108

(33.4%) belonged to males. The age of the patients varied between 13-77 (average: 38.74 ± 18.12). It was observed that impacted maxillary canines were bilateral in 53 patients (42 female, 11 male) and unilateral in 217 patients. In the classification based on direction and position of impacted maxillary canines, the highest rates was Type 2 (55.42%) which was followed by Type 4 (26.93%), Type 1 (12.38%), Type 7 (2.79%), Type 3 (1.86%) and Type 5 (0.62%) respectively. There were no cases classified in Type 6. Impacted maxillary canines were mostly localized at left side (n=171, % 52.94) (Table-1).

**Table1.** Distribution of impacted maxillary canines by gender and the type of impaction.

Type	Localization		Gender		n	Total %
	Right (#13)	Left (#23)	Female	Male		
Type 1	25	15	28	12	40	12.38
Type 2	83	96	118	61	179	55.42
Type 3	4	2	5	1	6	1.86
Type 4	36	51	56	31	87	26.93
Type 5	0	2	2	0	2	0.62
Type 6	0	0	0	0	0	0
Type 7	4	5	6	3	9	2.79
<b>Total</b>	152 (47.06 %)	171 (52.94%)	215 (66.56%)	108 (33.44%)	323	100

The age distribution of patients showed that a significant number of patients with impacted

maxillary canines are between 13-20 of ages (Table-2).

**Table 2.** Age distribution of patients with impacted maxillary canines.

Age (years)	Number of impacted teeth	
	n	%
13-20	94	29.1
21-30	45	13.93
31-40	33	10.22
41-50	45	13.93
51-60	63	19.51
>60	43	13.31
<b>Total</b>	323	100

Twenty-eight patients (10.4%) with cystic lesion related to impacted maxillary canines were detected (Figure-2). Impacted maxillary canines concomitant with odontoma was detected in 4 patients (1.5%) (Figure-3). In 52 of the patients (19.3%), it was

detected that maxilla was edentulous except for the impacted canines, and the extractions of impacted canine teeth were due to prosthetic reasons. Thirty impacted maxillary canines of 24 patients (n=30, 9.28%) were placed buttons for orthodontic

maintenance, while surgical tooth extraction was preferred as a treatment option in other patients.

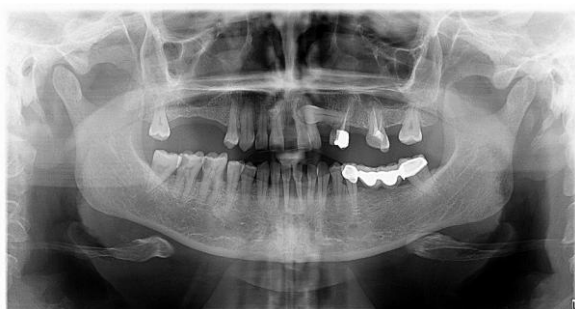

Figure 2. Impacted canine tooth associated with cystic lesion

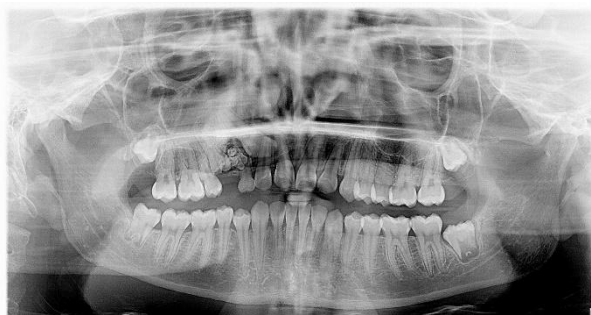

Figure 3. Impacted canine tooth associated with odontoma

## DISCUSSION

Maxillary canines play an important role in both aesthetically and functionally. Although the bilateral impact of maxillary canine is a frequent phenomenon, unilateral ectopic eruptions are more frequent.<sup>14,15</sup> In this study, the unilateral impact was more frequently observed. When the localization of impacted maxillary canines are analyzed, it is observed that the impacted maxillary canines are frequently located on the left side.<sup>1,16</sup> Despite the lack of any scientific evidence to show the high prevalence of left-sided impacted maxillary canines, it has been accepted as a general malformation. In this study, too, the left-sided impacted maxillary canine was more frequently observed.

Yamamoto *et al.*<sup>14</sup> were reported that impacted canines were more frequently observed in females. Similarly, in this study, 215 of 270 impacted canines were observed in females. Despite the lack of any literature about jawbone sizes of people with an impacted tooth, we believe that gender differences as the fact that females have smaller cranium, maxilla, and mandible than of males, may have an effect on this situation. Al-Zoubiet *al*<sup>1</sup> reported that Type 2 was more frequent among other types of impacted maxillary

canines. However, in the study of Yamamoto *et al.*<sup>14</sup>, Type 1 of impact is more frequent. In this study, Type 2 was the most frequently observed type of impact.

Patients are generally not aware of their impacted canines. They do not consult dentists unless they have problems like pain or swelling. The impacted tooth or persistent deciduous tooth is generally explored during the examination and confirmed via radiographies. Clinical examination includes inspection and palpation.<sup>17</sup> From the age of 8 years, the alveolar process on the distal side of the lateral incisor can palpate the buccal surface and open the position of the maxillary canine teeth, and this was offered as a diagnostic tool by Kettle.<sup>18</sup> Radiographic evaluation of jaws is an important diagnostic tool in the diagnosis and localization of impacted teeth. A radiograph is required for 3D (vertical, mesiodistal, and buccopalatal) imaging of the impacted canines, observing the relations with the middle line and neighboring teeth, and evaluating any resorption.<sup>19</sup> In the evaluation of impacted canine; Panoramic, periapical, cephalometric, lateral skull and maxillary occlusal, CT, and CBCT are widely used.<sup>17</sup> CBCT is the most sensitive radiographic localization method, which maximizes diagnostic efficiency and reduces radiation exposure. Total radiation is about 20% of conventional CTs.<sup>20,21</sup> CBCT eliminates problems such as magnification and superimposition in conventional radiographs. In orthodontics and pedodontics, underestimating the degree of resorption in maxillary canine is a common problem. CBCT increases resorption detection by 50%.<sup>22</sup> For these reasons, the use of three-dimensional imaging methods for the maxillofacial region has become more common than traditional radiographs.<sup>23</sup>

The demands of the patient should also be taken into account while deciding on treatment. Long-term follow of a tooth, extraction of the tooth, re-drawn of the tooth to its position on the dental arch by orthodontic movement, autotransplantation of the tooth, simultaneous dental implant placement after the extraction of the impacted tooth may be evaluated as treatment options for impacted canines.<sup>24,25</sup> Cyst formation

between possible sequels of impacted canines, internal resorption of an impacted tooth, external resorption of impacted or adjacent teeth, ankylosis, infection, and migration of neighboring teeth may also be included.<sup>26</sup> For this study, the surgical extraction reasons for impacted teeth may be evaluated as pathological formations as cyst and tumor-related to the impacted tooth, malposition of especially lateral teeth, and prosthetic reasons in edentulous patients.

Besides traditional surgical applications, Bensaha *et al.*<sup>27</sup> also suppose ultrasonic surgery for the treatment of impacted canines. The main advantages of ultrasonic surgery are facing no bleeding or no tissue necrosis and the chance of placing the brackets during the same visit. Baccetti *et al.*<sup>28</sup> suggest transpalatal arch therapy to be used as a treatment for impacted maxillary canine teeth. This option helps to control the movement of maxillary first molar teeth. Thus, the location of permanent maxillary canines is preserved, and spontaneous eruption can be induced. Moreover, mini-screws can be used when extrusion of impacted maxillary canine teeth is needed. Roth *et al.*<sup>29</sup> successfully performed a case where the maxillary canine was extruded via a mini-screw.

## CONCLUSIONS

Impacted maxillary canine teeth are usually diagnosed using panoramic imaging or cone-beam computed tomography. Cone-beam computed tomography is one of the most accurate diagnostic methods to identify the localization of affected maxillary canines. Orthodontic, surgical treatments or combinations may be preferred depending on the impact level of the canine. Early diagnosis and correct orientation of the patient is important for the success of the treatment.

### *Gömülü Maksillar Kanin Dişlerin Radyografik Özellikleri ve Tedavi Stratejileri*

#### ÖZ

**Amaç:** Gömülü kanin dişlerinin tedavisi estetik ve fonksiyon açısından önem taşımaktadır. Bu çalışmanın amacı; maksillar gömülü kanin dişlerin, radyografik özelliklerini belirlemek, tedavi seçeneklerini değerlendirmek ve ilgili patolojileri tespit etmektir. **Gereç ve Yöntem:** Bu retrospektif çalışmada, hastaların ortopantomograf radyografileri, tedavi seçenekleri ve

demografik özellikleri analiz edildi. Gömülü maksillar kaninler; Yamamoto ve arkadaşları tarafından yapılan sınıflamaya göre gruplara ayrıldı. Bu sınıflamaya göre maksillar kaninler oklüzal düzleme ve komşu dişlere konumlarına göre 7 tipe ayrılmıştır. Ayrıca; panoramik radyografilerden gömülü kanin dişler etrafındaki patolojiler tespit edildi. **Bulgular:** Çalışmada, 270 hastaya (173 kadın, 97 erkek) ait 323 gömülü maksillar kanin diş analiz edildi. Bu dişlerin 215'i (%66,6) kadınlarda, 108'si (%33,4) erkeklerde görüldü. Maksillar gömülü kanin dişler 53 hastada (42 kadın, 11 erkek) bilateral, 217 hastada unilateral olarak tespit edildi. Maksillar kaninlerin yönü ve pozisyonuna göre yapılan sınıflamada en yüksek oran Tip 2 (%55,42)'de onu takiben sırasıyla, Tip 4 (%26,93), Tip 1 (%12,38), Tip 7 (%2,79), Tip 3 (%1,86), Tip 5 (%0,62) idi. 28 hastada gömülü maksillar kanin dişlerle ilişkili kistik lezyon tespit edildi. 4 hastada ise gömülü maksillar kanin dişe odontoma eşlik ediyordu. Hastaların 52'sinde gömülü kanin dişler haricinde maksillanın total dişsiz olduğu ve protetik amaçlarla çekim gerçekleştirildiği belirlendi. 24 hastada 30 gömülü maksillar kanin dişe ortodontik olarak sürdürülme amacıyla buton yerleştirildi, diğer hastalarda ise tercih edilen tedavi yöntemi cerrahi çekimdi. **Sonuçlar:** Kanin dişin gömülülük derecesine bağlı olarak; tedavide ortodontik, cerrahi ya da kombinasyonları tercih edilebilir. Tedavinin başarısında erken tanı ve hastanın doğru yönlendirilmesi önemlidir. **Anahtar Kelimeler:** Gömülü, maksilla, diş, diş çekimi.

## REFERENCES

1. Al-Zoubi H, Alharbi AA, Ferguson DJ, Zafar MS. Frequency of impacted teeth and categorization of impacted canines: A retrospective radiographic study using orthopantomograms. *Eur J Dent* 2017;11:117-121.
2. Pedro FL, Bandeca MC, Volpato LE, Marques AT, Borba AM, Muis CR, et al. Prevalence of impacted teeth in a Brazilian subpopulation. *J Contemp Dent Pract* 2014;15:209-213.
3. Damlar İ, Altan A, Tatlı U, Arpağ OF. Retrospective Investigation of the Prevalence of Impacted Teeth in Hatay. *Cukurova Medical Journal* 2014;39:559-565.
4. Uğur Aydın Z, Korkmaz YN, Sarioğlu B. Radiographic Investigation of The Relationship

Between Dental Malocclusions And Dental Anomalies on the Turkish Population. *Cumhuriyet DentJ* 2018;21:343-349.

5. Aydin U, Yilmaz HH, Yildirim D. Incidence of canine impaction and transmigration in a patient population. *Dentomaxillofac Radiol* 2004;33:164-169.

6. Bhullar MK, Aggarwal I, Verma R, Uppal AS. Mandibular Canine Transmigration: Report of Three Cases and Literature Review. *J Int Soc Prev Community Dent* 2017;7:8-14.

7. Joshi MR. Transmigrant mandibular canines: a record of 28 cases and a retrospective review of the literature. *Angle Orthod* 2001;71:12-22.

8. Sumer P, Sumer M, Ozden B, Otan F. Transmigration of mandibular canines: a report of six cases and a review of the literature. *J Contemp Dent Pract* 2007;8:104-110.

9. Celikoglu M, Kamak H, Oktay H. Investigation of transmigrated and impacted maxillary and mandibular canine teeth in an orthodontic patient population. *J Oral Maxillofac Surg* 2010;68:1001-1006.

10. Alhammadi MS, Asiri HA, Almashraqi AA. Incidence, severity and orthodontic treatment difficulty index of impacted canines in Saudi population. *J Clin Exp Dent* 2018;10:e327-e334.

11. Becker A, Chaushu S. Surgical Treatment of Impacted Canines: What the Orthodontist Would Like the Surgeon to Know. *Oral Maxillofac Surg Clin North Am* 2015;27:449-458.

12. Bonardi JP, Gomes-Ferreira PH, de Freitas Silva L, Momesso GA, de Oliveira D, Ferreira S, et al. Large Dentigerous Cyst Associated to Maxillary Canine. *J Craniofac Surg* 2017;28:e96-e97.

13. Guarnieri R, Cavallini C, Vernucci R, Vichi M, Leonardi R, Barbato E. Impacted maxillary canines and root resorption of adjacent teeth: A retrospective observational study. *Med Oral Patol Oral Cir Bucal* 2016;21:e743-e750.

14. Yamamoto G, Ohta Y, Tsuda Y, Tanaka A, Nishikawa M, Inoda H. A new classification of impacted canines and second premolars using orthopantomography. *Asian Journal of Oral and Maxillofacial Surgery* 2003;15:31-37.

15. Thilander B, Myrberg N. The prevalence of malocclusion in Swedish schoolchildren. *Scand J Dent Res* 1973;81:12-21.

16. Takahama Y, Aiyama Y. Maxillary canine impaction as a possible microform of cleft lip and

palate. *Eur J Orthod* 1982;4:275-277.

17. Counihan K, Al-Awadhi EA, Butler J. Guidelines for the assessment of the impacted maxillary canine. *Dent Update* 2013;40:770-777.

18. Kettle MA. Treatment of the unerupted maxillary canine. *Trans Br Soc Orthod* 1957;74-78.

19. Stivaros N, Mandall NA. Radiographic factors affecting the management of impacted upper permanent canines. *J Orthod* 2000;27:169-173.

20. Preda L, La Fianza A, Di Maggio EM, Dore R, Schifino MR, Campani R, et al. The use of spiral computed tomography in the localization of impacted maxillary canines. *Dentomaxillofac Radiol* 1997;26:236-241.

21. Mah JK, Danforth RA, Bumann A, Hatcher D. Radiation absorbed in maxillofacial imaging with a new dental computed tomography device. *Oral Surg Oral Med Oral Pathol Oral Radiol Endod* 2003;96:508-513.

22. Ericson S, Kurol PJ. Resorption of incisors after ectopic eruption of maxillary canines: a CT study. *Angle Orthod* 2000;70:415-423.

23. Bayrak S, Sezgin OS, Kayıpmaz, Çan G. The Effect of Slice Thickness on the Volume Estimations Performed by Using Cone Beam CT. *Cumhuriyet Dent J* 2018;21:167-172.

24. Sajnani AK, King NM. Retrospective audit of management techniques for treating impacted maxillary canines in children and adolescents over a 27-year period. *J Oral Maxillofac Surg* 2011;69:2494-2499.

25. Penarrocha M, Penarrocha M, Garcia-Mira B, Larrazabal C. Extraction of impacted maxillary canines with simultaneous implant placement. *J Oral Maxillofac Surg* 2007;65:2336-2339.

26. Bishara SE. Impacted maxillary canines: a review. *Am J Orthod Dentofacial Orthop* 1992;101:159-171.

27. Bensaha T. A new approach for the surgical exposure of impacted canines by ultrasonic surgery through soft tissue. *Int J Oral Maxillofac Surg* 2013;42:1557-1561.

28. Baccetti T, Sigler LM, McNamara JA, Jr. An RCT on treatment of palatally displaced canines with RME and/or a transpalatal arch. *Eur J Orthod* 2011;33:601-607.

29. Roth A, Yildirim M, Diedrich P. Forced eruption with microscrew anchorage for preprosthetic leveling of the gingival margin. Case report. *J Orofac Orthop* 2004;65:513-519.



## COMPARISON OF ORAL HEALTH STATUS AND BEHAVIORS BETWEEN CHILDREN WITH AUTISTIC SPECTRUM DISORDER AND HEALTHY CHILDREN IN RASHT CITY, IRAN

### ABSTRACT

**Objectives:** In this study, the caries experience, gingivitis and behaviors of 6-12 year old children with Autistic Spectrum Disorder (ASD) were investigated according to the Frankl scale during dental examination, and then compared with healthy children.

**Materials and Methods:** Totally, 55 children with ASD (including 49 males and 6 females) and 165 healthy children (including 83 males and 82 females) were assessed in Rasht, Iran. Before clinical examination, their parents were asked to complete a questionnaire consisting of several questions about parental education level, nutritional status and oral hygiene status. The number of decayed, missing and filled teeth, gingival status and behaviors of the children were recorded during the dental examination. The obtained data were analyzed using Chi-square and Mann Whitney U Test. P-value less than 0.05 was considered statistically significant.

**Results:** Our results implied that the children with ASD had higher DMFT/dmft scores compared with healthy children ( $p < 0.001$ ). Also, the prevalence of localized and generalized gingivitis was higher in children with ASD than that in healthy children ( $p = 0.014$ ). Most of the children with ASD behaved in negative or definitely negative manner during dental examination ( $p = 0.001$ ). The results showed that the mean level of parental education and oral hygiene habits (such as frequency of brushing and flossing) in healthy children were higher than that in the children with ASD.

**Conclusions:** According to the results, the children with ASD had higher caries experience and gingivitis compared with healthy children and most of them behaved in negative or definitely negative manner during dental examination.

**Keywords:** Autistic disorder, dental caries, gingivitis, child.

 Seyedeh Hadiyah DANESHVAR<sup>1</sup>  
 Alaleh KAVIANFAR<sup>2</sup>  
 Seyed Hossein MASOOMI<sup>3</sup>  
 Mir Mahdi DANESHVAR<sup>4</sup>

ORCID IDs of the authors:

S.H.D. 0000.0002-5002-2350

A.K. 0000-0002-1294-4813

S.H.M. 0000-0002-3981-5114

M.M.D. 0000-0003-4213-3867

<sup>1</sup> Dental Sciences Research Center, Department of Pediatric Dentistry, School of Dentistry, Guilan University of Medical Sciences, Rasht, Iran

<sup>2</sup> School of Dentistry, Guilan University of Medical Sciences, Rasht, Iran

<sup>3</sup> Student Research Committee, Dental Research Center, School of Dentistry, Guilan University of Medical Sciences, Rasht, Iran

<sup>4</sup> Postgraduate Student, Department of Prosthodontics Dentistry, School of Dentistry, Guilan University of Medical Sciences, Rasht, Iran.

Received : 25.10.2019

Accepted : 15.01.2020

## **INTRODUCTION**

Autism Spectrum Disorder (ASD) as a neurodevelopment disorder is characterized by repetitive patterns of behaviors and major impairment in social communication. ASD was first described in 1943 by Leo Kanner. This disorder is classified into five subtypes: (a) autism disorder, (b) asperger's syndrome, (c) rett's disorder, (d) childhood disintegrative disorder and (e) pervasive developmental disorder.<sup>1</sup> ASD as a common disorder has a population prevalence of 6 cases in 1000 children. This disorder is considered as an important cause of morbidity and mortality worldwide.<sup>2</sup> Regardless of the age of the children, ASD interventions should improve all difficulties and challenges in relation to this disorder such as gastrointestinal disturbances, attention deficit hyperactivity disorder (ADHD), learning disability, anxiety and depression, sleep disturbances, sensory sensitivity and motor difficulties.<sup>3</sup> It has been well known that ASD is a multifactorial psychiatric condition and a combination of three developmental, environmental and genetic factors is introduced as the etiology of this disorder.<sup>4</sup> Boys are 3.7 times more likely to be autistic than girls.<sup>5</sup> Early signs of autism appear in infants as young as 6 months. The signs of this disorder are then stabilized by age 2-3 years, and then tend to continue through adulthood. It has been reported that there are certain problems and obstacles preventing autistic patients from receiving adequate professional dental care, and in most cases the dental needs of these children are ignored. Previous studies have reported controversial outcomes on prevalence of dental caries in children with ASD compared with healthy children.<sup>6-9</sup> Some literatures<sup>4,6,10</sup> have reported that the prevalence of dental caries and periodontal problems in children with ASD is higher than that in healthy children due to the lack of ability to learn and perform oral hygiene habits such as brushing and flossing. By contrast, some other studies<sup>11-13</sup> have showed a lower dental caries in children with ASD due to good supervision of their parents regarding tooth brushing. Therefore, the results of these studies are not comparable and conclusive about oral health status of children with ASD. Hence, the

present study aimed to evaluate oral health status and behaviors of children with ASD during dental examination and to compare them with healthy children in Rasht, Iran.

## **MATERIALS AND METHODS**

In this cross-sectional case control study, 55 children with ASD (49 males and 6 females) were selected from autism rehabilitation center of Rasht city as the case group. Also, 165 healthy children (83 males and 82 females) were selected from children referred to the Dentistry faculty of Guilan University of Medical Science, Rasht, Iran, as the control group. Inclusion criteria were an age in the range 6–12 years old and having a diagnosis of ASD for the case group. Exclusion criteria included poor cooperation, having other disorders and parental dissatisfaction. Ethical approval (IR.GUMS.REC.1397.333) for this study was obtained from ethics committee of the Guilan University of Medical Sciences and Autism Rehabilitation Center prior to oral examination. In the both case and control groups, their parents were informed about the procedure and objectives and the informed written consent was obtained.

The parents were asked to complete a questionnaire containing questions about parental education level, nutritional status and oral hygiene status of the children. The severity of ASD was categorized into three levels including mild, moderate and severe based on the impairments in communication, social interaction and repetitive behaviors by a physician<sup>1</sup>. The oral examinations of the children were performed by pediatric dentist using Tell-Show-Do technique. The oral examinations were conducted using a dental mirror and explorer under natural light. The dentist recorded all decayed teeth (D/d), missing teeth (M/m) (due to caries) and all filled teeth (F/f) (including primary and permanent teeth) in accordance with WHO guidelines (1997).<sup>14</sup>

Gingival status was recorded as generalized or localized gingival inflammation depending on the amount of gingival redness and bleeding during the examination according to the gingival index of Loe and Silness.<sup>15</sup> During dental examination, behavioral status of patients was also evaluated based on Frankl scale.<sup>16</sup> Bruxism was recorded

based on the observation of wear facets as an indication of enamel and dentin attrition.<sup>17</sup> During the examination, their parents/trainers were present to make them feel more comfortable and informed about the dental treatment needs of their children.

### Statistical Analysis

Statistical analysis was carried out using SPSS software (version 21). Descriptive statistics were reported as mean  $\pm$  standard deviation for quantitative variables. The frequencies and percentages were used for qualitative variables. Chi-square statistic test was used to analyze the data obtained regarding the children's ages, oral habits, Frankl's behavior scale score, bruxism and

gingivitis. Mann-Whitney U test was also applied to compare the caries experience between the two case and control groups. A statistically significant level was considered at  $p < 0.05$ .

### RESULTS

In the present study, 55 autistic and 165 healthy children were selected as the case and control groups, respectively. The mean age of the children in the study and control groups were  $9.32 \pm 2.33$  and  $8.71 \pm 1.97$ , respectively. There was no significant difference between the two means ( $p=0.085$ ). 89.1% of participants in the case group and 50.3% of them in the control group were male. (Table 1)

**Table 1.** Demographic status, parental education level, nutrition status and oral hygiene habits of children with ASD and healthy children

Parameters		Children with ASD		Healthy children		P-value
		N	%	N	%	
<b>Gender</b>	Male	49	89.1	83	50.3	0.001
	Female	6	10.9	82	49.7	
<b>Age</b>	6-7 yr	19	34.5	73	44.2	0.360
	8-9 yrs	10	18.2	31	18.8	
	10 and above	26	47.3	61	37	
<b>Age (Mean <math>\pm</math>SD)</b>		9.32 $\pm$ 2.33		8.71 $\pm$ 1.97		0.085
<b>Dentition</b>	Primary	11	20	28	17	0.125
	Mixed	24	43.6	97	58.8	
	Permanent	20	36.4	40	24.2	
<b>Father's education</b>	Elementary	10	18.2	11	6.7	0.034
	High school	28	50.9	87	52.7	
	University degree	17	30.9	67	40.6	
<b>Mother's education</b>	Elementary	12	21.8	13	7.9	0.014
	High school	24	43.6	75	45.5	
	University degree	19	34.5	77	46.7	
<b>Frequency of sweet consumption</b>	Low	30	54.5	91	55.15	0.110
	Moderate	16	29.1	62	37.6	
	High	9	16.4	12	7.3	
<b>Dental floss use</b>	No	55	100	135	81.8	0.001
	Yes	0	0	30	18.2	
<b>Brushing frequency (per day)</b>	Does not brush	19	34.5	6	3.6	0.001
	Once	30	54.5	86	52.1	
	Twice or more	6	10.9	73	44.2	

The education level of the fathers ( $p=0.034$ ) and mothers ( $p=0.014$ ) in control group was significantly higher than that in the case group. There were no differences between the ASD and control groups in terms of frequency of sweet consumption ( $p=0.11$ ) (Table 1).

The results implied that in the ASD group, none of the children were using dental floss, while in the control group, 18.2% of participants were

using dental floss ( $p=0.001$ ). The rate of tooth brushing in the ASD group was significantly less than that in the control group ( $p=0.001$ ). These results are presented in Table 1.

The prevalence of gingivitis ( $p=0.014$ ) and bruxism ( $p=0.001$ ) in children with ASD was significantly higher than that in the healthy group (Table 2).



**Table 2.** Behavioral status during dental examination according to Frankl scale, gingival status and bruxism in children with ASD and healthy children.

Parameters	Children with ASD		Healthy children		P-Value	
	N	%	N	%		
Frankl scale	Negative	26	47.3	4	2.4	0.001
	Definitely negative	21	38.2	0	0	
	Positive	8	14.5	68	41.2	
	Definitely positive	0	0	93	56.4	
Bruxism	No	24	43.6	159	96.4	0.001
	Yes	31	56.4	6	3.6	
Gingivitis	Non	23	41.8	91	55.2	0.014
	localized	23	41.8	66	40	
	Generalized	9	16.4	8	4.8	

According to Frankl’s behavior rating scale, the healthy children were more likely to behave in positive or definitely positive manner during dental examination compared with the ASD group. There was a statistically significant

difference between the two groups (p=0.001) (Table 2).

As presented in Table 3, the children with ASD had higher DMFT/dmft scores compared with healthy children (p=<0.001).

**Table 3.** Comparison of number of decayed, missing and filled teeth between children with ASD and healthy children.

Parameters	Children with ASD		Healthy children		P-value
	Mean ± SD	median	Mean ± SD	Median	
DMFT+dmft	6.33±2.88	6	3.88±2.91	4	<0.001
Decayed teeth (D+d)	5.78±3.21	6	2.48±2.69	2	<0.001
Missing teeth (M+m)	0.11±0.42	0	0.13±0.44	1	<0.001
Filled teeth (F+f)	0.44±1.07	0	1.27±1.62	1	<0.001

In this regard, a statistically significant difference was observed in the mean numbers of decayed, missing and filled teeth between the case and control groups (p=<0.001). The results showed that the mean number of decayed teeth in children with ASD was higher than that of the healthy children, while the mean numbers of missing and filled teeth in the ASD group was lower than that in healthy children.

Our findings implied that there were no significant difference in caries experiences between children with ASD and healthy children. So that, no significant difference was observed in primary and mixed dentition between the two groups (p=0.06). The DMFT score in permanent dentition in children with ASD was significantly higher than that of healthy children (p=<0.001) (Table 4).

**Table 4.** Comparison of caries experiences in permanent, primary and mixed dentition in children with ASD and healthy children.

Parameters	Children with ASD		Healthy children		P-Value
	Mean±SD	Median	Mean±SD	Median	
Permanent dentition (DMFT)	6.20±2.75	6	2.7±2.6	2	<0.001
Primary dentition (dmft)	6.45±3.50	7	4.43±2.87	4	0.06
Mixed dentition (DMFT+dmft)	6.38±2.81	6	4.22±2.93	4	0.06

Table 5 presents the relationship between ASD severity and DMFT/dmft scores. As observed, the mean score of DMFT/dmft in the children with

severe ASD was higher than that in the children with mild and moderate ASD (P=0.007).

**Table 5.** Relationship between ASD severity and caries experiences (DMFT+dmft).

Disorder severity	N	DMFT+dmft		P-Value
		Mean±SD	Median	
Mild	17	5.59±2.74	6	0.007
Moderate	27	5.78±2.71	5	
Severe	9	8.78±2.05	8	

## DISCUSSION

ASD is a developmental disorder that can affect oral health status of people with this disorder. Most of previous studies have focused on the awareness of ASD. While few studies have investigated oral health status in children with ASD. This cross-sectional study assessed the dental caries experiences, behavioral and gingival status of 6-12 year old children with ASD in comparison with healthy children in Rasht city, Iran.

In the present study, M/F ratio was 8:1, which indicated that the boys are at a higher risk for having ASD. This finding is in agreement with all previous studies around the world.<sup>10,11</sup> The higher prevalence of this disorder among males suggests an x-linked disorder, involving up to 20 interacting genes. It is believed that children born with a genetic vulnerability to autism, are sensitive to external environmental factors. In this disorder, parental environmental factors include taking antidepressants during pregnancy, maternal viral infections and nutritional deficiency, especially folic acid deficiency. Some other factors have been also addressed such as extremely low birth weight and neonatal anemia.<sup>10,18,19</sup>

Children with ASD suffer from poor muscle coordination and tend to consume sweet and soft food. They are more likely to keep their food in oral cavity instead of swallowing due to oral motor deficiencies. These nutritional problems lead to increased risk of dental caries in these children. Drugs that are used by these children to control the symptoms of this disorder, can cause xerostomia and subsequently make the patient more susceptible to dental caries.<sup>5</sup> Some literatures reported that the prevalence of dental caries in children with ASD is higher than that in healthy children.<sup>4,6,10</sup>

Suhaib *et al.*<sup>4</sup> reported that the high rate of dental caries experience among ASD children is attributed to inability or irregular brushing habits. Some studies showed that children with ASD have lower prevalence of dental caries.<sup>11-13</sup> This finding can be attributed to the good oral health care supervision by their parents and using

carbohydrate-restricted diets. Sarnat *et al.*<sup>11</sup> concluded that the lower dental caries in children with ASD is a result of a decreased consumption of sweet snacks.

Shapira *et al.*<sup>20</sup> found lower caries prevalence and severe periodontal problems in these patients. Tharapiwattananon *et al.*<sup>21</sup> showed that half of the children with ASD had dental caries and poor oral hygiene, and the caries may lead to early tooth loss in these children and subsequently causes malocclusion. Desai *et al.*<sup>22</sup> also reported a higher prevalence of dental caries in children with ASD.

In this study, children with ASD had more untreated dental caries compared with healthy children, and the number of extracted and filled teeth in healthy children were more than children with ASD. These results could be due to poor dental awareness and poor cooperation of these children with dentists. On the other hand, the parents of children with ASD are often exhausted for constant supervision, feeding, bathing and the children are unable to follow oral hygiene instructions. In addition, inadequate training of dentists and dental specialists, and high sensitivity of these children to unfamiliar sounds, lights, odors and colors are the barriers to access their dental care.<sup>23</sup>

Namal *et al.*<sup>13</sup> reported that children with ASD had more extracted permanent teeth compared with healthy children. It is believed that extraction in children with ASD is preferred due to the challenging nature of their management.

There was no significant difference in frequency of sweet consumption between the children with ASD and healthy groups. These results are consistent with findings of previous studies conducted in Pakistan<sup>4</sup> and Egypt.<sup>23</sup>

Bruxism is one of the relatively common oral health problems in children with ASD.<sup>24,25</sup> In this study, 56.4% of the children with ASD and 3.6% of the healthy children had bruxism. In Önoğlu *et al.*<sup>26</sup> study, in the western mediterranean region of turkey, 41.3% of children with ASD and 5.4% of children without ASD had bruxism. El Khatib AA *et al.*<sup>23</sup> reported a higher prevalence of occlusal

facets, as an indication of bruxism, in children with ASD ( $p < 0.001$ )

During dental examination, children with ASD showed more uncooperative behaviors compared with the healthy children, which is in agreement with Marshall *et al.*, study<sup>27</sup>, in which 65% of children with ASD were uncooperative. It has been suggested that the behavioral management should involve gradual desensitization to familiarize these children with basic dental instruments and procedures.<sup>23</sup>

The results of the gingival status of children with ASD showed that 41.8% and 16.4% of them had localized and generalized gingivitis, respectively. In Jaber MA study<sup>6</sup> in the United Arab Emirates, 97% of children with ASD had gingivitis, which was generalized in 78% of the cases and localized in 22% of the studied cases.

According to the results obtained, the oral hygiene and gingival status of children with ASD were significantly poorer than that of healthy children, which could be attributed to irregular brushing, lack of ability to brush and side-effects of medications used to control the symptoms of this disorder.<sup>11</sup>

## CONCLUSIONS

The above discussion emphasizes the fact that the children with ASD had a higher prevalence of caries and gingivitis with poor cooperation during dental examination compared with healthy children. Therefore, comprehensive oral health educational programs should be implemented for their parents to prevent dental and oral diseases in the children with ASD. With regard to the increase of the number of children with ASD in recent years, it is essential to implement effective training programs to raise the awareness of dentists about the problems of these children, and to provide better dental services for them.

## ACKNOWLEDGEMENTS

We would like to thank Autism Rehabilitation Center of Rasht for their great support.

## CONFLICT OF INTEREST

The authors declare no conflict of interest.

## REFERENCES

1. Magoo J, Shetty AK, Chandra P, Anandkrishna L, Kamath PS, Iyengar U. Knowledge, attitude and practice towards oral health care among parents of autism spectrum disorder children. *J Adv Clin Res Insights* 2015; 2:82-86.
2. Simonoff E, Pickles A, Charman T, Chandler S, Loucas T, Baird G. Psychiatric disorders in children with autism spectrum disorders: prevalence, comorbidity, and associated factors in a population-derived sample. *J Am Acad Child Adolesc Psychiatry* 2008; 47:921-929.
3. Elder JH, Kreider CM, Brasher SN, Ansell M. Clinical impact of early diagnosis of autism on the prognosis and parent-child relationships. *Psychol Res Behav Manag* 2017; 10:283-292.
4. Suhaib F, Saeed A, Gul H, Kaleem M. Oral assessment of children with autism spectrum disorder in Rawalpindi, Pakistan. *Autism* 2019; 23:81-86.
5. Chandrashekhar S, Bommangoudar JS. Management of Autistic Patients in Dental Office: A Clinical Update. *Int J Clin Pediatr Dent* 2018; 11:219-227.
6. Jaber MA. Dental caries experience, oral health status and treatment needs of dental patients with autism. *J Appl Oral Sci* 2011; 19:212-217.
7. Delli K, Reichart PA, Bornstein MM, Livas C. Management of children with autism spectrum disorder in the dental setting: concerns, behavioural approaches and recommendations. *Med Oral Patol Oral Cir Bucal* 2013; 18:e862.
8. Karaaslan F, Dikilitaş A, Yiğit U. Oral Health Status and Associated Factors in a Subpopulation of Turkish Patients. *Cumhuriyet Dent J* 2019; 22(2):167-175.
9. Altın KT, Alp F, Aydın SN, Çıldır ŞK, Sandallı N. Improvement of Oral Health Status in a Group of Students with Visual Impairment in Istanbul. *Cumhuriyet Dent J* 2019; 22(1):83-91.
10. Reka Vishnu C, Arangannal P, Shahed H. Oral health status of children with autistic disorder in chennai. *Eur Arch Paediatr Dent* 2012; 13:126-131.
11. Sarnat H, Samuel E, Ashkenazi-Alfasi N, Peretz B. Oral health characteristics of preschool children with

- autistic syndrome disorder. *J Clin Pediatr Dent* 2016; 40:21-25.
12. Subramaniam P, Gupta M. Oral health status of autistic children in India. *J Pediatr Dent* 2011;36 :43-46.
13. Namal N, Vehit H, Koksall S. Do autistic children have higher levels of caries? *J Indian Soc Pedod Prev Dent* 2007; 97-102.
14. World Health Organization. Oral Health Surveys. Basic method. 4<sup>th</sup> ed. Geneva:WHO;1997.
15. Loe H, Silness J. The gingival index, the plaque index and the retention index systems. *J Periodontol* 1967;41:41-43.
16. Frankl SN, Shiere FR, Fozzeles HR. Should the parent remain with the child in the dental operator? *J Dent Child* 1962;29:150-163.
17. Knight DJ, Leroux BG, Zhu C, Almond J, Ramsay DS. A longitudinal study of tooth wear in orthodontically treated patients. *Am J Orthod Dentofac Orthop* 1997;112:194-202.
18. Newschaffer CJ, Croen LA, Daniels J et al. the epidemiology of autism spectrum disorders. *Annu Rev Public Health* 2007; 28:235–258.
19. Geier, Kern, Geier. A prospective study of oxidative stress biomarkers in autistic disorders. *Electronic J Applied Psychology* 2009; 5(1): 2-10.
20. Shapira J, Mann J, Tamari I, Mester R, Knobler H, Yoeli Y, Newbrun E. Oral health status and dental needs of an autistic population of children and young adults. *Spec Care Dentist* 1989;9:38-41.
21. Tharapiwattananon T. Autistic child and dental management. *Cu Dent J* 1994;17:1-10.
22. Desai M, Messer LB, Calache H. A study of the dental treatment needs of children with disabilities in Melbourne, Australia. *Aust Dent J* 2001;46:41-50.
23. El Khatib AA, El Tekeya MM, El Tantawi MA, Omar T. Oral health status and behaviours of children with Autism Spectrum Disorder: a case-control study. *Int J Paediatr Dent* 2014;24:314-323.
24. Gandhi RP, Klein U. Autism spectrum disorders: an update on oral health management. *J Evid Based Dent Pract* 2014;14:115-126.
25. Muthu MS, Prathibha KM. Management of a child with autism and severe bruxism: a case report. *J Indian Soc Pedod Prev Dent* 2008;26:82.
26. Önel S, Kırzioğlu Z. Evaluation of oral health status and influential factors in children with autism. *Niger J Clin Pract* 2018;21:429-435.
27. Marshall J, Sheller B, Williams BJ, Mancl L, Cowan C. Cooperation predictors for dental patients with autism. *Pediatr Dent* 2007;29:369-376.



## EVALUATION OF LONG-TERM RESULTS OF TWO DIFFERENT CALCIUM SILICATE BASED MATERIALS IN PRIMARY MOLAR TEETH VITAL PULPOTOMIES: AN INVIVO STUDY

### ABSTRACT




**Objectives:** Pulpotomy is one of the pulp therapy for cariously exposed pulps in primary molar teeth. There are several materials that allows regeneration of the residual pulp. The purpose of this study was to evaluate the efficacy of two different calcium silicate based materials (ProRoot MTA, BIOfactor MTA) in primary molar teeth vital pulpotomies.

**Materials and Methods:** A total of 12 children (24 human mandibulary primary second molar teeth) aged between 6 and 9 years were selected in this randomized clinical study. The patients were randomly assigned to receive the pulpotomy medicaments. All pulpotomized teeth were restored with stainless steel crowns and evaluated clinically and radiologically at 1, 3, 6 and 12 months. Statistical analysis using chi-square test was performed to determine the significant differences between two materials.

**Results:** Neither clinical nor radiographical differences were seen in 1st, 3rd and 6th months but in 12th month ProRoot MTA showed statistically better results in clinical evaluation ( $p=0.047$ ).

**Conclusions:** Both two calcium silicate based materials showed similar clinical and radiographical results by the end of 6th month but ProRoot MTA showed better results at the end of 12th month.

**Keywords:** ProRoot MTA, BIOfactor MTA, pulpotomy.

 \*Fatih OZTURHAN<sup>1</sup>  
 Mevlut KAYABAŞI<sup>1</sup>  
 Büşra KESKÜŞ<sup>1</sup>

ORCID IDs of the authors:

F.Ö. 0000-0002-7797-0932

M.K. 0000-0002-8138-4346

B.K. 0000-0002-6966-8442

<sup>1</sup> Sivas Cumhuriyet University, Faculty of Dentistry, Department of Pedodontics, Sivas, Turkey

Received : 25.11.2019

Accepted : 20.02.2020

## **INTRODUCTION**

At the present time, in spite of the reduction of dental caries prevalence in different parts of the world, this disease continues to be one of the major public health problems affecting many children and adolescents in its most severe form.<sup>1-3</sup>

Primary teeth are important because of their function as a space maintainer for the permanent teeth below, stimulating the vertical development of the jaws with chewing movements, contributing to the nutrition, growth and development of the child, phonation and aesthetic functions. Therefore, preservation of the dental arch until the time of physiological fall is necessary in terms of permanent dentition and jaw development.<sup>4,5</sup> If they leave untreated or extracted; decreased chewing function, loss of space, malocclusion formation, speech disorders, psychological disorders, surgical trauma, atypical language habits may occur. In order to avoid such problems, it is necessary to maintain the function of the teeth at the dental arch till they exfoliate.<sup>6</sup>

The structural and histological differences between the pulps of primary teeth and the pulps of permanent teeth affect the primary teeth pulp response to carious lesions and pulp therapies.<sup>7</sup> Pulpotomy is one of the most common therapy in primary teeth. Pulpotomy therapy is defined as the process of removing the teeth of the infected tooth and removing the normal root pulp of the normally infected root pulp and maintaining the vitality and function of the tooth with a bactericidal agent. Clinicians have used different pulpotomy agents and methods, such as formocresol, a calcium silicate-based bioactive material, Ankaferd blood stopper, enamel matrix derivative, calcium hydroxide, zinc oxide and eugenol, sodium hypochlorite, glutaraldehyde, ferric sulfate, Portland cement, mineral trioxide aggregate (MTA), calcium hydroxide and iodoform, electrosurgery, and laser therapies.<sup>8, 9</sup> The ideal agent or method for amputation treatment of primary teeth has not yet been determined.<sup>10</sup>

MTA has been recognized for its high success rate in clinical and radiological examinations in conservative pulp therapies.

However, the MTA has a long curing time and requires moisture during hardening, its manipulation is difficult. Therefore, researchers continue to research to improve the physical properties of materials.<sup>10</sup>

A new type of MTA, BIOfactor MTA (Imicryl Dental, Konya, Turkey), has recently been introduced on the market to be used for pulp capping, pulpotomies, apexification, root end filling, apical plug procedures and root perforation repairs. This cement can be prepared in a flowing or thickness, based on the treatment type. The manufacturer claims that BIOfactor MTA has a shorter setting time, finer powder for faster hydration, easier handling properties, stronger sealing, and that it does not cause tooth discoloration. Moreover, BIOfactor MTA seems to be a lower costing product. There is no difference between materials and methods during the use of both materials. Depending on the content of the materials, the mixing times vary.<sup>10</sup>

The new material BIOfactor MTA had never been tested in primary molar teeth with a long time period. Therefore, the aim of this study is to compare and evaluate the long-term results of the primary teeth vital amputations of two different calcium-silicate-based materials (ProRoot MTA and BIOfactor MTA) used in routine clinical practice.

## **MATERIALS AND METHODS**

Ethical approval was obtained from Sivas Cumhuriyet University Clinical Research Ethics Committee (2017-07/35) and the study was conducted at the Faculty of Dentistry, Department of Pediatric Dentistry, Sivas Cumhuriyet University. The clinical procedure, associated risks, and benefits were fully explained to the parents of the participants and written consent to participate was obtained before the procedure.

### **Sample Size Calculation**

Sample size was performed under the assumption of studies that have resemble to our study.<sup>9, 11, 12</sup> Accepting  $\alpha = 0.05$ ,  $\beta = 0.10$ ,  $(1-\beta) = 0.90$  a total of 24 subjects are necessary (12 in ProRoot MTA group and 12 in BIOfactor MTA group). The power of test was found 0,90169. The study was

performed on 24 mandibular, carious primary second molar teeth of 12 patients (7 girls, 5 boy), aged between 6 and 9 years (in the mind of starting root resorption age according to Logan and Kronfeld)<sup>13</sup> assigned into two groups that included ProRoot MTA and, BIOfactor MTA allocating 12 teeth in each group using simple lottery method.

Intra- and extraoral examinations of patients were performed before the treatment and their initial radiologic examinations were performed.

Patients who had no disease, such as congenital or rheumatic heart disease, leukemia, allergic reactions to substances, such as local anesthetics and latex, who did not require general anesthesia and sedation, and who had good individual and family cooperation were included in the study.

The teeth requiring pulpotomy were selected based on the inclusion criteria: deep cavity lesions that exposed vital pulp during the removal of caries; no history of spontaneous or nocturnal pain; absence of clinical symptoms such as swelling, fistula, tenderness of the percussion or palpation, pathologic mobility; those in which hemostasis was achieved within 5 minutes during clinical procedure; and the presence of two-thirds of the root length radiographically. No

**Table 1.** Compositions of MTAs

Material	Composition
BIOfactor MTA	<i>Liquid:</i> Demineralised water, 1-5% hydrosoluble polymer for gelling effect and reology. <i>Powder:</i> Tricalcium silicate, dicalcium silicate and tricalcium aluminate calcium sulphate hemihydrate. Ytterbium Oxide for radiopacity. There is no Bismuth due do discoloration of tooth
ProRoot MTA	<i>Liquid:</i> Distilled water <i>Powder:</i> Calcium silicate, calcium sulfate, tricalcium aluminate, calcium oxide, iron oxide, and bismuth oxide

MTA was prepared according to the manufacturer's instructions by mixing MTA powder with distilled water in a 3:1 ratio and pulp stumps were covered. The MTA condensed lightly with a moistened cotton pellet. Resin-modified glass ionomer cement (Vitrebond 3M ESPE, Seefeld, Germany) was placed to fill the pulp chamber. The teeth were restored with stainless steel crowns (3M ESPE, Dental

radiographic evidence of pulp degeneration, such as internal or external root resorption, furcal radiolucency, interradicular or periapical bone destruction, or pulp stones.

The 24 teeth that were considered according to the abovementioned criteria were randomized into two study groups. In the first group, ProRoot MTA pulpotomy was performed on 12 teeth and BIOFactor MTA pulpotomy was performed on the rest in the second group.

**Treatment Procedures**

After performing topical anesthesia by lidocaine spray, regional anesthesia was administered by Maxicaine D-S (Maxicaine, Vem İlaç, Ankara, Turkey). All cavity lesions were removed and an access cavity was prepared under the isolation of rubber dam. A low-speed sterile round bur (No.12, No.18) and excavator were used for removing coronal pulp. Sterile cotton pellets moistened with sterile saline were placed over the pulp stumps and was applied with a light pressure for 5 minutes. All pulpotomy procedures were performed by one pediatric dentist.

After the bleeding control is achieved, one of the treated pulps of the teeth will be applied to the ProRoot MTA (Dentsply Tulsa Dental, Tulsa, OK, USA) and the other to the BIOfactor MTA (Imicryl Dental, Konya, Turkey)(Table 1).

Products, St. Paul, MN, USA) and cemented with glass ionomer cement (Meron® Voco, Cuxhaven, Germany). The reason we cover with stainless steel crowns is to prevent possible microspheres.

**Evaluation of Pulpotomy Treatment and Stainless Steel Crown (SSC) Application**

After applying SSC, the first radiographs were taken and the patients were recalled for clinical and radiographic evaluation after 1, 3, 6 and 12

months. Clinical and radiological evaluations were performed independently by two experienced pediatric dentists. The teeth were considered successful if they had no symptoms of palpation–percussion sensitivity, spontaneous pain, hot–cold sensitivity, presence of fistula as welling, pathologic mobility, internal–external resorption, periapical/interradicular bone destruction, disintegration of the lamina dura, enlargement of the periodontal space, and radiological calcific metamorphosis.

### Statistical evaluation

The data obtained from our study were loaded into SPSS (22.0) program and chi-square test was performed to determine the significant differences between two materials. A *P* value <0.05 was considered statistically significant.

### RESULTS

12 children were participated to this study and 58.33% were girls (n=7), and 41.67% were boys (n=5).

Radiological and clinical evaluation of ProRoot MTA and BIOfactor MTA (1-12 months) were shown on Table 2.

**Table 2.** Radiological and clinical evaluation of ProRoot MTA and BIOfactor MTA (1-12 months)

Recall Periods/Materials	Radiographical Evaluation		Clinical Evaluation				
	Success (n)	Failure (n)	Success (n)	Failure (n)			
1. Month ProRoot MTA	12		12				
	BIOfactor MTA	12	12				
3. Month ProRoot MTA	11	1	12	0			
	BIOfactor MTA	9	3	10	2		
					p=0.295		p=0.239
6. Month ProRoot MTA	11	1	12	0			
	BIOfactor MTA	8	4	9	3		
					p=0.158		p=0.109
12. Month ProRoot MTA	10	2	12	0			
	BIOfactor MTA	7	5	8	4		
					p=0.185		*p=0.047

\* p<0.05

There were no significant differences at the end of the 1<sup>st</sup> month and both two groups showed no failure.

At the end of 3<sup>rd</sup> month, ProRoot MTA showed 1 radiographical failure and BioFactor MTA showed 3 radiographical and 2 clinical failure but that remained no statistically differences.

ProRoot MTA showed 1 radiographical failure and BioFactor MTA showed 4 radiographical and 3 clinical failure at the end of 6<sup>th</sup> month and there no significant differences.

At the end of 12<sup>th</sup> month ProRoot MTA showed 2 radiographical failure and BioFactor MTA showed 5 radiographical and 4 clinical failure and ProRoot MTA showed statistically better results in clinical evaluation (p=0.047).

### DISCUSSION

Pulpotomy is a routine procedure in pediatric dentistry for asymptomatic primary molar teeth that have been exposed with caries. The aim of this procedure is to amputate the infected coronal pulp tissue and cover the vital radicular pulp tissue using an agent such as biocompatible, non-irritating, impermeable and also bioinductive. With the development of materials that have all these properties, the research for pulpotomy agents has expanded. One of these materials that have been used in routine in clinics is MTA.<sup>14</sup> This clinical trial was conducted to evaluate the effects of the use of two different calcium silicate based materials as ProRoot MTA and BIOfactor MTA as pulpdressing agents during pulpotomies of primary molars.

The manufacturer of BIOfactor MTA claims that the new MTA has easier handling properties, a finer powder for faster hydration, stronger



sealing and a shorter setting time, and that it does not cause tooth discoloration. Additionally, BIOfactor MTA seems to be a lower costing product. In this present study, we aimed to evaluate as a novel type of calcium-silicate based cements called BIOfactor MTA compared to a well-known and an overworked material as ProRoot MTA on the clinical and radiological success in primary molar pulpotoomies. The results of this study showed that there was no statistically significant differences between two MTAs in 1., 3. and 6. Months of follow-up however ProRoot MTA found successful when compared to BIOfactor MTA in 12. Months clinical follow-up.

There are numerous studies have evaluated on the clinical and radiological success of different types of MTA in pulpotomy and showed that all types of MTA had good results.<sup>15-20</sup> Both MTA Angelus and ProRoot MTA had significantly greater clinical and radiographic success rates compared to calcium hydroxide following pulpotomy in primary molar teeth.<sup>21,22</sup> No significant difference was found between two different MTAs such as white and gray ProRootMTA as pulpotomy agents in primary teeth.<sup>23,24</sup> In this study, ProRoot MTA and BIOfactor MTA have also high clinical and radiological success rates.

Celik *et al.*<sup>21</sup> evaluated of clinical and radiological success of ProRoot MTA and MTA Angelus and revealed that ProRoot MTA had high clinical (for ProRoot MTA 98% - for MTA Angelus 96%) and radiological (for ProRoot MTA 98% - for MTA Angelus 69%) success rate in 24-months follow-up despite of there were no statistically significant differences. Our findings are in agreement with this previous research that revealed no statistically significant differences between ProRoot and BIOfactor MTA in first 6 months. However, in 12 months follow-up, ProRoot MTA had statistically significant higher clinical (for ProRoot MTA 100% – for BIOfactor MTA 66.6%) and radiological (for ProRoot MTA 83.3% – for BIOfactor MTA 58.3%) success rates than BIOfactor MTA ( $p<0.05$ ).

There were four clinical failures that all in BIOfactor MTA group. The failures in this present

study involved gingival swelling, which has long been considered a clinical failure after a primary molar pulpotomy treatment.<sup>17,25,26</sup> However, the molars suffering from gingival swelling could cause by lack of oral hygiene and accumulation of dental plaque around the stainless steel crowns or a combination of these two factors. The BIOfactor MTA has some different component like ytterbium oxide, which added in the cement as a radiopacifier agent, unlike ProRoot MTA. This chemical composition differences could cause by changing the cement's penetration into the dentin tubules that due to leakage. The effects of different chemical composition in the calcium silicate-based material on the material's physicochemical properties are unknown. Further studies are required to determine the results of these changings.

There were two radiological failures in ProRoot MTA group which did not shown as a clinical failure finding on the evaluated samples. In this study, these examined primary molars remained asymptomatic during 12 months follow-up. In BIOfactor MTA group, there were five radiological failures which the same four molars of these radiologically failed five were shown as a clinical failure finding. The inconsistency of these findings in BIOfactor MTA group could be caused by the decision of the clinical observer's of the study which was the tooth without clinical failure findings could be delayed for extraction. The reasons for radiological failures should be histologically evaluated, which is one of the shortcomings of the study.

One of the limitations of this study is the setting time. Setting time is a crucial factor for these materials. There a lot of study that compared the setting time of calcium silicate based materials, but there is no consensus about the initial time and final curing time.<sup>27</sup> Long setting times are bringing many problems and researches are trying to overcome with this problem. Haghgoo and Abbasi<sup>28</sup> declared that when MTA was not condensed evenly, and the ratio of powder to liquid, temperature and air entrapped into the mass, can affect the form of the material

and these factors may have affected the outcome of our study.

One of the limitations of this study is the small sample size, therefore these results should be done with a large number of participants and with an increased follow-up period.

## CONCLUSIONS

Two calcium silicate based materials showed similar clinical and radiographical results by the end of 6th month but ProRoot MTA showed better results at the end of 12th month.

## ACKNOWLEDGEMENTS

This work was supported by the Scientific Research Project Fund Cumhuriyet University [grant number DIS-208].

## CONFLICT OF INTEREST

The authors declare that they have no conflict of interest.

## REFERENCES

1. Gimenez T, Bispo BA, Souza DP, Vigano ME, Wanderley MT, Mendes FM, Bonecker M, Braga MM. Does the Decline in Caries Prevalence of Latin American and Caribbean Children Continue in the New Century? Evidence from Systematic Review with Meta-Analysis. *PLoS One*. 2016;11:1-14.
2. Kassebaum NJ, Smith AGC, Bernabe E, Fleming TD, Reynolds AE, Vos T, Murray CJL, Marcenes W, Collaborators GBDOH. Global, Regional, and National Prevalence, Incidence, and Disability-Adjusted Life Years for Oral Conditions for 195 Countries, 1990-2015: A Systematic Analysis for the Global Burden of Diseases, Injuries, and Risk Factors. *J Dent Res*. 2017;96:380-387.
3. Stringhini Junior E, Dos Santos MGC, Oliveira LB, Mercade M. MTA and biodentine for primary teeth pulpotomy: a systematic review and meta-analysis of clinical trials. *Clin Oral Investig*. 2019;23:1967-1976
4. Caicedo R, Abbott PV, Alongi DJ, Alarcon MY. Clinical, radiographic and histological analysis of the effects of mineral trioxide aggregate used in direct pulp capping and pulpotomies of primary teeth. *Aust Dent J*. 2006;51:297-305.
5. Godhi B, Sood PB, Sharma A. Effects of mineral trioxide aggregate and formocresol on vital pulp after

pulpotomy of primary molars: An in vivo study. *Contemp Clin Dent*. 2011;2:296-301

6. Misra S, Tahmassebi JF, Brosnan M. Early childhood caries--a review. *Dent Update*. 2007;34:556-564.
7. Smail-Faugeron V, Glenny AM, Courson F, Durieux P, Muller-Bolla M, Fron Chabouis H. Pulp treatment for extensive decay in primary teeth. *Cochrane Database Syst Rev*. 2018; 5: CD003220.
8. Shafae H, Alirezaie M, Rangrazi A, Bardideh E. Comparison of the success rate of a bioactive dentin substitute with those of other root restoration materials in pulpotomy of primary teeth: Systematic review and meta-analysis. *J Am Dent Assoc*. 2019;150:676-688.
9. Carti O, Oznurhan F. Evaluation and comparison of mineral trioxide aggregate and biodentine in primary tooth pulpotomy: Clinical and radiographic study. *Niger J Clin Pract*. 2017;20:1604-1609.
10. Lin PY, Chen HS, Wang YH, Tu YK. Primary molar pulpotomy: a systematic review and network meta-analysis. *J Dent*. 2014;42:1060-1077.
11. Cuadros-Fernandez C, Lorente Rodriguez AI, Saez-Martinez S, Garcia-Binimelis J, About I, Mercade M. Short-term treatment outcome of pulpotomies in primary molars using mineral trioxide aggregate and Biodentine: a randomized clinical trial. *Clin Oral Investig*. 2016;20:1639-1645.
12. Gandolfi MG, Siboni F, Polimeni A, Bossù M, Riccitiello F, Rengo S. In vitro screening of the apatite-forming ability, biointeractivity and physical properties of a tricalcium silicate material for endodontics and restorative dentistry. *Dentistry Journal*. 2013;1:41-60.
13. Logan WH, Kronfeld R. Development of the human jaws and surrounding structures from birth to the age of fifteen years. *The Journal of the American Dental Association* 1933;20:379-428.
14. Agamy HA, Bakry NS, Mounir MM, Avery DR. Comparison of mineral trioxide aggregate and formocresol as pulp-capping agents in pulpotomized primary teeth. *Pediatr Dent*. 2004;26:302-309.
15. Ansari G, Ranjpour M. Mineral trioxide aggregate and formocresol pulpotomy of primary teeth: a 2-year follow-up. *Int Endod J*. 2010; 43(5): 413-418

16. Farsi N, Alamoudi N, Balto K, Mushayt A. Success of mineral trioxide aggregate in pulpotomized primary molars. *J Clin Pediatr Dent.* 2005;29:307-311
17. Holan G, Eidelman E, Fuks AB. Long-term evaluation of pulpotomy in primary molars using mineral trioxide aggregate or formocresol. *Pediatr Dent.* 2005;27:129-136
18. Niranjani K, Prasad MG, Vasa AA, Divya G, Thakur MS, Saujanya K. Clinical Evaluation of Success of Primary Teeth Pulpotomy Using Mineral Trioxide Aggregate((R)), Laser and Biodentine(TM)-an In Vivo Study. *J Clin Diagn Res.* 2015;9:35-37
19. Nowicka A, Lipski M, Parafiniuk M, Sporniak-Tutak K, Lichota D, Kosierkiewicz A, Kaczmarek W, Buczkowska-Radlinska J. Response of human dental pulp capped with biodentine and mineral trioxide aggregate. *J Endod.* 2013;39:743-747
20. Sonmez D, Sari S, Cetinbas T. A Comparison of four pulpotomy techniques in primary molars: a long-term follow-up. *J Endod.* 2008;34:950-995
21. Celik B, Atac AS, Cehreli ZC, Uysal S. A randomized trial of mineral trioxide aggregate cements in primary tooth pulpotomies. *J Dent Child (Chic).* 2013;80:126-132
22. Liu H, Zhou Q, Qin M. Mineral trioxide aggregate versus calcium hydroxide for pulpotomy in primary molars. *Chin J Dent Res.* 2011;14:121-125
23. Cardoso-Silva C, Barberia E, Maroto M, Garcia-Godoy F. Clinical study of Mineral Trioxide Aggregate in primary molars. Comparison between Grey and White MTA--a long term follow-up (84 months). *J Dent.* 2011;39:187-193
24. Frenkel G, Kaufman A, Ashkenazi M. Clinical and radiographic outcomes of pulpotomized primary molars treated with white or gray mineral trioxide aggregate and ferric sulfate--long-term follow-up. *J Clin Pediatr Dent.* 2012;37:137-141
25. Erdem AP, Guven Y, Balli B, Ilhan B, Sepet E, Ulukapi I, Aktoren O. Success rates of mineral trioxide aggregate, ferric sulfate, and formocresol pulpotomies: a 24-month study. *Pediatr Dent.* 2011;33:165-170
26. Huth KC, Paschos E, Hajek-Al-Khatat N, Hollweck R, Crispin A, Hickel R, Folwaczny M. Effectiveness of 4 pulpotomy techniques--randomized controlled trial. *J Dent Res.* 2005;84: 1144-1148
27. Parirokh M, Torabinejad M. Mineral trioxide aggregate: a comprehensive literature review--Part I: chemical, physical, and antibacterial properties. *J Endod.* 2010;36:16-27
28. Haghgoo R, Abbasi F. Treatment of Furcal Perforation of Primary Molars with ProRoot MTA versus Root MTA: A Laboratory Study. *Iran Endod J.* 2013;8:52-54



## EFFECT OF IRRIGATION SOLUTION TEMPERATURE ON THE OSSEOINTEGRATION OF DENTAL IMPLANTS

### ABSTRACT

**Objectives:** Thermal trauma during implant surgery limits the proper healing process. The aim of the study was to investigate the effect of different irrigation temperatures during implant surgery on the osseointegration of dental implants.

**Materials and Methods:** Eight adult male New Zealand white rabbits were used in this study. Total of 32 implants were inserted in each tibia of each rabbit's rear legs. Rabbits were randomly divided according to different irrigation procedures applied (37°C, 24°C, 10°C, and 1°C). Resonance frequency analysis (RFA) was performed following to implant surgery, 1st week, 2nd week, 3rd week, and 1st month. In addition, removal torque values (RTVs) were measured from sacrificed tibias at the end of 30 days.

**Results:** No significant difference in implant stability quotient (ISQ) was detected between groups from the first measurement to 5th measurement. However, there was a statistically significant difference in RTVs between 1°C and 37°C, and 1°C and 10°C (p=0.024 and p=0.013, respectively).

**Conclusions:** Different irrigation temperatures during implant surgery were not effective on the primary and secondary stability values of dental implants in rabbit models.

**Key Words:** Dental implant, osseointegration, trauma, rabbit model.

\*Doğukan YILMAZ<sup>1</sup>  
 Halit FURUNCUOĞLU<sup>2</sup>  
 Osman VAROL<sup>3</sup>  
 Hakan AKIN<sup>4</sup>

ORCID IDs of the authors:

D.Y. 0000-0003-2576-0885

H.F. 0000-0002-2093-4121

O.V. 0000-0002-9775-4954

H.A. 0000-0002-4770-4297

<sup>1</sup> Department of Periodontology, Faculty of Dentistry, Sakarya University, Sakarya, Turkey.

<sup>2</sup> Department of Oral and Maxillofacial Surgery, Faculty of Dentistry, Sakarya University, Sakarya, Turkey.

<sup>3</sup> Department of Prosthodontics, Faculty of Dentistry, Sivas Cumhuriyet University, Sivas, Turkey.

<sup>4</sup> Department of Prosthodontics, Faculty of Dentistry, Sakarya University, Sakarya, Turkey.

Received : 03.01.2020

Accepted : 09.03.2020

## INTRODUCTION

Osseointegration is a key factor for dental implant survival and success. To establish an optimal osseointegration, atraumatic surgery is a crucial determinant.<sup>1</sup> Gentle drilling and preservation of healthy tissues are essential prerequisites for atraumatic surgery.<sup>2</sup> During implant bed preparations not only mechanical damage but also thermal trauma occurs.<sup>3,4</sup> Thermal trauma damages the tissue and limits the proper healing process which is essential for implant survival and success.<sup>5</sup>

Temperature ranging from 47°C to 50°C up to 1 minute during implant bed preparation were found to upper threshold to avoid thermal necrosis.<sup>6</sup> Thermal trauma effects both organic and inorganic structures of surrounding surgical area. It leads to inactivation of enzymes and proteins which are required to optimal healing.<sup>7</sup> According to a study, dislocation of hydroxyapatite mineral structure and microscopic bone deformation also induced by thermal trauma<sup>8</sup>, in clinical point of view this may effect primary stability of dental implants and risk of early failure rates increase dramatically.<sup>8,9</sup>

To overcome the unwanted effects of thermal trauma many *in-vitro* and *in-vivo* studies evaluated the potential indicator of thermal trauma.<sup>4,10-24</sup> They concluded multiple factors associated with the condition e.g: drill speed<sup>10,11</sup>, drill material<sup>12</sup>, drilling technique<sup>13</sup>, drill diameter<sup>14</sup>, drill configuration<sup>4</sup>, bone type<sup>15</sup>, irrigation method<sup>16,17-20</sup>, irrigation solution volume<sup>21,22</sup>, and surgical technique.<sup>23</sup> Irrigation solution temperature is also one of the crucial indicator which effect thermal trauma.<sup>24</sup> It has been concluded that cold irrigation solution can minimize temperature elevation at the surface<sup>11</sup> and according to an *in-vitro* study, external irrigation at room temperature can provide sufficient cooling during implant bed preparation<sup>24</sup>, however to the best of author's knowledge data is available regarding impact of irrigation solution temperature on osseointegration. In consideration of these premises, the aim of the study was to investigate the effect of different irrigation solution temperatures, during implant bed preparation, on the osseointegration of dental implants. The hypothesis of lower temperature of irrigation solution would improve the osseointegration was tested.

## MATERIALS AND METHODS

### *Study material and design*

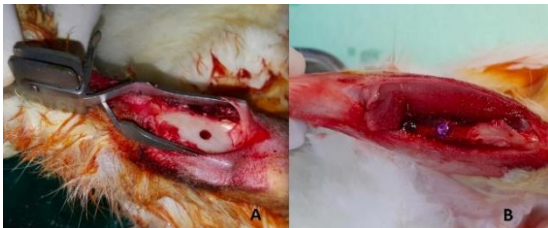The study protocol was approved by local ethical committee of the Animal Ethics Commission of Cumhuriyet University (protocol number: 65202830-050.04.04-31). Eight, healthy, male, white rabbits (*Oryctolagus cuniculus*, New Zealand) with body weight 3 kg were included the study. Rabbits were housed in standard room conditions (22-24°C, 12/12 light/dark cycle, %55-70 humidity, 1 atm) and each rabbit was housed in separate cages. The conditions of animals were monitored every day. Rabbits were placed in cages two weeks ago to adopt their environmental conditions.

Rabbits were randomly divided according to different irrigation solution temperature applied (37°C, 24°C, 10°C, and 1°C).

### *Surgical procedure*

Surgical procedures were applied under general anesthesia. The animals were sedated intramuscularly with 10mg/kg xylazine (Rompun 2%, Bayer, İstanbul, Turkey) and 90 mg/kg Ketamin HCl (Ketalor, Eczacıbaşı-Warner Lambert, İstanbul, Turkey). After anesthesia was obtained, proximal tibia area was shaved unilaterally and local anesthetic articaine HCl (Ultracal DS Fort Aventis Pharma, İstanbul, Turkey), intravenous prophylactic antibiotics (50 mg/kg cefazolin) and analgesic (1 mg/kg Tramadol HCl) were injected then, surgical area was covered by sterile drapes and antiseptic solution was applied. (Povidone-iodine, Batticon, Genesis, İstanbul, Turkey). 2 cm skin incision extending distally from the medial of the proximal metaphysis of the tibia was followed by the dissection of soft tissue and detachment of the periosteum was performed in the left and right tibia of every rabbit. At least 6 mm horizontal distance were measured on each osteotomy area. Osteotomies were performed in same room conditions (temperature: 23-24°C, relative humidity: 50±5%, and no direct ventilation.) with different irrigation solution temperatures. (37°C, 24°C, 10°C, and 1°C). The irrigation solution temperatures were measured just before the procedure by liquid thermometer. (HB Durac, SP-Scienceware, NJ, USA). For each different irrigation solution temperature, the same surgical and stability

measurements stages were applied. The osteotomies were performed according to manufacturer recommendations. Each animal was received 3.5×7 mm (Anyone, MegaGen Implant, Daegu, Korea) implants. Briefly TiN coated initial (Ø1.8) and shaping drills (Ø2.8, Ø3.3) were applied, shaping drills were 0.59mm longer than the fixture, so total drill depth was 7.59mm. Drilling time for each implant was approximately 5 minutes and multiple drilling steps were applied at 1500 rpm. Each different temperatures of irrigation solution were applied externally with using a physiodispenser pump (MEG-ENGINE, MegaGen Implant, Daegu, Korea). Each osteotomy was performed by the same experienced surgeon (OV) for operative standardization. Implants were inserted into preparation cavity with ratchet. In order to carry out the stability measurements, the gingival formers were mounted on the implants. Total of 4 implants were applied in each animals (2 left, 2 right) overall 32 osteotomies and implants were applied. Figure 1 illustrates the surgical steps.



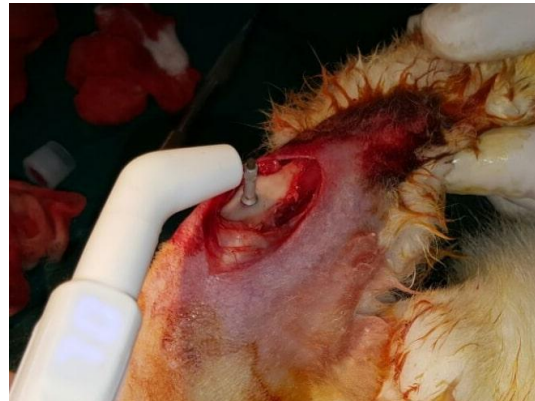**Figure 1:** Surgical steps of the study. (A) Mucoperiosteal flap elevation and implant bed preparation. (B) Insertion of dental implants.

The periosteum, fascia and skin were sutured with Vicryl resorbable sutures (Ethicon, Somerville, NJ, USA). Post-operatively animals were administered 50 mg/kg Cephaxon IM and 4 mg/kg Rimadyl 20 cc flakon for 3 days subcutaneously, besides wound areas were irrigated with Rifamicin SV (Rifeten, Ulagay İlaç Sanayi, Istanbul, Turkey).

### **Stability measurements**

Resonance frequency analysis (RFA) was performed on the implants to detect the degree of primary osseointegration by using the Mega ISQ device (MegaGen Implant, Korea). In brief, a connector so called Smartpeg was screwed into implants, taking care to ensure that no significant torque force was applied to the implants and then implant stability quotient (ISQ) values were

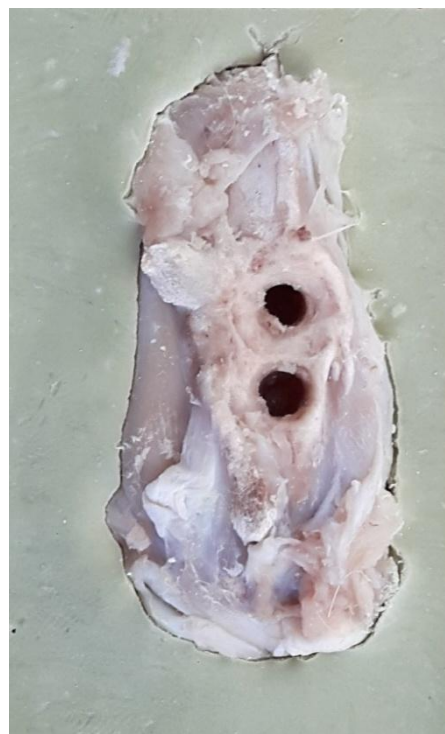measured. For each implant, the probe of the ISQ machine was held stable at a distance of approximately 2 mm from the Mega ISQ device, Figure 2 illustrates the related step.



**Figure 2:** The measurement of ISQ value with Mega ISQ® device.

Two measurements were conducted on the mesial and distal parts of the device, and mean ISQs were recorded. 5 measurements (following to implant surgery, 1th week, 2nd week, 3rd week, and 1th month) were carried out. In post operative 1st month, animals were sacrificed with an intramuscularly administered 200 mg/kg i.p. sodium pentobarbital.

Prior to removal torque test (RTT), resected tibia fragments were embedded into type IV dental stone (Figure 3) (Moldano, Heraeus Kulzer GmbH, Hanau, Germany).



**Figure 3:** Resected tibia fragments were embedded into type IV dental stone, prior to RTV.

RTT was then performed on the implants. The blocks were stabilized by the second researcher, and a digital torque meter (IMADA, Northbrook, IL, USA) was positioned in the direction of the implant axis which presented in Figure 4.



**Figure 4:** Illustration of RTV measurements which performed by digital torque meter.

The removal torque values (RTVs) were measured until the implant rotated inside the bone tissue, completely rupturing the bone-implant interface. These RTVs were then recorded for statistical analysis.

**Statistical Analysis**

The present methodology was reviewed by an independent statistician. The mean and standard deviations and statistical analyzes of the data were calculated using SPSS 14.0 (SPSS Inc., Chicago, USA) program. Normality of data distribution was confirmed by using Q-Q plot test. The data were analyzed with two-way ANOVA and post hoc Tukey-Kramer multiple comparisons tests ( $\alpha=0.05$ ).

**RESULTS**

The healing was uneventfull and any implant or animal loss was not observed until the sacrifice. The RFA and RTV values, obtained from study groups, presented in Table 1.

**Table 1.** Mean RFA (ISQ) and RTV (N/cm) Values Obtained from Study Groups.

	Groups	Mean	SD	N
RFA (ISQ)	37°C	69.37	Ara.59	8
	24°C	70.25	13.27	8
	10°C	64	Kas.78	8
	1°C	69.12	Eyl.78	8
	Total	68.18	Kas.61	32
RTV (N/cm)	37°C <sup>b</sup>	22.25	14.42	8
	24°C	26.91	Haz.76	8
	10°C <sup>a</sup>	21.Şub	Ağu.18	8
	1°C <sup>a,b</sup>	37.98	10.Haz	8
	Total	27.Nis	Kas.89	32

\*Lower case letters represent significant differences in rows. RFA: Resonance Frequency Analyse, ISQ: Implant Stability Quatient, RTV: Reverse Torque Value, SD: Standard Deviation

The samples from irrigation solution temperature 24°C group had the highest mean ISQ values (70.25), while the samples from 10°C irrigation solution temperature group had the lowest mean ISQ scores (64.00). However no statistically significant difference in mean ISQ values were detected between the sample groups from first to 5th measurement. ( $p>0.05$ )

The highest mean RTV values were measured from the samples in 1°C irrigation solution temperature group (37.98 N/cm) while the samples in 10°C irrigation solution temperature group had the lowest mean RTV scores (21.02 N/cm). This difference between the groups was statistically significant ( $p=0.013$ ), also another statistically significant difference presented between the

samples from groups of 1°C and 37°C irrigation solution temperature, in mean RTV values ( $p=0.024$ ).

## DISCUSSION

To best of author's knowledge this is the first study which the effect of irrigation solution temperature on primary and secondary dental implant stability values was tested. The present study indicate that different irrigation solution temperatures during implant surgery did not have a significant effect on RFA values of dental implants however, implants that applied with the lowest irrigation solution temperature had the highest RTV scores. The null hypothesis of the study was not confirmed according to present findings. Osseointegration is a complex process and many determinant have crucial role. In point of thermal trauma heat generation during drilling steps cannot be ignored and may affect the present findings, future studied needed which investigate both determinants.

Rabbit models are convenient for skeletal research studies, and have been extensively used to test the bone reaction to implant biomaterials.<sup>25</sup> Rabbit models provide a cost-effective animal model with maintenance and housing are simple and recovers well postoperatively. The literature reports similarities between rabbit and human bone composition and cortical tibia bone with similarities to the mandible.<sup>26</sup> Disadvantages also exist with rabbit models. One of them is the sample size, larger sample size is not possible due to ethical reasons which is the major limitation of the present study. The term of osseointegration always has been the first place in successful implant rehabilitation. The osseointegration may be evaluated in several ways. In the present study RFA and RTV were utilized. RFA is a non-invasive method for measuring implant stability.<sup>27</sup> RTV is an invasive, objective method with easy to administer. It has been said to be beneficial to identify of secondary stability, quality of bone-implant contact especially in the second stage of implant surgery.<sup>28</sup> In the present study, RTV was applied after 1 month of dental implant surgery, that mimics the term of second surgery of humans.<sup>29</sup>

Thermal trauma may cause osseonecrosis and directly effects the osseointegration process.<sup>30</sup>

More heat is generated in the superficial part of implant bed preparation area, owing to compact and spongy components of bone.<sup>31</sup> Therefore cooling the area and keep the temperature below critical threshold is essential to avoid thermal necrosis.<sup>6</sup> Cooling the implant bed preparation area with an irrigation solution is the most common technique to overcome detrimental effects of thermal trauma and the saline is the first choice as an irrigation solution.<sup>32</sup> It has been widely accepted that external cooling systems effectively prevent excessive heat generation which had been used in present study. Different determinants may be contribute in the effect of irrigation solution on thermal trauma.<sup>16-22,24</sup> However there is limited information in literature, regarding the impact of irrigation solution temperature on current issue.<sup>24,33</sup> An interesting study pointed out the effect of irrigation solution temperature on heat control.<sup>24</sup> In that *in-vitro* study, the authors measured the bone temperature without irrigation, and with irrigation using saline at 25° and 10°C and concluded that lower temperature saline was more effective in cooling the bone.<sup>24</sup> The findings of the present study were in concurrence with Sener *et al.*<sup>24</sup>, irrigation solutions with different temperatures that included the study were able to cool the bone adequately so the proper osseointegration was achieved. Regardless of the proper osseointegration and ISQ values, implants performed by 1°C irrigation solution temperature had statistically higher RTV scores, which demonstrate secondary stability values, compared with the implants applied with 10°C and 37°C irrigation solution temperature. Even though the cooling was enough to establish osseointegration, there may be an optimum temperature range to achieve better RTV scores. Biological variables of osseointegration may be the potential explanation on this issue. Osteoblast, alkaline phosphatase (ALP) activity, osteogenic and angiogenic markers have an undeniable effects to establish an osseointegration.<sup>34</sup> To avoid the excessive thermal increase which is warranted for proper dental implant healing 47°C reported as a threshold for osseonecrosis<sup>6</sup>, however some reports noted that limited hyperthermia during implant surgeries which below the threshold of 47°C enabled an optimal field which promotes the



osseogenesis by increasing human mesenchymal stem cell (hMSC) mineralization, ALP activity and led to induction of angiogenesis.<sup>35</sup> The results of the present study support these findings.

In present study, dental implants which were applied had surfacetreated based on SLA technique with nano layer of Ca incorporated. Implant surface also is an important key factor for proper osseointegration<sup>36</sup>, and it is still unclear how surface characteristic would response thermal trauma, future studies which biochemical and mechanical properties of osseointegration subjected together with larger sample size included to identify optimal thermal range during implant surgery and to achieve better primary and secondary stability scores in healing and maintenance phases for the long term success of dental implant treatment are warranted.

## CONCLUSIONS

Within the limitation of the study, in rabbit models, different irrigation solution temperatures during implant surgery did not have a direct effect on the primary and secondary stability values of dental implants.

## ACKNOWLEDGEMENT

This investigation was supported by the Cumhuriyet University Scientific Research Project (Project Number: DİŞ-168).The authors would like to extend sincere thanks to Assist. Prof. Ziyet CINAR from Department of Biostatistics, Faculty of Medicine Cumhuriyet University, Sivas, Turkey, for the help of statistical analysis.

## CONFLICT OF INTEREST STATEMENT

No potential conflict of interest relevant to this article was reported.

### *İrrigasyon Solüsyon Sıcaklıklarının Dental*

### *İmplantların Osseointegrasyonu Üzerine Olan Etkisi* **ÖZ**

**Amaç:** İmplant cerrahisi sırasındaki termal travma, iyileşme sürecini sınırlar. Bu çalışmanın amacı, implant cerrahisi sırasında kullanılan farklı sıcaklıktaki irrigasyon solüsyonlarının, dental implantların osseointegrasyonu üzerine olan etkisini araştırmaktır.

**Gereç ve Yöntemler:** Bu çalışmada sekiz yetişkin erkek Yeni Zelanda beyaz tavşanı kullanıldı. Tavşanların tibialarına toplam 32 implant yerleştirildi. Tavşanlar,

uygulanan farklı sıcaklıktaki irrigasyon solüsyonlarına göre (37 °C, 24 °C, 10 °C ve 1 °C) rastgele gruplara ayrıldı. Rezonans frekans analizi (RFA) implant cerrahi uygulamasından hemen sonra ve cerrahiye takip eden; 1. hafta, 2. hafta, 3. hafta ve 1. ayın sonunda yapıldı. İmplant cerrahisinden 30 gün sonra, sakrifiye edilen tavşanların tibialarına yerleştirilen implantların, çıkarma torku değerleri (RTV'ler) ölçüldü ve uygun istatistiksel yöntemlerle değerlendirme yapıldı. **Bulgular:** Çalışmada uygulanan implantların, implant stabilite katsayısında (ISQ) İlk ölçümden 5. ölçüme kadar gruplar arasında anlamlı bir fark bulunmadı. Bununla birlikte, RTV'lerde 1 °C ile 37 °C ve 1 °C ile 10 °C arasında istatistiksel olarak anlamlı bir fark tespit edildi. (p=0,024 ve p=0,013, sırasıyla). **Sonuçlar:** Tavşan modellerinde, implant cerrahisi sırasında kullanılan farklı sıcaklıktaki irrigasyon solüsyonları, dental implantların primer ve sekonder stabilite değerlerini etkilememiştir. **Anahtar Kelimeler:** Dental implant, osseointegrasyon, travma, tavşan modeli.

## REFERENCES

1. Albrektsson T, Lekholm U. Osseointegration: current state of the art. Dent Clin North Am1989;33:537-554.
2. Sutter F, Krekeler G, Schwammberger AE, Sutter FJ. Atraumatic surgical technique and implant bed preparation. Quintessence Int 1992;23:811-816.
3. Flanagan D. Heat generated during seating of dental implant fixtures. J Oral Implantol 2014;40:174-181
4. Scarano A, Piattelli A, Assenza B, Carinci F, Di Donato L, Romani GL, Merla A. Infrared thermographic evaluation of temperature modifications induced during implant site preparation with cylindrical versus conical drills. Clin Implant Dent Relat Res2011;13:319-323.
5. Carvalho AC, Queiroz TP, Okamoto R, Margonar R, Garcia IR Jr, Magro Filho O. Evaluation of bone heating, immediate bone cell viability, and wear of high-resistance drills after the creation of implant osteotomies in rabbit tibias. Int J Oral Maxillofac Implants2011; 26:1193-1201.
6. Eriksson RA, Albrektsson T. The effect of heat on bone regeneration: an experimental study in the rabbit using the bone growth chamber. J Oral Maxillofac Surg1984;42: 705-711.
7. Tehemar SH. Factors affecting heat generation during implant site preparation: a review of biologic observations and future considerations. Int J Oral Maxillofac Implants 1999;14:127-136.

8. Yoshida K, Uoshima K, Oda K, Maeda T. Influence of heat stress to matrix on bone formation. *Clin Oral Implants Res* 2009;20:782-790.
9. Strbac GD, Giannis K, Unger E, Mittlböck M, Vasak C, Watzek G, Zechner W. Drilling and withdrawing related thermal changes during implant site osteotomies. *Clin Implant Dent Relat Res* 2015;17:32-43.
10. Kim SJ, Yoo J, Kim YS, Shin SW. Temperature change in pig rib bone during implant site preparation by low-speed drilling. *J Appl Oral Sci* 2010;18:522-527.
11. Kondo S, Okada Y, Iseki H, Hori T, Takakura K, Kobayashi A, Nagata H. Thermological study of drilling bone tissue with a high-speed drill. *Neurosurg* 2000;46:1162-1168.
12. Hochscheidt CJ, Shimizu RH, Andrighetto AR, Moura LM, Golin AL, Hochscheidt RC. Thermal variation during osteotomy with different dental implant drills: a standardized study in bovine ribs. *Implant Dent* 2017;26:73-79.
13. El-Kholy KE, Ramasamy S, Kumar RS, Elkomy A. Effect of simplifying drilling technique on heat generation during osteotomy preparation for dental implant. *Implant Dent* 2017;26:888-891.
14. El-Kholy KE, Elkomy A. Effect of the drilling technique on heat generation during osteotomy preparation for wide diameter implants. *Implant Dent* 2016;25:825-828.
15. Trisi P, Berardini M, Falco A, Vulpiani MP. Effect of temperature on the dental implant osseointegration development in low-density bone: an in vivo histological evaluation. *Implant Dent* 2015;24:96-100.
16. Gehrke SA, Aramburú Júnior JS, Pérez-Albacete Martínez C, Ramirez Fernandez MP, Maté Sánchez de Val JE, Calvo-Guirado JL. The influence of drill length and irrigation system on heat production during osteotomy preparation for dental implants: an ex vivo study. *Clin Oral Implants Res* 2018;29:772-778.
17. Strbac GD, Giannis K, Unger E, Mittlböck M, Watzek G, Zechner W. A novel standardized bone model for thermal evaluation of bone osteotomies with various irrigation methods. *Clin Oral Implants Res* 2014;25:622-631.
18. Gehrke SA, Loffredo NH, Mardegan FE. Investigation of the effect of movement and irrigation systems on temperature in the conventional drilling of cortical bone. *Br J Oral Maxillofac Surg* 2013;51:953-957.
19. Gehrke SA, Pazetto MK, de Oliveira S, Corbella S, Taschieri S, Mardegan FE. Study of temperature variation in cortical bone during osteotomies with trephine drills. *Clin Oral Investig* 2014;18:1749-1755.
20. Benington IC, Biagioni PA, Briggs J, Sheridan S, Lamey PJ. Thermal changes observed at implant sites during internal and external irrigation. *Clin Oral Implants Res* 2002;13:293-297.
21. Sindel A, Dereci Ö, Hatipoğlu M, Altay MA, Özalp Ö, Öztürk A. The effects of irrigation volume to the heat generation during implant surgery. *Med Oral Patol Oral Cir Bucal* 2017;22:506-511.
22. Rashad A, Kaiser A, Prochnow N, Schmitz I, Hoffmann E, Maurer P. Heat production during different ultrasonic and conventional osteotomy preparations for dental implants. *Clin Oral Implants Res* 2011;22:1361-1365.
23. Sannino G, Gherlone EF. Thermal changes during guided flapless implant site preparation: a comparative study. *Int J Oral Maxillofac Implants* 2018;33:671-677.
24. Sener BC, Dergin G, Gursoy B, Kelesoglu E, Slih I. Effects of irrigation temperature on heat control in vitro at different drilling depths. *Clin Oral Implants Res* 2009;20:294-298.
25. Pearce AI, Richards RG, Milz S, Schneider E, Pearce SG. Animal models for implant biomaterial research in bone: a review. *Eur Cell Mater* 2007;13:1-10.
26. Sul YT, Johansson CB, Albrektsson T. Oxidized titanium screws coated with calcium ions and their performance in rabbit bone. *Int J Oral Maxillofac Implants* 2002;17:625-634.
27. Meredith N, Shagaldi F, Alleyne D, Sennerby L, Cawley P. The application of resonance frequency measurements to study the stability of titanium implants during healing in the rabbit tibia. *Clin Oral Implants Res* 1997;8:234-243.
28. Trisi P, Berardini M, Falco A, Podaliri Vulpiani M. Validation of value of actual micromotion as a direct measure of implant micromobility after healing (secondary implant stability). An in vivo histologic and biomechanical study. *Clin Oral Implants Res* 2016;27:1423-1430.
29. Trindade, R, Albrektsson T, Galli S, Prgomet Z, Tengvall P, Wennerberg A. Osseointegration and foreign body reaction: Titanium implants activate the immune system and suppress bone resorption during the first 4 weeks after implantation. *Clin Implant Dent Relat Res* 2018;20:82-91.

- 30.** Möhlhenrich SC, Modabber A, Steiner T, Mitchell DA, Hölzle F. Heat generation and drill wear during dental implant site preparation: systematic review. *Br J Oral Maxillofac Surg* 2015;53:679-689.
- 31.** Möhlhenrich SC, Abouridouane M, Heussen N, Modabber A, Klocke F, Hölzle F. Influence of bone density and implant drill diameter on the resulting axial force and temperature development in implant burs and artificial bone: an in vitro study. *Oral Maxillofac Surg* 2016;20:135-142.
- 32.** Shah FA, Thomsen P, Palmquist A. A review of the impact of implant biomaterials on osteocytes. *J Dent Res* 2018;97:977-986.
- 33.** Barrak I, Boa K, Joób-Fancsaly Á, Varga E, Sculean A, Piffko J. Heat Generation During Guided and Freehand Implant Site Preparation at Drilling Speeds of 1500 and 2000 RPM at Different Irrigation Temperatures: An In Vitro Study. *Oral Health Prev Dent* 2019; 9:1-8
- 34.** Ota T, Nishida Y, Ikuta K, Kato R, Kozawa E, Hamada S, Sakai T, Ishiguro N. Heat-stimuli enhanced osteogenesis using clinically available biomaterials. *PLoS One* 2017;18:1-16.
- 35.** Chen E, Xue D, Zhang W, Lin F, Pan Z. Extracellular heat shock protein 70 promotes osteogenesis of human mesenchymal stem cells through activation of the ERK signaling pathway. *FEBS Lett* 2015;21:589:4088-4096.
- 36.** Albrektsson T, Wennerberg A. On Osseointegration in Relation to Implant Surfaces. *Clin Implant Dent Relat Res* 2019;21:4-7.



## THE RELATIONSHIP BETWEEN THE MANDIBULAR BONE QUALITY ASSESSED BY DIGITAL PANORAMIC RADIOGRAPHY AND SERUM BIOLOGICAL PARAMETERS IN PATIENTS PLANNING DENTAL IMPLANT SURGERY

### ABSTRACT


**Objectives:** The aim of this study was to evaluate the bone density of the implant site with panoramic radiomorphometric parameters [mandibular cortical index (MCI), mental index (MI)], and to investigate the relationships between bone density, vitamin D, HDL, and LDL.

**Materials and Methods:** Forty patients with mandibular first molar or second molar tooth deficiency who had undergone implant surgery were included in the study. Blood samples and panoramic MCI and MI parameters were used to evaluate mandibular bone density. Data were analyzed using the Mann-Whitney U and Kruskal-Wallis tests. The relationships between MI and the study variables were assessed by Spearman's correlation coefficient. The Chi-square or Fisher's exact tests were used to determine the relationships between MCI and the study variables.  $p < 0.05$  was considered statistically significant.


**Results:** There were significant weak positive correlations of MI with Vitamin D and LDL ( $r = 0.329$ ,  $p = 0.038$ ;  $r = 0.341$ ,  $p = 0.031$ ). Vitamin D, LDL, and HDL measurements were not statistically different among the MCI groups ( $p=0.100$ ,  $p=0.119$ ,  $p=0.840$ , respectively).

**Conclusions:** Vitamin D level may carry importance in addition to radiographic and clinical parameters; thus, patients should be evaluated in this respect. Further studies involving larger patient groups are needed to conclude the relationship between vitamin D level and bone quality.

**Keywords:** Dental implant, bone remodeling, Vitamin D, HDL cholesterol, LDL cholesterol.

 Kaan ORHAN<sup>1</sup>

 Mehmet Özgür ÖZEMRE<sup>1</sup>

 \*Mediha Nur NİŞANCI YILMAZ<sup>2</sup>

 Cansu KÖSEOĞLU SEÇGİN<sup>1</sup>

 Şule BULUT<sup>2</sup>

ORCID IDs of the authors:

K.O. 0000-0003-1686-4746

M.Ö.Ö. 0000-0001-5863-6990

M.N.N.Y. 0000-0002-6410-2060

C.K.S. 0000-0002-7896-1165

Ş.B. 0000-0002-8808-0185

<sup>1</sup> Department of Dentomaxillofacial Radiology, Faculty of Dentistry, Baskent University, Ankara, Turkey

<sup>2</sup> Department of Periodontology, Başkent University Faculty of Dentistry, Ankara, Turkey

Received : 23.01.2020

Accepted : 27.02.2020

## **INTRODUCTION**

Dental implant surgeries are the most common treatments in patients with missing teeth. The quality or density of the available bone is the most critical factor for success in implant surgeries. The bone density in the toothless region, treatment planning, the structure of the implant, surgical approach, healing time, and loading are the criteria that affect the loading process during the prosthetic stage. The alveolar bone structure of the implant drilling site defines the success of anchored endosseous implants. In the presence of a toothless crest, dense or porous cortical bone can be found on the outer surface of the bone, and sometimes the trabecular bone inside the cortical bone, whether the crest is thick or thin. While the cortical bone has the function of withstanding torsional loading and provides higher initial stability, cancellous bone is more abundant in vascular canals and thus, vasculature supplying mesenchymal progenitor cells. Therefore, it is essential to evaluate the bone quality and quantity in potential implant sites.<sup>1</sup> Accurate evaluation of the bone structure and planning of surgery before placement of the implant affect the success and survival rates of the implant.<sup>2</sup> Mandibular radiomorphometric parameters such as the Mandibular Cortical Index (MCI) and the Mental Index (MI) are used to evaluate the bone quality of the mandible.<sup>3,4</sup>

MCI classifies the visibility of the cortical bone at the lower edge of the mandible. MI is the amount of cortical bone thickness measured at the mental foramen region.<sup>5</sup> Although different reference ranges have been reported in various studies, it has been concluded that asymptomatic dental patients with an MI < 3 mm without osteoporosis might be referred for bone mineral density measurement and must be evaluated for osteoporosis risk.<sup>6</sup> These indices play critical roles in the identification and evaluation of patients with osteoporosis or low mineral density.<sup>5,7</sup> Qualitative and quantitative panoramic indices, including MCI, MI, and PMI (Panoramic Mandibular Index), are the measurements developed in order to evaluate the quality and quantity of mandibular bone density on panoramic radiographs and to identify the resorption points. MI is the best predictor of

reduced cortex width under the two mental foramina. Osteopenia can be defined by measuring the cortical thickness at the lower border of the mandible. Thin mandibular cortical width is a finding that shows reduced skeletal bone mineral density (BMD).<sup>7</sup> MCI shows the porosity of the mandible but is also associated with BMD.<sup>8</sup> MCI has been found to be useful in demonstrating osteoporosis.

One of the hypotheses of failure after implant or graft applications in recent years is the presence of underlying biological disorders affecting bone metabolism. There is evidence that LDL (low-density lipoprotein) cholesterol (dyslipidemia) slows bone metabolism or reduces the osseointegration of dental implants. It is also known that Vitamin D is the key to natural and acquired immunity and that both immunities are impaired in vitamin D deficiency. Therefore, vitamin D deficiency slows the osseointegration of the implant or increases the risk of graft infection.<sup>9,10</sup>

Today, the use of dental implants for rehabilitation of missing teeth is increasing day by day. In this parallel, complications of peri-implant tissues and implant failures have become more common. The most important criteria for implant success are the quantity and quality of the available bone. Therefore, it is crucial to evaluate factors that may negatively affect the density, quantity, quality, or metabolism of the bone before the procedure. In the present study, we evaluated the radiographic and biochemical parameters and posterior bone structure of patients who were planned to undergo implant surgery, and we think that this can help to prevent further possible complications. The aim of the study was to evaluate the bone density of the implant site with panoramic radiomorphometric indices and to investigate the relationships between bone density and biochemical parameters.

## **MATERIALS AND METHODS**

The study was conducted on patients aged 18-49 years who had undergone mandibular molar region implant surgery in the Department of Dentomaxillofacial Radiology of Baskent University Faculty of Dentistry. MCI and MI indexes were measured by three radiologists on digital panoramic radiographs. The study protocol

was conducted in full accordance with the Helsinki Declaration and was approved by Baskent University Institutional Review Board and Ethics Committee (Project no: D-KA18/21). Written informed consent was obtained from all subjects.

Panoramic radiographs were taken with the same device (Veraviewpocs 2D, Morita, Japan) and with the same technical parameters (64–66 kVp; 6–9 mA; 10 s and voxel size 0.08 mm<sup>3</sup>). Klemetti *et al.*<sup>7</sup> defined MCI as C1, C2, C3 according to the visibility of the mandibular cortical bone. Cortical bone thickness was measured at the site of mental foramen using Clearcanvas (Synaptive Medical, Toronto, Canada) program for MI. The standard magnification value of the panoramic device used in MI was 10%.

C1: Normal cortex, cortical bone on both sides regular and continuous,

C2: Moderately eroded cortex, half-moon defects, and stratification in cortical bone,

C3: Severely eroded cortex, extreme irregularity in cortical bone, and significant porosity. It was reported that the C3 category should be evaluated in terms of the risk of osteoporosis.<sup>6</sup>

LDL, HDL (high-density lipoprotein), and vitamin D levels in blood samples were obtained from patients who accepted implant surgery. In serum, the reference value for HDL cholesterol was between 35-55 mg/dL and for LDL cholesterol, <130 mg/dL. For 25-OH-cholecalciferol, reference value between 6.2-45.5 ng/mL was used.

Inclusion criteria for the study were as follows:

- 1) No drug or systemic disease affecting bone metabolism,
- 2) Missing teeth only in the first molar or second molar region of the mandible,
- 3) No periodontal disease,
- 4) No diagnosis of menopause.

### Statistical Analysis

Statistical analysis of the data was performed by SPSS (Version 22.0, SPSS Inc., Chicago, IL, USA). Descriptive statistics were presented with mean  $\pm$  standard deviation and median (min-max) for continuous variables in accordance with the data distribution. Categorical variables were expressed as numbers and percentages. The distribution of normality of data for statistical test selection was examined by the Shapiro-Wilk test. Since parametric test assumptions were not met, Mental Index (MI) values in sex and smoking groups and Vitamin D, LDL, and HDL measurements in Mandibular Cortical Index (MCI) groups were compared using the Mann-Whitney U test. Mental index (MI) values were compared with the Kruskal-Wallis test in the tooth-loss year groups. The relationships between MI and tooth-loss year, Vitamin D, HDL, and LDL were investigated with Spearman's correlation coefficient according to data distribution. The relationships between MCI and gender, smoking, tooth-loss year, LDL, and HDL were investigated by Chi-square or Fisher exact test. The statistical significance level was considered as  $p < 0.05$ .

### RESULTS

In the present study, there were 14 (35%) females and 26 (65%) males. The mean age of the patients was  $38.8 \pm 5.90$  (23-49) years. The mean age of females was  $36.93 \pm 7.10$  (23-48) years, and the mean age of males was  $39.81 \pm 5$  (29-49) years. The mean ages of male and female patient groups were not statistically different ( $p = 0.143$ ). Eighteen (45%) of the patients reported smoking, while 22 (55%) stated that they did not smoke. Smoking rates of men and women were similar according to gender groups ( $p = 0.257$ ). 57.1% ( $n = 8$ ) of females were smoking and 38.5% ( $n = 10$ ) of males were smoking. The average vitamin D level was found to be  $16.38 \pm 9.69$  ng / mL in the 40 subjects, whereas the average LDL value was  $129.5 \pm 47.91$  mg/dL, and the average HDL value was  $43.5 \pm 9.47$  mg /dL (Table 1).

**Table 1.** Mean Vitamin D, LDL, and HDL levels in study patients

Variables	N	Mean±SD	Median (min-max)
Vitamin D ng / mL	40	16.38±9.69	14.75 (7.1-44,9)
LDL mg / dL	40	129.52±47.91	129 (46-209)
HDL mg / dL	40	43.62±9.74	43.5 (19-63.6)

MCI, C1, and C2 ratios were similar in females and males (p = 0.641). There was no statistically significant difference between C1 and C2 rates of smoking groups (p = 0.064). There

was no significant difference between C1 and C2 ratios, according to the toothless period (p= 0.849) (Table 2).

**Table 2.** Comparison of Mandibular Cortical Index (MCI) by gender, smoking, and period of tooth loss

		MCI		Total N	P-value
		C1 N(%)	C2 N(%)		
Gender	Female	7 (50%)	7 (50%)	14	0.641 <sup>†</sup>
	Male	11 (42.3%)	15 (57.7%)	26	
Smoking	No-smoking	7 (31.8%)	15 (68.2%)	22	0.064 <sup>†</sup>
	Smoking	11 (61.1%)	7 (38.9%)	18	
Period of Tooth Loss	5 years and less	5 (38.5%)	8 (61.5%)	13	0.849 <sup>‡</sup>
	5-10 years	8 (47.1%)	9 (52.9%)	17	
	More than 10 years	5 (50%)	5 (50%)	10	

<sup>†</sup> Chi-square test, <sup>‡</sup> Fisher exact test

MI measurements according to demographic and clinical characteristics of the patients were shown in Table 3. The mean MI did not differ

significantly regarding gender, smoking, and the toothless period (p = 0.944, p = 0.946, p = 0.552, respectively).

**Table 3.** Comparison of Mental Index (MI) measurements according to demographic and clinical characteristics of patients

		N	MI		P value
			Mean±SD	Median (min-max)	
Gender	Female	14	5.29±0.72	5 (4-7)	0.944 <sup>¶</sup>
	Male	26	5.42±1.41	5 (4-10)	
Smoking	No-smoking	22	5.45±1.50	5 (4-10)	0.946 <sup>¶</sup>
	Smoking	18	5.28±0.75	5 (4-7)	
Tooth loss time	5 years or less	13	5.15±1.28	5 (4-7)	0.552 <sup>§</sup>
	5-10 years	17	5.65±1.41	5 (4-10)	
	More than 10 years	10	5.20±0.63	5 (4-6)	

<sup>¶</sup> Mann Whitney U test

<sup>§</sup> Kruskal-Wallis test

SD: Standart Deviation:

Vitamin D, LDL, and HDL measurements were not statistically different between the MCI

groups (p = 0.100, p = 0.119, p = 0.840, respectively) (Table 4).

**Table 4.** Comparison of Vitamin D, LDL, and HDL levels according to Mandibular Cortical Index (MCI) groups.

	MCI groups	N	Mean±SD	Median (min-max)	p value
Vit D	C1	18	13.61±6.87	10 (7-26)	0.100 <sup>¶</sup>
	C2	22	18.64±11.16	16 (7-45)	
LDL	C1	18	116.5±49.69	107.5 (46-209)	0.119 <sup>¶</sup>
	C2	22	140.23±44.69	141 (74-206)	
HDL	C1	18	42.78±11.52	43.5 (19-64)	0.840 <sup>¶</sup>
	C2	22	44.36±8.28	43.5 (33-60)	

<sup>¶</sup> Mann Whitney U test

SD: Standart deviation

Significant positive weak correlations of MI with VitaminD and LDL were determined to be

present( $r = 0.329$ ,  $p = 0.038$ ;  $r = 0.341$ ,  $p = 0.031$ ) (Table 5).

**Table 5.** Results of correlation analysis between Mental Index (MI) and VitD, HDL and LDL

		<b>VitD</b>	<b>LDL</b>	<b>HDL</b>
<b>MI</b>	R	<b>0.329*</b>	<b>0.341*</b>	0.063
	P	<b>0.038</b>	<b>0.031</b>	0.698
	N	<b>0.038</b>	40	40

\* Spearman's rho correlation statistically significant

## DISCUSSION

Vitamin D is a fat-soluble vitamin derived from endogenous production in the skin following exposure to adequate sunlight (cholecalciferol) or obtained through dietary means (ergocalciferol and cholecalciferol), then converted in the liver to 25-hydroxyvitamin D (25(OH) D). Thereafter, 25(OH)D is converted in the kidney to its active form 1,25-hydroxyvitamin D (1,25(OH)D).<sup>11</sup> Vitamin D is involved in the intestinal absorption and regulation of calcium homeostasis and is crucial for bone and overall health.<sup>12</sup> This vitamin can stimulate osteoblastic bone matrix production, coupling bone resorption to bone formation, and optimizing bone remodeling.<sup>13</sup> It increases calcium absorption in the intestine, leading to a reduction in PTH (parathyroid hormone) secretion and lowers systemic bone resorption with a possible inhibition of osteoclastogenesis. 1, 25-dihydroxyvitamin D<sub>3</sub> can stimulate bone resorption by binding to vitamin D receptors of osteoblasts and by altering the balance between RANKL and osteoprotegerin.<sup>14,15</sup> Although vitamin D has been widely used in the treatment and prevention of osteoporosis in recent years, studies investigating its effects on implant osseointegration are limited.<sup>9,16</sup>

In an animal experiment, Kelly *et al.*<sup>17</sup> observed low bone-implant connection (BIC) in rats with vitamin D deficiency two weeks after implant placement. However, the same study emphasized that the prevalence of vitamin D deficiency might vary in different populations. Recently, the effect of topical application of vitamin D (10%) and melatonin (5%) solutions on the surface of immediate implants placed in dogs was evaluated. Both topical applications improved new bone formation around implants significantly and reduced crestal bone loss at 12 weeks following surgery, indicating the positive correlation between vitamin D and early stages of

osseointegration.<sup>18</sup> Aydın *et al.*<sup>19</sup> reported a significant increase in the amount of vitamin D in propolis groups and stated that the healing of the implanted bone was improved.

A retrospective study with the purpose of investigating a correlation between early implant failure and low serum level of vitamin D showed a higher incidence of the implant failure rate in these patients, but a correlation between the two factors could not be determined.<sup>20</sup>

The results of the current study revealed that vitamin D level was below the threshold of 20 ng/mL in thirty individuals included in the study. The World Health Organization reported that the insufficiency of vitamin D could be considered in levels below 20 ng/mL (50 nmol/L), and the deficiency of vitamin D levels could be considered below 10 ng/mL (25 nmol/L).<sup>21,22</sup> We think that the probability of implant failure in these individuals may be higher in subsequent implant applications. These individuals may be offered vitamin D supplementation before implant surgery, and patients maybe needed to be kept under control for peri-implantitis following implant surgery.

The results showed that there was no relationship between MCI and vitamin D level, whereas there was a weak positive correlation between MI and vitamin D level. This result shows that the vitamin D level may affect bone metabolism and structure.

Animal experiments showed that there were more bone resorption and less bone formation, together with higher levels of bone turnover marker after high cholesterol diets.<sup>23,24</sup> During *et al.*<sup>23</sup> reported that fatty acids and high cholesterol levels may adversely affect the rate of bone formation / bone destruction by down-regulating the Wnt signaling pathway. Wnt pathway balances



mesenchymal cell differentiation by inhibiting adipogenesis and stimulating osteoblasts proliferation, maturation, and differentiation. Although the adverse effects of obesity and increased cholesterol and triglycerides are widely known in the medical field, the effect of hyperlipidemia on osseointegration of dental implants is not fully known.<sup>25</sup> In a study, it was reported decreased bone formation and poor bone-implant attachment after 12 weeks of a high-fat diet.<sup>24</sup> However, in a study conducted by Dündar *et al.*<sup>26</sup>, no change in the status of bone-implant connections after a 3-month high-fat diet was determined in post-implant 12-week evaluations in rabbits.

According to the results of the present study, there were no correlations between the MCI index, HDL, and LDL, whereas there was a weak positive correlation between MI and LDL. As mentioned in the literature, we think that hyperlipidemia may affect bone quality and density, but adverse effects may be speculated in implant osseointegration. In addition, meaningful results may be obtained in studies with more substantial-sized samples.

In this study, no significant relationship was found between the duration of tooth loss and radiomorphometric indices. This can be explained by the presence of the natural teeth at the mesial and distal of the edentulous crest in the patients. In the literature, it has been reported that the presence of natural teeth, partial and total edentulism can be related to these indices.<sup>27</sup>

## CONCLUSIONS

Panoramic radiographs are frequently used before implant surgery. It was concluded that biomarkers such as Vitamin D might be relevant in addition to radiographic and clinical parameters, and patients should be evaluated in this respect.

In addition, the inverse relationship between plasma 25-OH D and serum PTH levels is very well known.<sup>28,29</sup> PTH plays a central role in calcium-phosphorus homeostasis. Thus, a combined evaluation of vitamin D and PTH levels may provide an accurate assessment. The limitation of the current study is the small sample size. However, vitamin D insufficiency was observed in

the majority of the patient group in the study, and the issue of whether vitamin D supplementation would be necessary before implant surgery was raised. Future studies are needed to evaluate vitamin D and PTH together and to evaluate the rate of peri-implantitis in patients with vitamin D deficiency after implant surgery.

## ACKNOWLEDGMENTS

This study was supported by Baskent University Research Fund.(Project no: D-KA18/21)

## CONFLICTS OF INTEREST STATEMENT

The author reports no conflicts of interest

### *Dental Implant Cerrahisi Planlanan Hastalarda Dijital Panoramik Radyografi ile Değerlendirilen Mandibular Kemik Kalitesi ile Serum Biyolojik Parametreler Arasındaki İlişki*

#### ÖZ

**Amaç:** Bu çalışmanın amacı, panoramik radyomorfometrik indeksler [mandibular kortikal indeks (MKI), mental indeks (MI)] kullanılarak implant bölgelerinde kemik densitesini değerlendirmek ve kemik densitesi ile D vitamini, HDL ve LDL arasındaki ilişkiyi incelemektir. **Gereç ve Yöntemler:** Çalışmaya mandibular birinci molar veya ikinci molar diş eksikliği olup implant cerrahisi planlanan 40 hasta dahil edilmiştir. Mandibular kemik dansitesini değerlendirmek için kan örnekleri ve panoramik MKI ve MI kullanılmıştır. Veriler Mann-Whitney U ve Kruskal-Wallis testleri kullanılarak analiz edildi. MI ve çalışma değişkenleri arasındaki ilişki Spearman korelasyon katsayısı ile değerlendirildi. MKI ve çalışma değişkenleri arasındaki ilişkiyi belirlemek için Ki-kare veya Fisher exact testleri kullanıldı. p değerinin <0,05 olması anlamlı kabul edildi. **Bulgular:** MI ile D vitamini ve LDL arasında anlamlı zayıf pozitif korelasyon bulunmuştur ( $r=0,329$ ,  $p=0,038$ ;  $r=0,341$ ,  $p=0,031$ ). MKI grupları arasında D vitamini, LDL ve HDL değerleri bakımından istatistiksel olarak fark bulunmamıştır (sırasıyla  $p=0,100$ ,  $p=0,119$ ,  $p=0,840$ ). **Sonuçlar:** D vitamini klinik ve radyolojik parametrelere ek olarak önemli bir faktör olabilmektedir ve hastalar bu açıdan değerlendirilmelidir. D vitamini ile kemik kalitesi arasındaki ilişkiyi araştıran daha çok sayıda hastanın dahil edildiği çalışmalara ihtiyaç vardır. **Anahtar Kelimeler:** diş implantları, kemiğin yeniden şekillendirilmesi, vitamin D, HDL kolesterol, LDL kolesterol.

## REFERENCES

1. Kohn DH. Overview of factors important in implant design. *J Oral Implantol* 1992; 18: 204-219.
2. Jemt T, Lekholm U. Implant treatment in edentulous maxillae: a 5-year follow-up report on patients with different degrees of jaw resorption. *Int J Oral Maxillofac Implants* 1995; 10: 303-311.
3. Zlataric DK, Celebic A. Clinical bone densitometric evaluation of the mandible in removable denture wearers dependent on the morphology of the mandibular cortex. *J Prosthet Dent* 2003; 90: 86-91.
4. Yeler DY, Koraltan M, Hocaoglu TP, Arslan C, Erselcan T, Yeler H. Bone quality and quantity measurement techniques in dentistry. *Cumhuriyet Dent J* 2016; 19: 73-86.
5. Taguchi A, Tsuda M, Ohtsuka M, Kodama I, Sanada M, Nakamoto T, et al. Use of dental panoramic radiographs in identifying younger postmenopausal women with osteoporosis. *Osteoporos Int* 2006; 17: 387-394.
6. Devlin H, Karayianni K, Mitsea A, Jacobs R, Lindh C, van der Stelt P, et al. Diagnosing osteoporosis by using dental panoramic radiographs: the OSTEODENT project. *Oral Surg Oral Med Oral Pathol Oral Radiol Endod* 2007; 104: 821-828.
7. Klemetti E, Kolmakov S, Kroger H. Pantomography in assessment of the osteoporosis risk group. *Scand J Dent Res* 1994; 102: 68-72.
8. Silverstein LH, Melkonian RW, Kurtzman D, Garnick JJ, Lefkove MD. Linear tomography in conjunction with pantomography in the assessment of dental implant recipient sites. *J Oral Implantol* 1994; 20: 111-117.
9. Xiong Y, Zhang Y, Guo Y, Yuan Y, Guo Q, Gong P, et al. 1alpha,25-Dihydroxyvitamin D3 increases implant osseointegration in diabetic mice partly through FoxO1 inactivation in osteoblasts. *Biochem Biophys Res Commun* 2017; 494: 626-633.
10. Insua A, Monje A, Wang HL, Miron RJ. Basis of bone metabolism around dental implants during osseointegration and peri-implant bone loss. *J Biomed Mater Res A* 2017; 105: 2075-2089.
11. Anand N, Chandrasekaran SC, Rajput NS. Vitamin D and periodontal health: Current concepts. *J Indian Soc Periodontol* 2013; 17: 302-308.
12. Vieth R. Vitamin D toxicity, policy, and science. *J Bone Miner Res* 2007; 22 Suppl 2: V64-68.
13. Kogawa M, Findlay DM, Anderson PH, Ormsby R, Vincent C, Morris HA, et al. Osteoclastic metabolism of 25(OH)-vitamin D3: a potential mechanism for optimization of bone resorption. *Endocrinology* 2010; 151: 4613-4625.
14. Leizaola-Cardesa IO, Aguilar-Salvatierra A, Gonzalez-Jaranay M, Moreu G, Sala-Romero MJ, Gomez-Moreno G. Bisphosphonates, vitamin D, parathyroid hormone, and osteonecrosis of the jaw. Could there be a missing link? *Med Oral Patol Oral Cir Bucal* 2016; 21: e236-240.
15. Christakos S, Lieben L, Masuyama R, Carmeliet G. Vitamin D endocrine system and the intestine. *Bonekey Rep* 2014; 3: 496.
16. Zhou C, Li Y, Wang X, Shui X, Hu J. 1,25Dihydroxy vitamin D(3) improves titanium implant osseointegration in osteoporotic rats. *Oral Surg Oral Med Oral Pathol Oral Radiol* 2012; 114: S174-178.
17. Kelly J, Lin A, Wang CJ, Park S, Nishimura I. Vitamin D and bone physiology: demonstration of vitamin D deficiency in an implant osseointegration rat model. *J Prosthodont* 2009; 18: 473-478.
18. Salomo-Coll O, de Mate-Sanchez JE, Ramirez-Fernandez MP, Hernandez-Alfaro F, Gargallo-Albiol J, Calvo-Guirado JL. Osseoinductive elements around immediate implants for better osteointegration: a pilot study in foxhound dogs. *Clin Oral Implants Res* 2018; 29: 1061-1069.
19. Aydin E, Hepokur C, Misir S, Yeler H. Effects Of Propolis On Oxidative Stress In Rabbits Undergoing Implant Surgery *Cumhuriyet Dent J* 2018;21: 136-144.
20. Mangano F, Mortellaro C, Mangano N, Mangano C. Is Low Serum Vitamin D Associated with Early Dental Implant Failure? A Retrospective Evaluation on 1625 Implants Placed in 822 Patients. *Mediators Inflamm* 2016; 2016: 5319718.

- 21.** Kennel KA, Drake MT, Hurley DL. Vitamin D deficiency in adults: when to test and how to treat. *Mayo Clin Proc* 2010; 85: 752-7; quiz 7-8.
- 22.** Spiro A, Buttriss JL. Vitamin D: An overview of vitamin D status and intake in Europe. *Nutr Bull* 2014; 39: 322-350.
- 23.** During A, Penel G, Hardouin P. Understanding the local actions of lipids in bone physiology. *Prog Lipid Res* 2015; 59: 126-146.
- 24.** Soares EA, Nakagaki WR, Garcia JA, Camilli JA. Effect of hyperlipidemia on femoral biomechanics and morphology in low-density lipoprotein receptor gene knockout mice. *J Bone Miner Metab* 2012; 30: 419-425.
- 25.** Keuroghlian A, Barroso AD, Kirikian G, Bezouglaia O, Tintut Y, Tetradis S, et al. The effects of hyperlipidemia on implant osseointegration in the mouse femur. *J Oral Implantol* 2015; 41: e7-e11.
- 26.** Dundar S, Yaman F, Ozupek MF, Saybak A, Gul M, Asutay F, et al. The effects of high-fat diet on implant osseointegration: an experimental study. *J Korean Assoc Oral Maxillofac Surg* 2016; 42: 187-192.
- 27.** Dutra V, Yang J, Devlin H, Susin C. Radiomorphometric indices and their relation to gender, age, and dental status. *Oral Surg Oral Med Oral Pathol Oral Radiol Endod* 2005; 99: 479-484.
- 28.** Dawson-Hughes B, Harris SS, Dallal GE. Plasma calcidiol, season, and serum parathyroid hormone concentrations in healthy elderly men and women. *Am J Clin Nutr* 1997; 65: 67-71.
- 29.** Chapuy MC, Preziosi P, Maamer M, Arnaud S, Galan P, Hercberg S, et al. Prevalence of vitamin D insufficiency in an adult normal population. *Osteoporos Int* 1997; 7: 439-443.








## TRAUMATIC ULCERATIVE GRANULOMA WITH STROMAL EOSINOPHILIA (TUGSE)-A PRECURSOR OF ORAL SQUAMOUS CELL CARCINOMA?

### ABSTRACT

Traumatic ulcerative granuloma with stromal eosinophilia (TUGSE) is a benign, chronic, reactive and self-healing lesion. It is composed of abundant eosinophils and small lymphocytes. Several studies have shown varying observations on the relation of tissue eosinophilia with the prognosis of oral cancer. Here, we present a case of a 65-year-old male who presented with a non-healing ulcer on the lateral border of the tongue, which was suggestive of TUGSE on histopathological examination. The patient was kept on strict monthly follow up and the second re-biopsy was suggestive of moderately differentiated squamous cell carcinoma. Literature does not support the transformation of TUGSE to oral squamous cell carcinoma; however, our experience suggests a close vigilance of such lesions due to its high clinical resemblance to malignancy. Hence, repeat biopsies on a regular basis are mandatory in cases where the clinical picture is highly suspicious.

**Keywords:** Oral cancer, squamous cell carcinoma, eosinophilia, tongue cancer, prognosis, lymph node.

 Mathangi KUMAR<sup>1</sup>  
 \*Ravindranath VINEETHA<sup>1</sup>  
 Keerthilatha M PAI<sup>1</sup>  
 Abhay T KAMATH<sup>2</sup>  
 Chetana CHANDRASHEKAR<sup>3</sup>

ORCID IDs of the authors:

M.K. 0000-0003-1245-2314  
R.V. 0000-0002-8932-9982  
K.M.P. 0000-0003-0967-5867  
A.K. 0000-0001-6412-3550  
C.C. 0000-0002-1061-0502

<sup>1</sup> Department of Oral Medicine&Radiology, Manipal College of Dental Sciences, Manipal, Manipal Academy of Higher Education, Manipal 576104, Karnataka, India.

<sup>2</sup> Department of Oral & Maxillofacial Surgery Manipal College of Dental Sciences, Manipal, Manipal Academy of Higher Education, Manipal 576104, Karnataka, India.

<sup>3</sup> Department of Oral & Maxillofacial Pathology, Manipal College of Dental Sciences, Manipal, Manipal Academy of Higher Education, Manipal 576104, Karnataka, India.

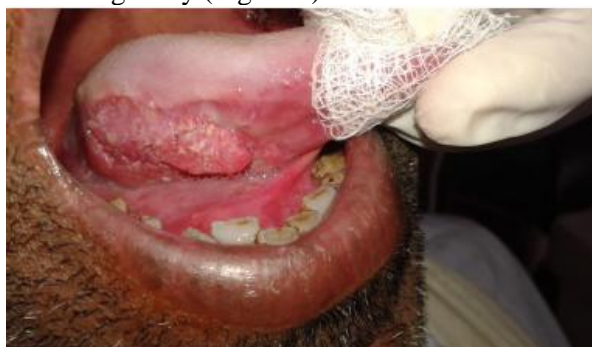Received : 20.11.2019  
Accepted : 13.02.2020

## INTRODUCTION

TUGSE is an uncommon, chronic reactive lesion affecting the oral cavity with a self-healing nature.<sup>1</sup> It occurs commonly on the tongue and trauma is a significant contributing factor. TUGSE manifests clinically as a solitary non-healing ulcer with raised and indurated margins. Because of this misleading clinical appearance, TUGSE is often misdiagnosed as oral malignancy.<sup>2</sup> However, microscopic features of TUGSE are definitive and comprise of dense, polymorphic inflammatory infiltrate of abundant eosinophils and lymphocytes with the absence of dysplastic tissue changes.<sup>3</sup> The advancing front of oral squamous cell carcinoma may also show eosinophilic infiltration and poses a diagnostic challenge for the pathologists. TUGSE is a benign condition and literature does not support its transformation to oral malignancy at any stage. However, our clinical experience with the present case cautions about the possibility of TUGSE being a precursor of oral squamous cell carcinoma. Here, we report the first-ever case of TUGSE, eventually turning into malignancy in a three-month duration.

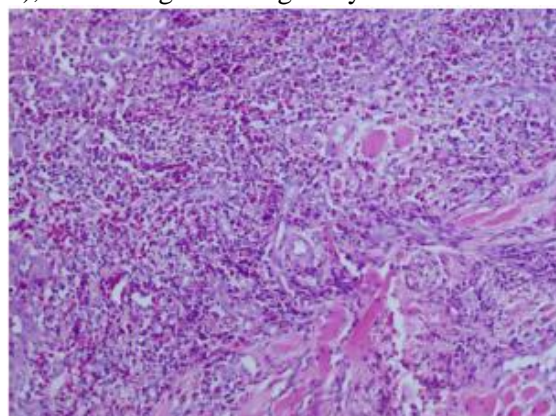
## CASE REPORT

A 65-year-old male presented to the Department of Oral Medicine and Radiology, Manipal College of Dental Sciences, Manipal, India, with a complaint of a non-healing ulcer on the tongue of one-month duration. The ulcer was associated with mild pain. Personal history revealed that he was a chronic smoker and had quit the habit for three months. On intraoral examination, there was an ulceroproliferative growth with irregular and indurated margins on the right lateral border of the tongue with the classic clinical appearance of oral malignancy (Figure 1).



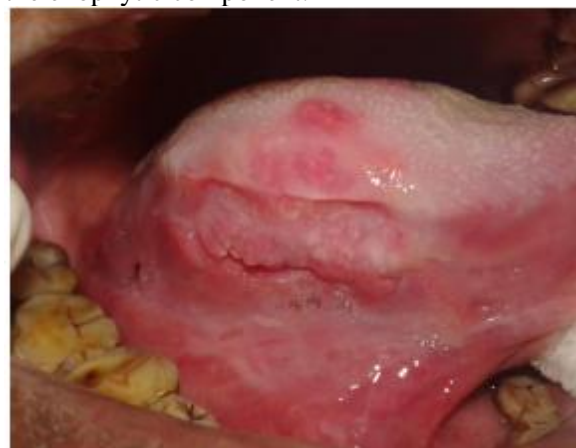**Figure 1.** Initial clinical presentation of the ulceroproliferative growth on the right lateral aspect of the tongue

There were no sharp cusps of teeth adjacent to the lesion. Signed informed patient's consent was obtained and an incisional biopsy of the tongue lesion was performed under local anaesthesia. Histopathological examination of the lesion showed para keratotic stratified squamous hyperplastic epithelium with ulceration along with few inflammatory cells. The stroma exhibited dense polymorphic inflammatory cell infiltrate with abundant eosinophils, lymphocytes and neutrophils. The inflammatory infiltrate was extending from the subepithelial stroma to the deeper stroma comprising of muscle tissue. Numerous vascular spaces lined by plump endothelial cells and nerve bundles were noted. These features were suggestive of TUGSE (Figure 2), thus ruling out malignancy.



**Figure 2.** Photomicrograph (hematoxylin and eosin staining, original magnification  $\times 100$ ) depicting tissue eosinophilia

As the clinical picture was not matching with the benign nature of the lesion as suggested by the histopathological report, we advised a repeat biopsy, which reconfirmed the diagnosis of TUGSE. The patient was kept on strict monthly follow up. The growth showed mild regression of the exophytic component.



**Figure 3.** Follow up photograph after 2 months showing regression in the size of the growth

Re-biopsy after one month again demonstrated tissue eosinophilia without malignant features. On a three-month follow-up, there was a sudden increase in the endophytic component of the lesion. This warranted a re-biopsy and histopathology demonstrated malignant changes suggestive of moderately differentiated squamous cell carcinoma. The patient underwent right partial glossectomy with radical neck dissection followed by post-surgical radiotherapy and is kept on three monthly follow up. This case portrays the gradual progression of TUGSE, a benign reactive lesion into an established oral squamous cell carcinoma.

## DISCUSSION

TUGSE is also known as eosinophilic ulcer, ulcerative eosinophilic granuloma and eosinophilic granuloma of soft tissue. It is a chronic, benign and reactive lesion with a self-limiting course.<sup>1</sup> The pathogenesis is unclear, with trauma being a significant contributing factor. It commonly presents as a solitary ulcer on the tongue with raised and indurated margins resembling oral squamous cell carcinoma (OSCC). OSCC usually occurs in males above 40 years of age, on the tongue and buccal mucosa followed by other intra-oral sites and is strongly associated with the use of tobacco (smoking and smokeless tobacco).<sup>4,5,6</sup>

Microscopically, TUGSE comprises of dense, polymorphic inflammatory infiltrate composed of abundant eosinophils and lymphocytes extending into the underlying muscle along with scattered large atypical histiocyte-like cells. The role of eosinophils is unclear and hypothesized that they could represent tissue response to some antigen introduced via mucosal injury.<sup>2</sup> A retrospective review by Hirshberg *et al.*<sup>7</sup> suggested that the lesion is self-healing with the duration ranging from several weeks to one year. Observations by Rahrotabanet *al.*<sup>8</sup> revealed the anti-tumour role of eosinophils with a positive correlation between the degree of tumour differentiation and tumour-associated tissue eosinophilia (poorly differentiated tumours had lesser tissue eosinophilia). Bankur *et al.*<sup>9</sup> performed a quantitative study on tumour-associated tissue eosinophils with various histological grades of oral squamous cell

carcinoma and suggested that tissue eosinophilia is higher in well-differentiated squamous cell carcinoma compared to other grades.

Jain S *et al.*<sup>10</sup> conducted a study on 35 patients with OSCC and examined the tumour as well as the lymph node status for tumour-associated tissue eosinophilia and found a weak positive correlation between mean eosinophils count in tumour and lymph nodes. Yellapurkar *et al.*<sup>11</sup> noted that haematoxylin and eosin staining of tissues showed significantly better visualization of eosinophils than Congo red staining and that tissue eosinophil counts were higher in cases of well-differentiated SCC with lymph node involvement and cases with no recurrence. Falconieri *et al.*<sup>12</sup> concluded that stromal invasion and metastatic lymph nodes were noted in all cases of eosinophil-rich OSCC.

Several studies have shown varying observations on the relation of tissue eosinophilia with the prognosis of oral cancer. Lowe *et al.*<sup>13</sup> suggested that tumour associated tissue eosinophilia alone has a better prognosis than those without, while tumour-associated blood eosinophilia is associated with tumour spread and a poor prognosis. A study by Dorta *et al.*<sup>14</sup> suggested that an independent favourable prognostic factor for oral cancer was intense Tumour Associated Tissue Eosinophilia (TATE). Whereas, Rakesh *et al.*<sup>15</sup> noticed a significant association between intense tissue eosinophilia and locoregional recurrence.

## CONCLUSIONS

Literature does not support the transformation of TUGSE to oral squamous cell carcinoma; however, our experience suggests a close vigilance of such lesions due to its high clinical resemblance to malignancy. Hence, repeat biopsies on a regular basis are mandatory in cases where the clinical picture is highly suspicious.

## ACKNOWLEDGMENTS

None

## CONFLICT OF INTEREST

No conflicts of interest to disclose

## REFERENCES

1. Soyele O, Adesina O, Ladeji A, Kuye K, Owotade F. Traumatic ulcerative granuloma with stromal

- eosinophilia: Review of the literature and case report. *Afr J Med Health Sci* 2017;16:115-159.
2. Medicum C. Ulcerative Granuloma With Stromal Case Report and Short Literature Review. *POL J Pathol* 2011;172-175.
  3. Sharma B, Koshy G, Kapoor S. Traumatic ulcerative granuloma with stromal eosinophila: A case report and review of pathogenesis. *J Clin Diagnostic Res* 2016;10:ZD07-09.
  4. Buch SA, Babu SG, Rao S. Indiscriminate use of smokeless tobacco leading to oral cancer at a young age; a case report with literature review on tobacco consumption. *Cumhuriyet Dent J* 2019;22:477-480.
  5. Bagherpour A, Mehr MT, Khajehahmadi S, Afzalinassab S. Maxillary sinus squamous cell carcinoma during pregnancy: A new case report. *Cumhuriyet Dent J* 2015;18:364-369.
  6. Özeç İ, Taşveren S, Yeler D, Kiliç E. Evaluation of the prevalence of oral mucosal lesions in people aged over 40 in SIVAS. *Cumhuriyet Dent J* 2008;11:10-15.
  7. Hirshberg A, Amariglio N, Akrish S, Yahalom R, Rosenbaum H, Okon E, et al. Traumatic ulcerative granuloma with stromal eosinophilia: A reactive lesion of the oral mucosa. *Am J Clin Pathol* 2006;126:522-529.
  8. Saravani S, Kadeh H, Derakhshanfar G. Tumor-Associated Tissue Eosinophilia in Squamous Cell Carcinoma of Head and Neck. *Dent Clin Exp J* 2016;90-94.
  9. Bankur R, Rodrigues C, Anjaly D, Gopinathan P, Bankur P. Quantitative analysis of tumor-associated tissue eosinophilia in different histological grades of oral squamous cell carcinoma. *Indian J Dent Res* 2016;27:463.
  10. Jain M, Kasetty S, Khan S, Jain NK. Tissue eosinophilia in head and neck squamous neoplasia: An update. *Exp Oncol* 2014;36:157-161.
  11. Yellapurkar S, Natarajan S, Boaz K, Baliga M, Shetty P, Manaktala N, et al. Tumour-associated tissue eosinophilia in oral squamous cell carcinoma- A boon or a bane? *J Clin Diagnostic Res* 2016;10:ZC65-68.
  12. Falconieri G, Luna MA, Pizzolitto S, DeMaglio G, Angione V, Rocco M. Eosinophil-rich squamous carcinoma of the oral cavity: a study of 13 cases and delineation of a possible new microscopic entity. *Ann Diagn Pathol* 2008;12:322-327.
  13. Lowe D, Jorizzo J, Hutt MSR. Tumour-associated eosinophilia: A review. *J Clin Pathol* 1981;34:1343-1348.
  14. Landman G, Lauris JRP, Kowalski LP, Latorre MRDO, Oliveira DT, Dorta RG. Tumour-associated tissue eosinophilia as a prognostic factor in oral squamous cell carcinomas. *Histopathology* 2003; 41:152-157.
  15. Rakesh N, Devi Y, Majumdar K, Reddy SS, Agarwal K. Tumour associated tissue eosinophilia as a predictor of locoregional recurrence in oral squamous cell carcinoma. *J Clin Exp Dent* 2015;7:e1-6.









## UNUSUAL APPEARANCE OF MULTIPLE EXOSTOSIS: CASE REPORT

**ABSTRACT**

Unilateral mandibular bone exostosis located in the buccal region is a rare condition. A 25-year-old female who presented with unilateral mandibular bone exostosis had her clinical diagnosis confirmed using cone beam computed tomography. Additionally, a nodular torus palatinus was found in the midline of the palate. Wear faces on the vestibular cusps of 46 as well as thickening of the periodontal ligament space were present. Both are signs of occlusal trauma. The presence of mandibular tori could indicate other underlying conditions, such as the presence of parafunctional activity or systemic health conditions. Mandibular exostosis can remain for life without the need to be surgically removed unless it compromises prosthetic rehabilitation.

**Key Words:** Exostosis, torus palatinus, torus mandibularis, case report.

 Livia Sonia ZAMBRANO-DE LA PEÑA<sup>1</sup>  
 David ARISTIZABAL<sup>2</sup>  
 Luis E Arriola-GUILLÉN<sup>2,3</sup>  
 Yalil Rodríguez-CÁRDENAS<sup>4</sup>  
 Aron Aliaga-Del CASTILLO<sup>5</sup>  
 \*Maria Eugenia GUERRERO<sup>1</sup>

ORCID IDs of the authors:

L.S.Z.D.P. 0000-0002-2510-6069  
 D.A. 0000-0001-6116-1113  
 L.A.G. 0000-0003-0010-5948  
 Y.R.C. 0000-0002-3107-3013  
 A.A.C. 0000-0003-3963-1742  
 M.E.G. 0000-0001-5425-870X

<sup>1</sup> Division of Oral and Maxillofacial Radiology, School of Dentistry, Universidad Científica del Sur, Lima, Perú.

<sup>2</sup> Medico Surgical Department, Faculty of Dentistry, Universidad Nacional Mayor de San Marcos, Lima, Peru.

<sup>3</sup> Department of Orthodontics, Bauru Dental School, University of São Paulo, Bauru, Brazil.

<sup>4</sup> Division of Orthodontics and Division of Oral and Maxillofacial Radiology, School of Dentistry, Universidad Científica del Sur, Lima, Perú.

<sup>5</sup> Department of Orthodontics, Bauru Dental School, University of São Paulo, Bauru, Brazil.

**Received** : 11.12.2019  
**Accepted** : 06.02.2020



## INTRODUCTION

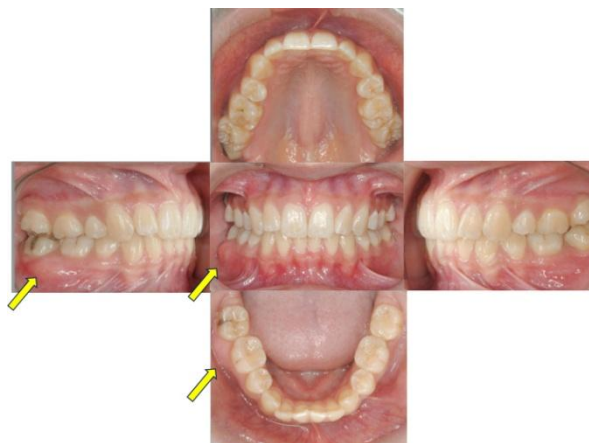
Intraoral exostosis is an abnormal growth of the bone tissue of a benign nature. The mechanism of its development is still unknown, and several related factors have been reported, such as hereditary conditions, excessive occlusal function and/or parafunctional activity, some systemic conditions, sex and age.<sup>1,2</sup>

Usually, the torus palatinus is located in the midline of the palate. Most mandibular tori cases are bilateral and are located in the lingual surface of the premolar region.<sup>3</sup> The growth of mandibular tori is very slow and variable, and in most cases, bilateral tori are present. Mandibular tori can also present with different sizes and shapes such as flat, spindle, nodular and lobular excrescences.<sup>4</sup>

This article describes the clinical case of a unilateral mandibular bone exostosis of a nodular shape located in the vestibular area of the mandibular first and second right molars in a young patient who also presented a torus palatinus.

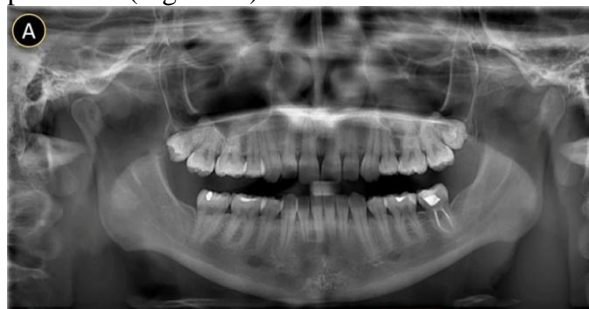## CASE REPORT

A 25-year-old female patient with a medical history of hyperthyroidism and orthodontic and myofunctional treatments visited the dental clinic. The patient had a family history of torus palatinus. During the routine clinical evaluation, two nodular protuberances of hard consistency were observed along the midline of the palate and in the vestibular area of right mandibular first and second molars (teeth 46 and 47, respectively). The oral examination revealed an asymptomatic consistent nodular protuberance in the vestibular region of teeth 46 and 47, with a thin yellowish-white soft tissue. Wear faces were observed in the vestibular cusps of 46. (Figure 1) In addition, the patient presented lateral deviation of the mandible towards the right side during buccal opening and a habit of biting her right cheek.



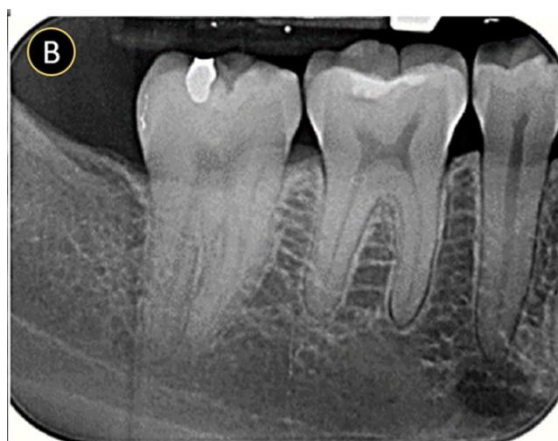**Figure 1.** Intraoral photos showing a nodular protuberance in the midline of the hard palate and in the vestibular region of teeth 46 and 47, wear faces are observed in vestibular cusps of the first molar.

The panoramic radiograph showed a radiopaque area with well-defined borders and diffuse edges, projected over the apex of the maxillary central incisors, compatible with torus palatinus. (Figure 2a)



**Figure 2a.** Panoramic radiography showing a radiopaque area with well-defined borders and diffuse edges, projected over the apex of the maxillary central incisors, compatible with torus palatinus.

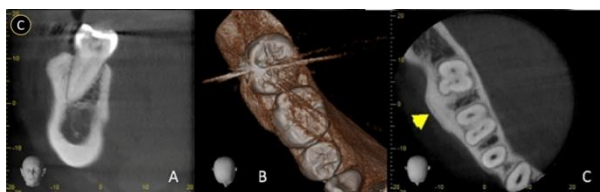
Digital periapical radiography showed superficial occlusal fillings on teeth 46 and 47 with a slight widening of the periodontal ligament space in the mesial root of tooth 46. (Figure 2b)



**Figure 2b.** Periapical radiograph confirming an increase in density below the periapical area of 46.

A slightly greater radiodensity was present compared to the circumscribed bone, and bone trabeculation had a normal morphology and density.

Cone-beam computed tomography was requested for a three-dimensional evaluation and was performed with J Morita Veraviewepocs 3D Equipment (J. Morita MFG. Corp., Kyoto, Japan) with a FOV of 40x40 mm, 80 kV and 6 mA. A hyperdense, homogeneous and rounded area with a regular edge was observed. The cortical bone along teeth 46 and 47 was thickened when observed on the axial and coronal views (Figure 2c).



**Figure 2c.** Right: Coronal view showing a buccal hyperdense structure on the cortical bone. Middle: 3D reconstruction of the region showing a homogeneous area with regular edges. Left: Axial view showing the increased thickness of the cortical bone along the vestibular region of the parts of 46 and 47 compatible with bone exostosis.

This appearance was compatible with bone exostosis. Since the patient was asymptomatic, no surgical intervention was required.

## DISCUSSION

The presence of an exostosis usually goes unnoticed by the patient and is diagnosed as an incidental finding. Exostosis could occasionally present complications during the evolution of some oral pathologies. Additionally, the thin oral mucosa that covers the underlying bone could have some lacerations after contact with a hard structure. Unilateral mandibular exostosis located in the vestibular region, as observed in the present case report, is not common since this growth usually occurs in the lingual area and has a bilateral presentation.<sup>5</sup>

The presence of wear faces on the occlusal areas of 46 as well as the thickening of the periodontal ligament space are signs of occlusal trauma. Several studies agree on the multifactorial aetiology of mandibular bone exostosis, with genetic factors being one of the most prevalent<sup>6</sup>, followed by parafunctional activity.<sup>7</sup> Cortes *et al.*<sup>8</sup> found a higher concentration of mechanical stress in areas with exostosis. A close relationship has

also been reported between the presence of dental attrition, dental wear facets and the presence of mandibular tori.<sup>9</sup> Therefore, the combination of genetic background, parafunctional activity and absence of Gardner's syndrome directed the diagnosis towards a bone exostosis located in the patient's mandible.

The differential diagnosis must be made to exclude a peripheral osteoma, which is a benign bone growth lesion from the periosteum.<sup>10</sup> However, the radiographic findings of peripheral osteomas appeared as a radiopaque, round or oval bone circumscribed lesion. The base is often attached to the underlying cortical bone as a pedunculated lesion; occasionally, the osteoma may also have a broad base. The presence of exostosis constitutes a risk factor in systemically compromised patients. Osteonecrosis cases involving tori have been reported in patients taking bisphosphonate medication.<sup>11</sup> The relationship between primary hyperparathyroidism and exostosis has also been studied, showing a reduction in the mandibular cortex width where growth is common, loss of the lamina dura and the appearance of frosted glass.<sup>12</sup>

Regarding treatment, surgical removal is not usually indicated unless there is persistent trauma to the lining of the mucosa and in cases where the use of a dental prosthesis is indicated. In these cases, osteotomy and remodelling will be necessary for prosthesis placement.<sup>13</sup> In the present case report, the lesion was asymptomatic. Therefore, no surgical treatment was necessary.

## CONCLUSIONS

The presence of mandibular exostosis could indicate other underlying systemic or local conditions as parafunctional activity. Mandibular exostosis can remain for life without the need for surgical intervention unless it compromises prosthetic rehabilitation.

## PATIENTS' CONSENT

Informed consent was obtained from the patient to publish the data concerning this case.

## ACKNOWLEDGEMENTS

None

## CONFLICTS OF INTEREST STATEMENT

The authors declare no conflicts of interest.

**ÖZ**

*Bukkal bölgede yer alan tek taraflı mandibular kemik ekzostoza nadir görülen bir durumdur. Klinik tanısı koni ışınli bilgisayarlı tomografi ile doğrulanan tek taraflı mandibular kemik ekzostozisi olan 25 yaşında bir kadın hasta. Ek olarak, damak orta çizgisinde nodüler torus palatinus bulundu. 46 vestibüler kapakta aşınma yüzleri ve periodontal ligament boşluğunun kalınlaşması mevcuttu. Her ikisi de oklüzal travma belirtileridir. Mandibular tori varlığı, parafonksiyonel aktivite veya sistemik sağlık koşulları gibi diğer altta yatan durumları gösterebilir. Mandibular ekzostoz, protez rehabilitasyonundan ödün vermedikçe cerrahi olarak çıkarılmasına gerek kalmadan ömür boyu kalabilir. **Anahtar Kelimeler:** Ekzostoz, torus palatinus, torus mandibularis, vaka raporu.*

**REFERENCES**

1. Koc N, Cagrankaya LB. Investigation of the determinants of the mandibular cortical morphology. Dent Med Probl 2019;56:21-25.
2. Şener S, Karabekiroğlu S, Ünlü N. Assessment of bruxism awareness and related various factors in young adults. Cumhuriyet Dent J 2014;17:361-371.
3. Choi Y, Park H, Lee JS, Park JC, Kim CS, Choi SH, Cho KS, Chai JK, Jung UW. Prevalence and anatomic topography of mandibular tori: computed tomographic analysis. J Oral Maxillofac Surg 2012;70:1286-1291.
4. Scricciu M, Mercu TV, Mercu TR, Birjovanu C, Stan MC, Marinescu IR, Niculescu M, Iorgulescu D, Bataiosu M. Morphological and clinical characteristics of the torus palatinus and torus mandibularis in a sample of young and adults' Romanian people. Rom J Morphol Embryol 2016;57:139-144.
5. Ozyemisci N, Koni B, Dogan A. Prosthetic rehabilitation of a partially edentulous patient with torus mandibularis: a case report. Cumhuriyet Dent J 2011;12:144-146.
6. Dou XW, Park W, Lee S, Zhang QZ, Carrasco LR, Le AD. Loss of Notch3 signaling enhances osteogenesis of mesenchymal stem cells from mandibular torus. J Dent Res 2017;96:347-354.
7. Koc N, Cagrankaya LB. Mandibular tori are associated with mandibular bone quality: a case-control study. Folia Morphol 2018;77:736-741.
8. Cortes AR, Jin Z, Morrison MD, Arita ES, Song J, Tamimi F. Mandibular tori are associated with mechanical stress and mandibular shape. J Oral Maxillofac Surg 2014;72:2115-2125.
9. Morita K, Tsuka H, Shintani T, Yoshida M, Kurihara H, Tsuga K. Prevalence of torus mandibularis in young healthy dentate adults. J Oral Maxillofac Surg 2017;75:2593-2598.
10. Akarslan Z, Kocabay C, Akar V, Akpinar D, Tokman B, Erten H. Peripheral osteoma causing asymmetry of the mandible: a case report and review of the literature. Cumhuriyet Dent J 2008;11:40-44.
11. Mizohata K, Sano T, Oishi K, Morita S. Successful treatment of MRONJ in the palatal torus with teriparatide. J Oral Maxillofac Surg Med Pathol 2018;30:500-503.
12. Rai S, Bhadada SK, Rattan V, Bhansali A, Rao DS, Shah V. Oro-mandibular manifestations of primary hyperparathyroidism. Indian J Dent Res 2012;23:384-387.
13. Madani FM, Kuperstein AS. Normal variations of oral anatomy and common oral soft tissue lesions: evaluation and management. Med Clin North Am 2014;98:1281-1298.