



ISSN : 1302-5805 e-ISSN : 2146-2852

Volume : 21

Issue : 3

2018

Cumhuriyet Üniversitesi
Diş Hekimliği Fakültesi
Dergisi

Cumhuriyet Dental Journal



<http://dergipark.gov.tr/cumudj>

<http://dergi.cumhuriyet.edu.tr/cumudj>

ISSN 1302-5805 e-ISSN 2146-2852 Volume/21 – Number/3 2018

CUMHURİYET ÜNİVERSİTESİ

Diş Hekimliği Fakültesi

Dergisi



Cumhuriyet Dental Journal

An official publication of the
Faculty of Dentistry, Cumhuriyet
University, Issues are published 3
times a year.

Our Faculty Journal first went
into press in 1998.

<http://dergipark.gov.tr/cumudj>

<http://dergi.cumhuriyet.edu.tr/cumudj>

ISSN 1302-5805

e-ISSN 2146-2852

Volume/21-Number/3-2018

Diş Hekimliği Fakültesi

Dergisi Adına Sahibi (Owner)

Prof.Dr.İhsan HUBBEZOĞLU

DEKAN (Dean)

Baş Editör

(Editor-in-Chief)

Prof.Dr.İhsan HUBBEZOĞLU

Editörler

(Associate Editors)

Doç.Dr.Vildan BOSTANCI

Doç.Dr.Derya Ö.DOĞAN

Doç.Dr.Recai ZAN

Doç.Dr.Oğuzhan GÖRLER

Dr.Öğr.Üyesi Burak BULDUR

Yayın Kurulu

(Editorial Board)

**Prof.Dr. Alessandro Leite
CAVALCANTI**

Prof.Dr.Hakan DEVELİOĞLU

Doç.Dr.Derya Ö.DOĞAN

Doç.Dr.Recai ZAN

Doç.Dr.Oğuzhan GÖRLER

Dr.Öğr.Üyesi Burak BULDUR

Yayın Kurulu Sekreteri

(Secretary)

Serap BEKİŞ

Telf: 03462191010/2730

E-mail: cdj@cumhuriyet.edu.tr

BİLİMSEL DANIŞMA KURULU (SCIENTIFIC ADVISORY BOARD)

Adil NALÇACI (Ankara Ü.)	Feridun HÜR MÜZLÜ (Cumhuriyet Ü.)
Ahmet ALTAN (G.O.P.Ü.)	Filiz AYKENT (Serbest Diş Hekimi)
Ahmet Berhan YILMAZ (Atatürk Ü.)	Funda BAYINDIR (Atatürk Ü.)
Ali ERDEMİR (Kırıkkale Ü.)	Fusun ÖZER (İzmir Bozyaka E.ve Arş.Hast.)
Ali Hakan DEVELİOĞLU (Cumhuriyet Ü.)	Giray BOLAYIR (Cumhuriyet Ü.)
Alparslan DİLSİZ (Atatürk Ü.)	Gülfem ERGÜN (Gazi Ü.)
Alpdoğan KANTARCI (Boston U.)	Gülsüm DURUK (İnönü Ü.)
Alper SİNANOĞLU (Kocaeli Ü.)	Hakan AKIN (Cumhuriyet Ü.)
Alper KAPDAN (Cumhuriyet Ü.)	Hakan GÖKTÜRK (G.O.P.Ü.)
Arife KAPDAN (Cumhuriyet Ü.)	Hakan İŞCAN (Acıbadem Sağlık Gr.)
Arlin KİREMİTÇİ (Hacettepe Ü.)	Hakan ÖZDEMİR (Osmangazi Ü.)
Arzu MÜJDECİ (Ankara Ü.)	Hakan TERZİOĞLU (Ankara Ü.)
Arzu TEZVERGİL MUTLUAY (Univ. of Turku)	Hale CİMİLLİ (Marmara Ü.)
Aslıhan ÜŞÜMEZ (Serbest Diş Hekimi)	Halenur ALTAN (G.O.P.Ü.)
Ayşegül GÖZE SAYGIN (Cumhuriyet Ü.)	Hamid JAFARZADEH (Mashhad U.)
Ayşen AÇIKKAL (Cumhuriyet Ü.)	Hare GÜR SOY (Yeditepe Ü.)
Banu ERMİŞ (S.Demirel Ü.)	Hasan YELER (Cumhuriyet Ü.)
Batu Can YAMAN (Osmangazi Ü.)	Hatice BALCI YÜCE (G.O.P.Ü.)
Burak BULDUR (Cumhuriyet Ü.)	Hatice ÖZDEMİR (Atatürk Ü.)
Cafer TÜRKMEN (Marmara Ü.)	Hayati Murat AKGÜL (Atatürk Ü.)
Defne YALÇIN YELER (Cumhuriyet Ü.)	Haydar ALBAYRAK (Erciyes Ü.)
Derya ÖZDEMİR DOĞAN (Cumhuriyet Ü.)	Işıl SARIKAYA (G.O.P.Ü.)
Diğdem EREN (Cumhuriyet Ü.)	Jale GÖRÜCÜ (Hacettepe Ü.)
Emine G. GÖKTOLGA AKIN (Cumhuriyet Ü.)	Kerem KILIÇ (Erciyes Ü.)
Emine PİRİM GÖRGÜN (Cumhuriyet Ü.)	Kezban Meltem ÇOLAK TOPCU (Atatürk Ü.)
Emrah SOYLU(G.O.P.Ü.)	Kürşat ER (Akdeniz Ü.)
Ercan Cenk DORUK (Cumhuriyet Ü.)	Mehmet Emre COŞKUN (Cumhuriyet Ü.)
Esengül BEKAR (G.O.P.Ü.)	Mehmet KAYAHAN (Okan Ü.)
Fadime SUATA ALPASLAN (Cumhuriyet Ü.)	Muhammed SÜMBÜLLÜ (Atatürk Ü.)
Faik TUĞUT (Cumhuriyet Ü.)	Murat TOZLU (Yeditepe Ü.)
Fatih ÖZNURHAN (Cumhuriyet Ü.)	Murat ÜNAL (Cumhuriyet Ü.)
Fatma ÇAĞLAYAN (Atatürk Ü.)	Mustafa GÜNDOĞDU (Atatürk Ü.)

Mustafa MUTLUAY (University of Turku)

Mustafa TUNALI (Bezmialem Ü.)

Mutlu OZCAN (University Of Zurich)

Neslihan ŞİMŞEK (İnönü Ü.)

Nihat AKBULUT (G.O.P.Ü.)

Nurhan ÖZTAŞ (Gazi Ü.)

Nursel AKKAYA (Hacettepe Ü.)

Özden ÖZEL BEKTAŞ (Cumhuriyet.Ü)

Özgül BAYGIN (K.A.T.Ü.)

Perihan OYAR (Hacettepe Ü.)

Regina PALMA-DİBB (São Paulo U.)

Sadullah ÜÇTAŞLI (Ankara Ü.)

Sema BELLİ (Selçuk Ü.)

Sevcan KURTULMUŞ YILMAZ (Y.Doğu Ü.)

Sibel AKBULUT(G.O.P.Ü.)

Sivakumar NUUVULA (N.D.C.H.)

Şenay CANAY (Hacettepe Ü.)

Şeyda HERGÜNER-SİSO

Tamer TAŞDEMİR (K.A.T.Ü.)

Tuğrul ASLAN (Erciyes Ü.)

T. Peyami HOCAOĞLU (Cumhuriyet Ü.)

Tülin POLAT (İnönü Ü.)

Uğur ERDEMİR (İstanbul Ü.)

Ulvi GÜRSOY (University of Turku)

Victor FEITOSA

Yağmur ŞENER (Konya Ü.)

Yakup ÜSTÜN (Erciyes Ü.)

Yasemin KULAK ÖZKAN (Marmara Ü.)

Yeliz HAYRAN (G.O.P.Ü.)

Yurdanur UÇAR (Çukurova Ü.)

Zeynep ÖZKURT KAYAHAN (Yeditepe Ü.)

Cumhuriyet Dental Journal

GUIDELINES FOR AUTHORS

Authors are requested to submit their original manuscript and figures via the online submission and editorial system for Cumhuriyet Dental Journal. Using this online system, authors may submit manuscripts and track their progress through the system to publication. Reviewers can download manuscripts and submit their opinions to the editor. Editors can manage the whole submission/review/revise/publish process.

Format

General

Manuscript length depends on manuscript type. In general, research and clinical science articles should not exceed 20 to 12 double-spaced, typed pages (excluding references, legends, and tables). Clinical Reports and Technique articles should not exceed 4 to 5 pages. Paper dimensions should be 8.5 × 11 inches with 2.5 cm margins on all sides.

use normal, plain font (12-point Times New Roman) number all pages consecutively. indent or space paragraphs. Articles should be arranged in the following order. *Title, Abstract, Introduction, Materials and Methods, Results, Discussion, Conclusions, Acknowledgements, References, Tables and Legends to Illustrations.*

Title page

-Title

-Authors (first name, middle initial, surname) e.g. Faik Tugut, DDS, PhD,^a

-Authors' addresses (abbreviated) e.g.

^aAssistant Professor, Department of Prosthodontics, Faculty of Dentistry, Cumhuriyet University, Sivas, Turkey.

-If the research was presented before an organized group, type the name of the organization and the location and date of the meeting.

PLEASE UPLOAD TITLE PAGE APART FROM MANUSCRIPT.

TITLE PAGE SHOULD UPLOAD AS A SUPPLEMENTARY FILE.

-Corresponding Author details (essential): Name, complete address, phone, fax, and E-mail numbers

Abstract

Should not exceed 300 words and should be presented under the following subheadings: Objectives, Materials and Methods; Results;

Conclusions (For Reviews: Objectives; Data; Sources; Study selection; Conclusions). These subheadings should appear in the text of the summary. Provide a short, nonstructured, 1-paragraph abstract that briefly summarizes the problem encountered and treatment administered for clinical report.

Keywords

Up to 10 keywords should be supplied e.g. Er: YAG laser, composite resin, adhesion.

Introduction

This must be presented in a structured format, covering the following subjects, although not under subheadings: succinct statements of the issue in question; the essence of existing knowledge and understanding pertinent to the issue; and the aims and objectives of the research being reported.

Materials and methods

-describe the procedures and analytical techniques.
-identify names and sources of all commercial products e.g.

-magnetic attachment (Hyper Slim 5513, Hitachi Metals, Tokyo, Japan)

Results

-refer to appropriate tables and figures.
-report statistical findings.

Discussion

-discuss the results of the study.
-agreement with other studies should also be stated.
-identify the limitations of the present study, and suggest areas for future research.

Conclusions

-concisely list conclusions that may be drawn from the research.

-do not simply restate the results.

Acknowledgements

-If the work was supported by a grant or any other kind of funding, supply the name of the supporting organization and the grant number.

References

-References must be identified in the body of the article with superscript Arabic numerals.
-The complete reference list, double spaced and in numerical order, should follow the Conclusions section but start on a separate page. Only references cited in the text should appear in the reference list.

-Do not include unpublished data or personal communications in the reference list.

Journal reference style:

Akin H, Coskun ME, Sari F, Tugut F. Mechanical success and failure of the different types of dental implants: two years follow up study. *Cumhuriyet Dent J* 2009;2:121-124.

Book reference style:

Hilton TJ. Direct posterior composite restorations. In: Schwartz RS, Summitt JB, Robbins JW (eds). *Fundamentals of Operative Dentistry*. Chicago: Quintessence, 1996:207-228.

Tables and Figures

All tables and figures must be thoroughly discussed in the text of the manuscript.

Tables

- one table to a page, each with a title.
- number tables in order of mention using Arabic numerals. Do not list tables in parts (eg, Table Ia, Ib, etc.). Each should have its own number.
 - must be able to "stand alone" apart from text.
 - when appropriate, standard deviations of values should be indicated in parentheses; (do NOT use \pm notation).
 - results of statistical analysis must be included, use superscript letters to indicate significant differences.
 - for explanatory footnotes, use symbols (*, #, **, ##).

Figures

- do not import the figures into the text file.
- figures grouped together should have similar dimensions and be labelled "A, B, C", etc.
- figures should be arranged to the width of 80 mm.
- color and black-and-white photographs should be created and saved at a minimum of 300 dots per inch (dpi).
 - figures should be saved in jpeg format.
 - The electronic image files must be named so that the figure number and format can be easily identified. For example, a Figure 1 in jpeg format should be named fig 1. Multipart figures must be clearly identifiable by the file names: fig 1A, fig 1B, fig 1C, etc.

Graphs

- unique, concise axis labels; do not repeat the Figure caption.
- uniform size for graphs of similar type.
- type size that will be easily read when the graph is reduced to one column width.
- lines that are thick and solid (100% black).

Figure legends

- list together on a separate page.
- should be complete and understandable apart from the text.
- include key for symbols or abbreviations used in Figures.

İÇİNDEKİLER / CONTENTS

ARAŞTIRMA / RESEARCH

- 167-172 The Effect of Slice Thickness on the Volume Estimations Performed by Using Cone Beam CT**
Konik Işınlı BT Kullanılarak Yapılan Hacim Hesaplamalarında Kesit Kalınlığının Etkisi
Seval BAYRAK, Ömer Said SEZGİN, Saadettin KAYIPMAZ, Gamze ÇAN
- 173-177 Investigation of Cytotoxic Effects of Eugenia Caryophyllus (Clove)**
Eugenia Caryophyllus (Karanfil) 'un Sitoksisitesinin Araştırılması
Ceylan HEPOKUR
- 178-183 The Relationship Between the Slope of the Mesioangular Lower Third Molars and the Presence of Second Molar Distal Caries: A Retrospective Study**
Mesioangular Pozisyonadaki Mandibular Üçüncü Molar Dişlerin Eğimi ve Komşu İkinci Molar Dişlerin Distal Yüzeyinde Çürük Varlığı Arasındaki İlişki: Retrospektif Bir Çalışma
Ahmet ALTAN, Emrah SOYLU
- 184-194 Effect of Different Surface Treatments and Composite Resins Used for Repairing Nanohybrid Resins on Microleakege**
Bir Nanohibrit Kompozitin Tamirinde Kullanılan Farklı Yüzey İşlemleri Ve Kompozit Rezinlerin Mikrosızıntıya Etkisi
Canan ARSLAN AYDOĞAN, Diğdem EREN
- 195-201 The Effect of Different Factors on Stress Distribution in a Molar Tooth**
Çocuk Hastalarda Diş Çekimi Amacıyla Uygulanan Sedasyon Tekniklerinin Geriye Dönük Değerlendirilmesi
Mehmet Sami GULER, Sadri SEN
- 202-208 Evaluation of Cytotoxicity of Qmix, Ethylene Diamintetraacetic Acid and Chlorhexidine on Human Osteoblast Cell Line**
Human Osteoblast Hücre Hattı Üzerinde Qmix, Etilen Diamintetraasetik Asit ve Klorhheksidin 'in Sitotoksisitesinin Değerlendirilmesi
Zeliha UĞUR AYDIN, Kerem Engin AKPINAR, Ceylan HEPOKUR,
Demet ALTUNBAŞ
- 209-215 Accuracy of Digital Panoramic Radiographs on the Vertical Measurements of Dental Implants**
Dijital Panoramik Radyografilerin Dental İmplantların Dikey Ölçümleri Üzerindeki Doğruluğu
Burak Kerem APAYDIN, Füsun YASAR, Alper KIZILDAĞ3, Osman Ufuk TASDEMİR

- 216-223** **Number of Fole Usage on Dentinal Defect Incidence of Waveone Gold and Reciproc NiTi Instruments**
WaveOne GOLD ve Reciproc NiTi Kanal Aletlerinin Kullanım Sayısının Dentin Defekti Oluşturma İnsidansı Üzerine Etkisinin İncelenmesi
Taha ÖZYÜREK, Koray YILMAZ, Gülşah USLU
- 224-229** **Evaluation of Carabelli's Trait in a Group of Turkish Patients**
Bir Grup Türk Hastada Karabelli Özelliğinin Değerlendirilmesi
Mağrur KAZAK
- 230-238** **Effect of Ozone Pretreatment on the Microleakage of Class V Cavities Following Office Bleaching with Diode Laser**
Diyot Lazerle Yapılan Ofis Beyazlatma Tedavisi Sonrası Ozon Uygulamasının Sınıf V Kavitelerde Mikrosızıntı Üzerine Etkisi
Derya SÜRMEİOĞLU, Emine Şirin KARAARSLAN, Eda ERBİL, Osman DEMİR
- 239-248** **Comparison and Evaluation of Alveolar Bone Around Lower Central Incisors in Class III and Class I Patients**
İskeletsel Sınıf III ve Sınıf I Bireylerin Alt Santral Kesici Dişlerinin Etrafındaki Alveolar Kemiğin Karşılaştırılması ve Değerlendirilmesi
Ezgi ATİK, Hande GÖRÜCÜ COŞKUNER, Tülin TANER
- 249-255** **Fortification of Fractured Instrument Removal Simulated Roots Using Several Calcium Silicate-Based Materials**
Kırık Enstrüman Çıkartılma Simülasyonu Yapılmış Köklerin Farklı Kalsiyum Silikat İçerikli Materyaller Kullanılarak Güçlendirilmesi
Tuğrul ASLAN, Yakup ÜSTÜN, Firdevs ÇINAR, Salih DÜZGÜN, İbrahim ŞENER
- 256-262** **Effect of Coronal Barrier Thickness on Fracture Strength of Immature Teeth**
Koronal Bariyer Kalınlığının Gelişimi Tamamlanmamış Dişlerin Kırılma Dayanımına Etkisi
Selen KÜÇÜKKAYA EREN, Sevinç ASKERBEYLİ ÖRS, Hacer AKSEL

OLGU SUNUMU / CASE REPORT

263-267 Hemangioma Presenting with Multiple Phleboliths: Case Report with CBCT Findings

D Multiple Flebolit Görülen Hemanjiyom: KIBT Bulguları ile Olgu Sunumu

Hazal KARSLIOGLU, A.Pınar SUMER

268-273 Composite Restoration Supported with Fiber Post in Case Complçated Crown Fracture: A Case Report

Komplike Kron Kırığı Olgusunda Fiber Post Destekli Kompozit Restorasyon: Olgu Sunumu

Seda ÖZKANOĞLU, Emine Gülşah GÖKTOLGA AKIN, İhsan HUBBEZOĞLU



THE EFFECT OF SLICE THICKNESS ON THE VOLUME ESTIMATIONS PERFORMED BY USING CONE BEAM CT

Konik Işınlı BT Kullanılarak Yapılan Hacim Hesaplamalarında Kesit Kalınlığının Etkisi

Seval BAYRAK¹, Ömer Said SEZGİN²

Saadettin KAYIPMAZ², Gamze ÇAN³

Makale Kodu/Article Code : 406394

Makale Gönderilme Tarihi : 16.03.2018

Kabul Tarihi : 22.06.2018

ABSTRACT

Objective: The purpose of this study is to investigate possible effects of the slice thickness on volume estimations with Cone Beam Compute Tomography (CBCT).

Materials and Methods: Intraosseous cavities representing bone defects on femoral condyles of bovines were scanned by CBCT. Consecutive slices at 0.1 mm, 0.2 mm, 0.3 mm, 0.4 mm, 0.5 mm, 1 mm, 2 mm, 3 mm, 4 mm, and 5 mm thickness were used to estimate the volumes of the cavities using Cavalieri principle of stereological methods then compared with the volumes obtained by Archimedean principle.

Results: The volumes estimated by Cavalieri principle in 0.1 mm, 0.2 mm and 0.3 mm thickness slices were consistent with the volumes obtained by Archimedean principle ($p>0.05$). For all the defects on the CBCT images, the volumes of the defects which were calculated with Cavalieri principle in 0.1 mm, 0.2 mm and 0.3 mm slice thickness were found to be consistent with the actual volumes, however, the volumes that were calculated in 0.4 mm, 0.5 mm, 1 mm, 2 mm, 3 mm, 4 mm, and 5 mm slice thickness were found to differ from the actual volumes.

Conclusion: When volume calculations were made by Cavalieri principle, the thinnest slice section should be chosen to make calculations consistent with actual volumes.

Keywords: Radiography, Dental, Cone Beam Computed Tomography, Quantitative Evaluation, Cavalieri Principle

ÖZ

Amaç: Bu çalışmanın amacı Konik Işınlı Bilgisayarlı Tomografi (KIBT) ile hacim hesaplamalarında kesit kalınlığının olası etkilerini araştırmaktır.

Materyal ve Metod: Sığır femur başında kemik defektlerini taklit eden intraosseöz kaviteler KIBT ile tarandı. Kavitelerin stereolojik bir metod olan Cavalieri prensibiyle hacim hesaplamalarında 0,1 mm, 0,2 mm, 0,3 mm, 0,4 mm, 0,5 mm, 1 mm, 2 mm, 3 mm, 4 mm ve 5 mm kalınlığında ardışık kesitler kullanıldı. Hesaplanan hacimler daha sonra Arşimet prensibiyle hesaplanan hacimlerle kıyaslandı.

Bulgular: 0,1 mm, 0,2 mm ve 0,3 mm kesit kalınlığında Cavalieri prensibiyle hesaplanan hacimler Arşimet Prensibiyle hesaplanan hacimlerle uyumluydu ($p>0,05$). KIBT görüntülerinde tüm defektler için, 0,1 mm, 0,2 mm, 0,3 mm kesit kalınlığında hesaplanan hacimler gerçek hacimlerle uyumluyken, 0,4 mm, 0,5 mm, 1 mm, 2 mm, 3 mm, 4 mm ve 5 mm kesit kalınlığında hesaplanan hacimler gerçek hacimlerden farklı bulundu.

Sonuç: Cavalieri prensibiyle hacim hesaplanacağı zaman, gerçek hacimle uyumlu hesaplamalar yapılabilmesi için en ince kesit kalınlığı seçilmelidir.

Anahtar Kelimeler: Radyografi, Dental, Konik Işınlı Bilgisayarlı Tomografi, Kantitatif Değerlendirme, Cavalieri Prensibi

¹ Abant İzzet Baysal University, Faculty of Dentistry, Department of Dentomaxillofacial Radiology, Bolu, Turkey

² Karadeniz Technical University, Faculty of Dentistry, Department of Dentomaxillofacial Radiology, Trabzon, Turkey

³ Karadeniz Technical University, Faculty of Medicine, Department of Public Health, Trabzon, Turkey

INTRODUCTION

The use of three-dimensional imaging methods for the maxillofacial region has become common due to the limitations of two-dimensional images obtained by conventional radiography. Cone Beam Computed Tomography (CBCT) was developed for several medical applications, such as angiography^{1,2} mammography¹⁻³ and radiotherapy guidance^{1, 2, 4} and it was approved by the Food and Drug Administration (FDA) in 2001 for the visualization of maxillofacial tissues. It is also used in almost all areas of dentistry.^{3, 5-7} Using CBCT, it is possible to obtain sectional images on the axial, sagittal and coronal planes. From these images, the volume of an anatomic or pathologic structure in any plane can be calculated with Cavalieri principle. According to this principle, the volume of an amorphous object can be calculated by multiplying the total area of the sections, which are taken randomly from the overall structure of an object, and the lengths between these sections.⁸

In the literature, there are several studies which use CBCT images for volumetric calculations⁸⁻¹², however, only few studies published regarding the effect of the slice thickness on these calculations.

The aim of this study is to investigate the effect of slice thickness on volume estimation by applying Cavalieri principle to CBCT images.

MATERIALS AND METHODS

In this study, 13 bovine femurs were used and 30 different intraosseous defects with different volumes were created on the femoral condyles by using an oval tungsten carbide burr. The upper borders of the defects were filled with dental stone (Fig. 1).

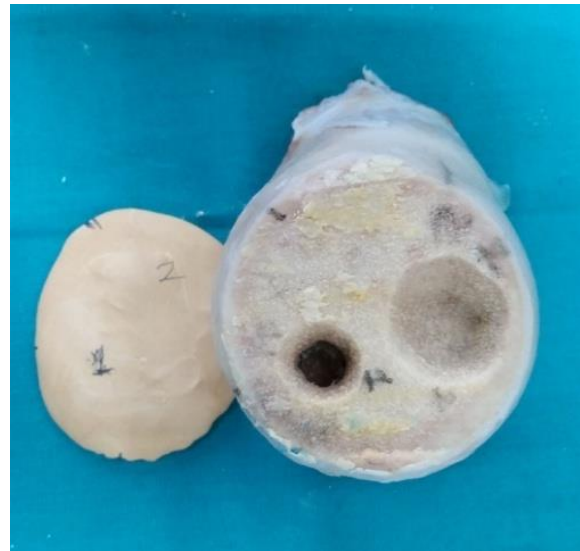

Fig.1: Intraosseous defects on the condyle of bovine femurs

CBCT scans of intraosseous cavities were taken with Kodak 9300 Cone Beam 3D System (Kodak Dental Systems, Carestream Health, Rochester, NY) with the following parameters 5×5 cm field of view, 0.09 mm voxel size, 84 kV tube voltage, 5 mA tube current, and 20. s scan time for the defects with a diameter smaller than 4.5 mm and 8×8 cm field of view, 0.2 mm voxel size, 90 kV tube voltage, 4 mA tube current, and 8 s scan time for defects with a diameter is larger than 4.5 mm.

Cavalieri principle was applied to calculate the volume of each intraosseous defect. For this purpose, each defect was obtained into consecutive sections of 0.1 mm, 0.2 mm, 0.3 mm, 0.4 mm, 0.5 mm, 1 mm, 2 mm, 3 mm, 4 mm and 5 mm using 3D-DOCTOR software (3D-DOCTOR Able Software Corp, Lexington, USA). There were no intervals between sections. The planimetry method was used to calculate the surface area of these sectional images (Fig. 2). The software automatically gave the total volume by multiplying the total surface area with the section thickness. This procedure was followed for all defects in every section thickness.

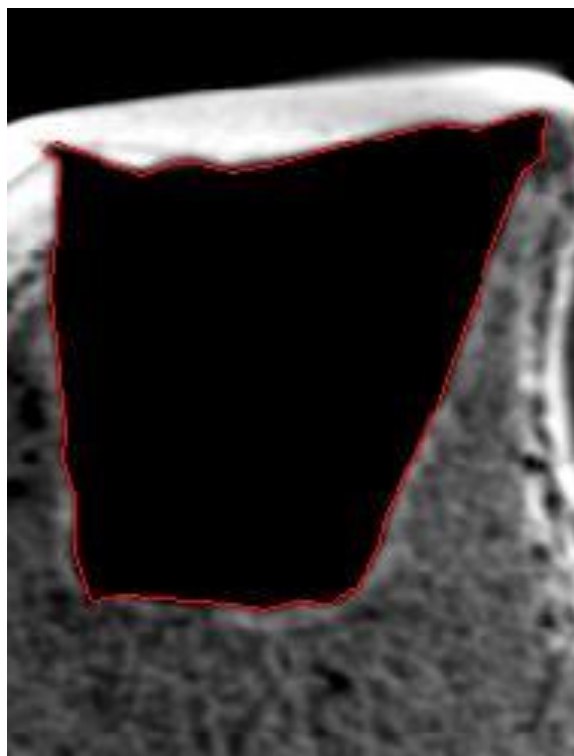


Fig.2: Borders of intraosseous defects traced manually surface of area calculate planimetry method by 3D-DOCTOR software

To calculate the actual volumes of the intraosseous defects, the intraosseous cavities were filled with low-viscosity silicon impression material. After polymerization, silicon impressions were immersed into a pycnometer filled with water, and the volumes were calculated using the density and weight of the water run-over, based on Archimedeian principle. These measurements by the water-displacement method served as the gold standard.

The data were analyzed using SPSS, version 13 (Chicago, IL, USA). The One Sample Kolmogorov-Smirnov normality test was applied for all samples. The actual volumes, which were determined by the Archimedeans principle, and the volumes that were calculated using Cavalieri principle in 0.1 mm, 0.2 mm, 0.3 mm, 0.4 mm, 0.5 mm, 1 mm, 2 mm, 3 mm, 4 mm, and 5 mm section thickness, were compared with Paired Sample T-tests separately. All statistical tests were set at the 95% confidence level ($p \leq 0.05$).

In order to analyze the relationship between the number of sections and defect volumes, measurements were categorized under 10 different groups such as 1-5, 6-10, 11-15, 16-20, 21-30, 31-50, 51-100, 101-200, 201-300 and 301-570, according to the number of sections. The average absolute percent variance values of each group were compared.

RESULTS

The results of the volume estimations using CBCT images and the actual volumes via Archimedeian principle are shown in Table 1.

Table 1: Actual and estimated volumes of intraosseous defects (mm³)

Actual	0.1 mm	0.2 mm	0.3 mm	0.4 mm	0.5 mm	1 mm	2 mm	3 mm	4 mm	5 mm
34.19	34.281	34.665	35.501	36.349	34.573	32.043	32.233	31.479	26.754	13.672
83	81.716	83.211	83.671	82.974	82.791	79.864	83.34	64.304	70.42	38.797
201.7	200.849	201.638	202.056	202.6	201.194	204.463	197.12	213.401	217.718	230.741
204.7	206.9	208.9	208.2	208.1	207.8	207.7	203.5	207	224.5	163.8
240.5	237.962	239.77	238.915	217.001	224.461	214.14	213.571	233.735	229.946	169.029
252.3	255.4	247.9	248.454	247.229	248.163	245.407	250.306	252.764	245.654	174.216
758.57	748.094	734.15	727.081	763.094	745.045	748.337	755.237	755.442	766.562	812.652
1107.87	1126.875	1118.75	1104.359	1112.601	1128.37	1123.547	1127.913	1128.446	1130.047	1110.58
1965.424	1982.84	2002.259	1995.981	1984.497	1977.445	1991.603	1966.157	1948.801	1968.576	1932.35
3123.449	3151.126	3152.77	3192.42	3173.792	3180.704	3183.876	3186.841	3115.794	3225.317	3000.612
3688.741	3665.944	3705.968	3754.495	3773.161	3725.585	3783.47	3827.369	3670.824	3541.282	3573.174
4354.66	4288.111	4314.057	4336.441	4331.779	4356.851	4321.192	4301.269	4227.796	4280.707	4245.395
4880.609	4889.039	4793.465	4893.452	4845.549	4797.292	4876.001	4894.586	4938.995	5013.117	4905.436
7063.061	7124.638	7050.054	7112.738	7103.6	7056.952	7070.474	7039.619	7026.694	7347.047	7258.131
7295.303	7233.158	7072.326	7196.554	7271.611	7249.662	7197.744	7329.884	7166.811	7169.352	7160.988
8900.204	8809.134	8917.495	8889.06	8833.628	8812.946	8897.47	8813.795	8750.177	8837.565	8613.372
9790.969	9829.73	9596.648	9546.473	9648.328	9506.895	9745.128	9458.328	9637.772	9371.204	9468.459
10519.9	10326.72	10229.96	10339.2	10253.3	10424.42	10265.13	10349.08	10348.78	10504.75	10454.96
10802	10801.8	10684.66	10753.45	10795.52	10665.02	10546.15	10557.38	10677.74	10475.7	10687.64
11039.55	11098.28	11048.74	10924.27	10787.43	10884.33	10951.21	10906.51	10740.19	10877.76	10572.54
13730.69	13984.74	13887.75	13890.01	13870.48	13781.29	13684.11	13756.94	13753.31	13841.93	13895.69
14575.41	14432.91	14427.01	14509.31	14395.57	14311.5	14335.68	14373.26	14205.47	14136.72	14132.21
16710.02	16619.23	16507.96	16711.94	16699.68	16579.83	16543.64	16389.9	16503.93	16127.9	16771.62
17088.5	17116.05	17173.75	17079.99	17028.86	17099.26	17057.74	17202.74	16982.99	17206.83	17153.43
17835.74	17964.94	17698.56	18062.1	18027.63	17816.03	17868.37	17961.43	17926.61	17983.11	18036.02
19095.31	19055.14	19011.39	18962.99	18847.66	19057.91	18798.32	18688.44	18696.25	18780.24	19003.96
23361.8	23785.2	23634.71	23347.89	23222.23	23657.16	23637.6	23759.38	23526.65	23522.19	23280.64
24495.29	23420.66	23538.81	23649.45	23817.93	24223.32	24098.58	24062.74	23978.97	23936.24	24284.46
27662.36	27252.03	27699.63	27434.79	27457.27	27395.91	27434.51	27232.23	27307.97	27135.36	27235.01
30052.7	29140.59	29165.9	29350.93	29200.83	29247.43	29538.98	29187.92	29046	28685.66	28888.8

The Paired Sample T-test was used to compare the volumes, which were calculated in every section thickness by Cavalieri principle, and the actual volume, separately. The Paired Sample T-tests showed that there was not a statistical significance between the actual volumes and the calculated volumes in the 0.1 mm, 0.2 mm and 0.3 mm section thickness, however, there was a statistically significant difference between the actual

volumes and the calculated volumes in the 0.4 mm, 0.5 mm, 1 mm, 2 mm, 3 mm, 4 mm, and 5 mm section thicknesses (Table 2).

Table 2: Evaluation of the results with the paired sample t-test ($p \geq 0.05$)

	Sig. (2-tailed)		Sig. (2-tailed)
0.1 mm	0.169	1 mm	0.015
0.2 mm	0.056	2 mm	0.037
0.3 mm	0.078	3 mm	0.004
0.4 mm	0.030	4 mm	0.031
0.5 mm	0.032	5 mm	0.016

According to the average absolute variance percentages of the volumes of the defects which were calculated by Cavalieri principle, the lowest variance was 1.1% at the 0.1 mm section thickness and this value was followed by the 0.3 mm (1.25%), 0.5 mm (1.26%), 0.2 mm (1.28%), 0.4 mm (1.58%), 1 mm (1.8%), 2 mm (1.86%), 3 mm (2.3%), and 4 mm (3.72%). The highest variance was calculated as 8.59% at the 5 mm section thickness (Table 3).

Table 3: The percent deviance of the measurements (from actual volumes) that were calculated by using Cavalieri principle according to number of sections.

Group	1	2	3	4	5	6	7	8	9	10
Section number	1-5	6-10	11-15	16-20	21-30	31-50	51-100	101-200	201-300	301-570
Percent variance	6.9 %	2%	2%	2%	1%	1%	1%	1%	1%	1%

In the volume calculations by Cavalieri principle, the measurements that were performed to investigate the effect of the number of sections were categorized according to the number of sections. The groups were categorized according to number of sections as 1-5, 6-10, 11-15, 16-20, 21-30, 31-50, 51-100, 101-200, 201-300, 301-570 and named as Group 1, Group 2, Group 3, Group 4, Group 5, Group 6, Group 7, Group 8, Group 9, and Group 10. For each defect, the percent variance (deviance of volumes calculated by Cavalieri principle from actual volumes) was calculated and the group average was determined.

In the calculations performed using Cavalieri principle, the maximum deviance was calculated as 6.9% in the measurements that were done on sections 1-5. This variance was 2% on sections 6-20 and it was 1% in the measurements done on sections 21-570.

DISCUSSION

The pathologies which cause resorptions in the jaw lead to bone defects.^{8,10} Knowing the volume of these defects is important for the diagnosis, treatment plan and the evaluation of treatment outcomes¹² and this can be visualized with 3D imaging techniques.^{10,12} Cavalieri principle is a common technique which is used for volumetric calculations and stereological methods and it enables the calculation of the volumes of amorphous objects which cannot be isolated from the outside environment on 3D radiological images.^{9, 13, 14}

In the literature, there are several studies which use CBCT images for volumetric calculations. Bayram *et al.*⁹ calculated volume of nine condyles in the dry human mandible and Kayipmaz *et al.*⁸ calculated volume of osseous defects in the sheep mandible.

In the volumetric calculations performed using Cavalieri principle, the thickness of the section affects the accuracy of the calculations. To investigate the effect of section thickness on volumetric calculations in Computed Tomography (CT), Magnetic Resonance Imaging (MRI) and CBCT images, different section thicknesses were used. Odaci *et al.*¹⁵ calculated volumes of 10 lumbar vertebrae whose volumes changes between 26 600 mm³ and 34 300 mm³ on CT images using Cavalieri principle in 3 mm and 5 mm section thickness. Even though calculated volumes were higher or lower than actual volumes in both section thickness, there was no statistically significant difference between actual volumes and calculated volumes. Similarly, Bilgic *et al.*¹⁶ also calculated volume of an intervertebral disc whose volume changes between 8 780 mm³ and 15 360 mm³ on CT images using Cavalieri principle in 3 mm and 5 mm section thickness. They could not find any statistically significant difference between actual volumes and calculated volumes, in this case either. In our study, also we found that the absolute variance

of calculated defect volumes in 3 mm and 5 mm thickness from actual defect volumes were found to be lower than 5%.

In Sezgin *et al.*'s^{10,17} study, six defects between 155 mm³ and 565.7 mm³ were formed on the two sheep mandible and scanned with CBCT. The volumes were calculated in 0.2 section thickness and 0.8 interval, in 0.6 mm section thickness and 0.4 mm interval and also 1 mm, 1.4 mm, and 2.2 mm section thickness using Cavalieri principle. Results were then compared with the actual volumes and the calculated volumes in thin sections were found compatible with actual volumes.

In our study, the calculated volumes in thin sections (0.1 mm, 0.2 mm, and 0.3 mm) were compatible with actual volumes, however, the calculated volumes in thicker section were different from actual volumes. The section thickness was found more effective on defects with a diameter less than 1 cm, but larger defects were affected less. The highest average variance from actual volume was 60% and it was found at the 5 mm section thickness of the smallest defect. The smallest average absolute variance was 0.001% and it was at 0.1 mm section thickness of the defect with 10 802 mm³ volume. When we look at the volume-to-section-thickness relationship in all defects used in this study, the lowest average variance from actual volume was seen at 0.1 mm section thickness and the highest average variance was calculated at 5 mm section thickness.

When volume was calculated using Cavalieri principle, the number of sections also affects the accuracy of the calculations. Sahin *et al.*¹⁸ reported that 8-15 sections were enough to calculate volume of a liver on MRI images by Cavalieri principle and they did not find any significant difference between actual and calculated volumes. We also found compatible results in our study which was calculated with six or more sections, however, we could not

get compatible results which were calculated with five or fewer sections.

CONCLUSIONS

Consequently, the thinnest section should be chosen to be able to find the closest volumetric value to the actual volume. As volume increases, the effect of section thickness decreases and when the number of sections is fewer than five, a significant difference was seen between the actual and calculated volumes.

REFERENCES

1. Farman AG SW. The Basics of Maxillofacial Cone Beam Computed Tomography. *Seminars in Orthodontics* 2009;15:2-13.
2. Scarfe WC, Farman AG. What is cone-beam CT and how does it work? *Dent Clin North Am* 2008;52:707-730, v.
3. Arnheiter C SW, Farman AG. Trends in maxillofacial cone-beam computed tomography usage. *Oral Radiology* 2006;22:80-85.
4. Scarfe WC, Farman AG, Sukovic P. Clinical applications of cone-beam computed tomography in dental practice. *J Can Dent Assoc* 2006;72:75-80.
5. Haney E, Gansky SA, Lee JS, Johnson E, Maki K, Miller AJ, et al. Comparative analysis of traditional radiographs and cone-beam computed tomography volumetric images in the diagnosis and treatment planning of maxillary impacted canines. *Am J Orthod Dentofacial Orthop* 2010;137:590-597.
6. White SC, Pharoah MJ. The evolution and application of dental maxillofacial imaging modalities. *Dent Clin North Am* 2008;52:689-705, v.
7. Scarfe WC, Levin MD, Gane D, Farman AG. Use of cone beam computed tomography in endodontics. *Int J Dent* 2009;2009:634567.
8. Kayipmaz S, Sezgin OS, Saricaoglu ST, Bas O, Sahin B, Kucuk M. The estimation of the volume of sheep mandibular defects using cone-beam computed tomography images and

a stereological method. *Dentomaxillofac Radiol* 2011;40:165-169.

9. Bayram M, Kayipmaz S, Sezgin OS, Kucuk M. Volumetric analysis of the mandibular condyle using cone beam computed tomography. *Eur J Radiol* 2012;81:1812-1816.

10. Sezgin OS KS, Sahin B. The effect of slice thickness on the assesment of bone defect volumes by cavalieri principle using cone beam computed tomography. *J Digit Imaging* 2012;26:115-118.

11. Agbaje JO, Jacobs R, Maes F, Michiels K, van Steenberghe D. Volumetric analysis of extraction sockets using cone beam computed tomography: a pilot study on ex vivo jaw bone. *J Clin Periodontol* 2007;34:985-990.

12. Esposito SA, Huybrechts B, Slagmolen P, Cotti E, Coucke W, Pauwels R, et al. A novel method to estimate the volume of bone defects using cone-beam computed tomography: an in vitro study. *J Endod* 2013;39:1111-1115.

13. Sahin B, Ergur H. Assessment of the optimum section thickness for the estimation of liver volume using magnetic resonance images: a stereological gold standard study. *Eur J Radiol* 2006;57:96-101.

14. Emirzeoglu M, Sahin B, Selcuk MB, Kaplan S. The effects of section thickness on the estimation of liver volume by the Cavalieri principle using computed tomography images. *Eur J Radiol* 2005;56:391-397.

15. Odaci E, Sahin B, Sonmez OF, Kaplan S, Bas O, Bilgic S, et al. Rapid estimation of the

vertebral body volume: a combination of the Cavalieri principle and computed tomography images. *Eur J Radiol* 2003;48:316-326.

16. Bilgic S, Sahin B, Sonmez OF, Odaci E, Colakoglu S, Kaplan S, et al. A new approach for the estimation of intervertebral disc volume using the Cavalieri principle and computed tomography images. *Clin Neurol Neurosurg* 2005;107:282-288.

17. Petersson A. What you can and cannot see in TMJ imaging--an overview related to the RDC/TMD diagnostic system. *J Oral Rehabil* 2010;37:771-778.

18. Sahin B, Emirzeoglu M, Uzun A, Incesu L, Bek Y, Bilgic S, et al. Unbiased estimation of the liver volume by the Cavalieri principle using magnetic resonance images. *Eur J Radiol* 2003;47:164-170

Corresponding Author

Dr. Seval Bayrak

Abant Izzet Baysal University

Faculty of Dentistry

Dentomaxillofacial Radiology,

Bolu, Turkey.

Tel : +90 374 253 8361

Fax : +90 374 254 0066

E-mail : dtseval@hotmail.com



INVESTIGATION OF CYTOTOXIC EFFECTS OF EUGENIA CARYOPHYLLUS (CLOVE)

Eugenia Caryophyllus (Karanfil)'un Sitoksisitesinin Araştırılması

Ceylan HEPOKUR¹

Makale Kodu/Article Code : 444426

Makale Gönderilme Tarihi : 17.07.2018

Kabul Tarihi : 26.07.2018

ABSTRACT

Objectives: *Eugenia caryophyllus* clove has been used as a traditional medicinal herb for thousands of years. It is used as an analgesic for tooth and toothache with the effect of eugenol substance included in clove. *Eugenia caryophyllus* is used at toothpaste and some mouthwash. The aim of this study was determined of *in vitro* cytotoxic effects *Eugenia caryophyllus* on fibroblast cells.

Materials and Methods: Cytotoxic activity of *Eugenia caryophyllus* were incubated at 24 and 48 h.

Results: In the present study, toxicity of clove that is used as a pain reliever in dentistry has examined on fibroblast cells. The IC₅₀ values of *Eugenia caryophyllus* were found 57.92 ± 0.98 µg/mL in 24 h, 37.97 ± 0.74 µg/mL in 48h.

Conclusions: It is found that the acceptable level of cytotoxicity of *Eugenia caryophyllus*. There is need to further studies in this area.

Keywords: *Eugenia caryophyllus*, Cytotoxicity, Cell culture

ÖZ

Amaç: *Eugenia caryophyllus* binlerce yıldır geleneksel şifalı bitki olarak kullanılmaktadır. Karanfil içerisindeki öjenol maddesinin etkisi ile diş ve diş ağrıları için analjezik olarak kullanılır. Karanfil, diş macunu ve bazı gargaralarda kullanılmaktadır. Bu çalışmanın amacı *Eugenia caryophyllus* in vitro sitotoksik etkileri fibroblast hücre hatları üzerinde belirlemiştir.

Gereç ve Yöntem: *Eugenia caryophyllus*'un sitotoksik aktivitesi XTT testi kullanılarak değerlendirildi. *Eugenia caryophyllus* 24 ve 48 saatlerde inkübe edildi.

Bulgular: Bu çalışmada diş hekimliğinde ağrı kesici olarak kullanılan karanfil toksisitesi fibroblast hücreleri üzerinde incelenmiştir. *Eugenia caryophyllus*'un IC₅₀ değerleri 24 saat de 57,92 ± 0,98 µg / mL, 48 saatte de 37,97 ± 0,74 µg / mL olarak bulundu.

Sonuç: *Eugenia caryophyllus*'un kabul edilebilir düzeyde sitotoksitesinin olduğu bulunmuştur. Bu alanda daha ileri çalışmalara ihtiyaç vardır.

Anahtar kelimeler: *Eugenia caryophyllus*, Sitotoksitesite, Hücre kültürü

¹ Cumhuriyet University, Faculty of Pharmacy, Department of Basic Pharmaceutical Sciences, Division of Biochemistry, Sivas, Turkey

INTRODUCTION

Nowadays, the extraction and evaluation of pure and especially main active component of medical plants and essential oils of these plants is very important both in scientific and in terms of economy.¹ The pharmacological properties of essential oil and its components are also examined and it is stated that they may be beneficial in medicine, cosmetics and industrial areas.² Essential oils are used in medicine from ancient times to the day. The use of herbal extracts for treatment of various human diseases has a long history. The abuse potential of herbal products causes serious side effects. As a result of pharmacological investigations on these medicines based on their intended use in folk medicine, some biological effects have been scientifically explained. Clove is a spice obtained from *Syzygium aromaticum* tree.³ Cloves can also be used by being kept in the mouth for a while, and also used as a spice. it keeps your breath fresh and clean. Cloves are used extensively against bad breath due to their beautiful smell. Cloves contain 15-20% volatile, 13% tannin, 10% fixed oil. Eugenol is major component of clove oil. The effect of "eugenol" contained in it is used as a local drug against mild to moderate dental and gingival pain.⁴ In addition, eugenol has antiviral and antimycotic effects. Cloves contain 15-20% volatile, 13% tannin, 10% fixed oil. Flower buds and flower stalks are dried and used. Eugenol obtained from carnauba is used as antiseptic and analgesic in modern dentistry.⁵ Its use is in the mouth chewing or their beans are boiled in water and drink. Cloves are frequently used in dentistry. The aim of this study was assessment of in vitro cytotoxic effects *Eugenia caryophyllus* on fibroblast cells.

MATERIALS AND METHODS

The Reagent

Phosphate buffer saline (PBS) tablet, trypan blue solution, dimethyl sulfoxide (DMSO), XTT assay and another chemical were purchased from Sigma (St. Louis, MO, USA). Fetal bovine

serum (FBS) was obtained from Biochrom (Berlin, Germany). Penicillin-streptomycin was purchased from Gibco (Paisley, UK) and trypsin EDTA solution from Biological Industries (Kibbutz Beit Haemek, Israel). Dulbecco's modified eagle medium (DMEM) was obtained from Lonza (Verviers, Belgium).

Eugenia caryophyllus (Clove) Oil

Eugenia caryophyllus essential oil was used in the study. *Eugenia caryophyllus* essential oil was purchased from Art de Huile.

Cell Culture

Mouse fibroblast (ATCC-CRL-6364) cells were purchased from (ATCC). Cells were grown at 37°C in a humidified incubator in 5% CO₂. All media were supplemented with 1% penicillin (100 U/mL) and streptomycin (100 µg/mL), and 10% fetal bovine serum (FBS). Cells were counted by a cell counting device (Olympus). Fibroblast cells were seeded in plates with a density of 5×10³.

Cytotoxicity Assay

Cytotoxicity was quantitatively evaluated by the 2,3-bis-(2-methoxy-4-nitro-5-sulfophenyl)-2H-tetrazolium-5-carboxanilide (XTT) method. The cells were seeded in 96-well plate in growth medium then treated with different concentrations of test compounds and incubated in a humidified CO₂ atmosphere at 37°C for 24 and 48h. After the incubation, 100 µL XTT was added to each well for another 2 h incubation. The optical density values were measured at 475 nm with a microplate reader.⁶ The all cells were treated with *Eugenia caryophyllus* (Clove) (200 - 6.25 µg/mL), and incubated for 24h and 48 h. All absorbance was compared to control samples (cells without any test compound) which represented 100% viability. Cell viability was determined as in Eq1.

$$\text{Cell viability (\%)} = \frac{[OD_{\text{sample}} - OD_{\text{blank}}]}{[OD_{\text{positive control}} - OD_{\text{blank}}]} \times 100$$

(Equation 1)

OD_{blank}: dead cell with DMSO

OD_{positive control}: viable cell

Statistical analysis

Data were expressed in the form of arithmetic mean \pm standard deviation ($\bar{x} \pm SD$). Statistical analysis was performed with Sigma Plot 12.0. All determinations were computed independent triplicated ($n=3$).

RESULTS

The cytotoxic effects of *Eugenia caryophyllus* in fibroblast cells are shown in Figure 1 and 2. *Eugenia caryophyllus* were studied at two different incubation times of 24 h and 48 h. The IC₅₀ values of *Eugenia caryophyllus* (Clove) were found $57.92 \pm 0,98 \mu\text{g/mL}$ in 24 h, $37.97 \pm 0.74 \mu\text{g/mL}$ in 48h.

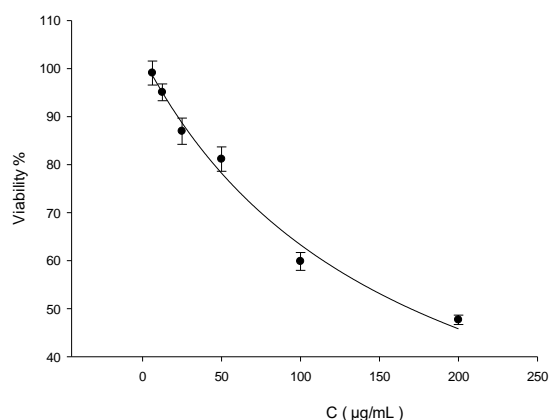


Figure 1. Cytotoxic effect of different concentrations of *Eugenia caryophyllus* in fibroblast cells for 24 h ($n=3$).

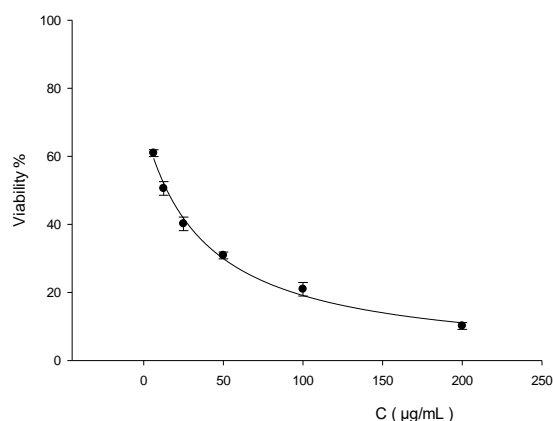


Figure 2. Cytotoxic effect of different concentrations of *Eugenia caryophyllus* in fibroblast cells for 48 h ($n=3$).

DISCUSSION

Compounds of natural product in play an essential role in human life, acting as health-protecting agents. Scientists have always been interested to active compounds of natural

sources. Natural products are an extremely important resource for medical agents. However, although a new approach to drug discovery emerges day by day, none of them is as important as the place of natural products in drug development.^{7,8}

Cloves has biological activities such as antibacterial, antifungal, insecticidal, antioxidant properties. And also, cloves have been used as flavoring and antimicrobial agents in food industries.⁹⁻¹⁰ Clove oil strengthens the immune system as it is a source of iron, calcium and omega3.¹¹ Strong biological activities of the clove oil is mostly due to the presence of eugenol in high levels. In ancient times clove oil and dry carnation seeds were used to treat infection.

Because of anti-inflammatory effect is directly used in toothache and before mucosal injection by dentists. Oral ulcers such as oral gingiva and mucosal areas are also added to the mixtures as antimicrobial and analgesic. Clove used against mouth odor are used as a natural solution in removing dental pain. It is used as a drug against dental and gingival pain of mild to moderate severity with the effect of eugenol substance contained in clove. This material is also found in toothpastes for killing bacteria. It also has pain killer and germicidal properties.¹²

According to the GC-MS results of Cloves in the studies conducted when the literature was examined; Results showed that the extracts were complex mixture of numerous compounds; many of which were present in trace amounts. The concentration of eugenol varies from 77-95%.¹³⁻¹⁴ Other studies of *Eugenia caryophyllus* was investigated for cytotoxicity; Tragoolpua and Jatisatienr stated that strains or isolates of viruses may affect the range of inhibition by *Eugenia caryophyllus*.¹⁵ Prashar *et al.* Clove oil and these components are generally recognized as 'safe', but the in-vitro study here demonstrates cytotoxic properties of both the oil and eugenol, towards human fibroblasts and endothelial cells. Clove

oil was found to be highly cytotoxic at concentrations as low as 0.03% (v/v) with up to 73% of this effect attributable to eugenol.¹⁶ Machado *et al.*, *S. aromaticum* essential oil and eugenol did not caused a significant alteration on the viability of treated mammalian cells when compared to control cells. Our results compare to literature, cytotoxicity of clove has showed lower.

CONCLUSION

The acceptable level of cytotoxicity associated with *Eugenia caryophyllus*. It is seen that the effect of many natural substances such as cloves on cytotoxicity should be examined. Such studies will help to reveal substances that can be used naturally for humanity. We will try to expand this work in our next publication. *Eugenia caryophyllus* oil may use active substance for medicine.

REFERENCES

1. Toroğlu S. ve Çenet M. KSÜ Fen ve Mühendislik Dergisi. 2006; 9(2):12-20.
2. Hammer KA, Carson CF, Riley TV. Journal of Applied Microbiology. 1999;86: 985-990.
3. Cortés-Rojas DF, Souza CRF, Oliveira WP. Clove (*Syzygium aromaticum*): a precious spice. Asian Pac J Trop Biomed. 2014;4(2): 90-96.
4. Cansian RL, Vanin AB, Orlando T, Piazza SP, Puton BM, Cardoso RI, Gonçalves IL, Honaiser TC, Paroul N, Oliveira D. Toxicity of clove essential oil and its ester eugenyl acetate against *Artemia salina*. Braz J Biol. 2017; 77(1):155-161. doi: 10.1590/1519-6984.12215.
5. Mahmoud H, Mina KA, Hassan R. Analgesic effect of clove essential oil in mice. Avi J Phytomed. 2011;1:1-6.
6. Gezegen H, Hepokur C, Tutar U, Ceylan M. Synthesis and Biological Evaluation of Novel 1-(4-(Hydroxy (1-oxo-1,3-dihydro-2H-inden-2-ylidene) methyl) phenyl) -3-phenylurea Derivatives. Chemistry Biodiversity. 2017;14 (10): doi: 10.1002/cbdv.201700223.
7. Heinrich M, Bremner P. Ethanobotany and ethanopharmacy-their role for anticancer drug development. Curr Drug Targets. 2006; 7: 239-245.
8. Thirumal M, Kishore G, Prithika R, Das S, Nithya G. In vitro anticancer activity of *Tecoma stans* (L) ethanolic leaf extract on human breast cancer. Journal of Pharmacognosy and Phytochemistry. 2016; 5(4): 331-334.
9. Jasna I, Suzana DB, Dusan M, Mihailo R, Irena Z. Evaluation and improvement of antioxidant and antibacterial activities of supercritical extracts from clove buds. J Funct Food. 2013;5:416-423.
10. Nazrul IB, Jaripa MD, Nemai CN, Farhana A. Constituents of the essential oil from leaves and buds of clove (*syzigium caryophyllatum* L. Alston). African J Plant Sci. 2010;4:451-454.
11. Bressler K, Ron B. Effect Of Anesthetics On Stress And The Innate Immune System Of Gilthead Seabream (*Sparus Surata*), The Israeli. Journal of Aquaculture Bamidgeh. 2014; 56(1):5-13.
12. Ho YC, Huang FM, Chang YC. Mechanisms of cytotoxicity of eugenol in human osteoblastic cells *in vitro*. Int Endod J. 2006; 39(5):389-393.
13. Trajano VN, Lima EO, Souza EL, Travassos AER. Inhibitory effect of the essential oil from *Eugenia caryophyllata* Thumb leaves on coalho cheese contaminating microorganisms. Ciência e Tecnologia de Alimentos. 2010;30(4):1001-1006.
14. Singh J, Baghotia A, Goel SP. Thunberg (Family Myrtaceae): a review. *Eugenia caryophyllata* International Journal of Research in Pharmaceutical and Biomedical Sciences. 2012;3(4):1469-1475.
15. Tragoolpua Y, Jatisatienr A. Anti-herpes simplex virus activities of *Eugenia caryophyllus* (Spreng.) Bullock & S. G.

Harrison and essential oil, eugenol. *Phytotherapy research*. 2017;21(12):1153-58.

16. Prashar A, Locke IC, Evans CS. Cytotoxicity of clove (*Syzygium aromaticum*) oil and its major components to human skin cells, *Cell Proliferation*. 2006;39(4):241-248.

17. Machado M, Dinis AM, Salgueiro L, Custódio José BA, Cavaleiro C, Sousa MC. Anti-Giardia activity of *Syzygium aromaticum* essential oil and eugenol: Effects on growth, viability, adherence and ultrastructure. *Exp Parasitol*. 2011;127:732-739.

Corresponding Author

Ceylan HEPOKUR

Cumhuriyet University,

Faculty of Pharmacy,

Department of Basic Pharmaceutical Sciences,
Division of Biochemistry

58140, Sivas, Turkey

Tel : +90 346 219 10 10 ext 3913

Fax : +90 346 219 16 34

E-mail : cozsoya@gmail.com



THE RELATIONSHIP BETWEEN THE SLOPE OF THE MESIOANGULAR LOWER THIRD MOLARS AND THE PRESENCE OF SECOND MOLAR DISTAL CARIES: A RETROSPECTIVE STUDY

Mesioangular Pozisyonadaki Mandibular Üçüncü Molar Dişlerin Eğimi ve Komşu İkinci Molar Dişlerin Distal Yüzeyinde Çürük Varlığı Arasındaki İlişki: Retrospektif Bir Çalışma

Ahmet ALTAN¹, Emrah SOYLU²

Makale Kodu/Article Code : 444396

Makale Gönderilme Tarihi : 16.07.2018

Kabul Tarihi : 31.07.2018

ABSTRACT

Objective: The purpose of this study was to examine the relationship between the degree of mesioangular mandibular third molar teeth and the presence of distal caries in the second molar teeth.

Materials and Methods: In this retrospective study, panoramic radiographs of 617 patients (328 females, 289 males) with impacted teeth in partially erupted mesioangular position were examined. The angle between the mandibular occlusal plane and the occlusal surface of the mandibular third molar was measured. Third molar teeth in mesioangular positions with an angle between 11° and 30° were classified as Group 1, an angle between 31° and 50° as Group 2, and an angle between 51° and 70° as Group 3. For each group, the presence of caries in the distal contact point of adjacent second molar teeth was detected.

Results: A total of 816 mandibular third molar teeth in the mesioangular position were analyzed. Of these, 439 (53.8%) were in females and 377 (46.2%) were in males. The prevalence of caries in the distal aspect of the second molar teeth was 34.5% in males and 21.4% in females ($p < 0.001$). A statistically significant difference was found between the groups ($p < 0.05$). The results showed that a slope of 51° to 70° in mandibular third molar presents a higher risk for caries formation in the distal aspect of second molar teeth.

Conclusions: Early prophylactic extraction of impacted mandibular teeth with a slope between 51° and 70° may prevent caries formation in the distal aspect of adjacent second molar teeth.

Key Words: Oral surgery; dental caries; third molar

ÖZ

Amaç: Bu çalışmanın amacı; mesioangular pozisyonadaki mandibular üçüncü molar dişlerin eğimi ile komşu ikinci molar dişlerin distal yüzeyindeki çürük varlığı arasındaki ilişkiyi incelemektir.

Gereç ve Yöntem: Bu retrospektif çalışmada, alt çenede kısmen sürmüş mesioangular pozisyonda gömülü dişi olan, 617 hastanın (328 kadın, 289 erkek) panoramik radyografları incelendi. Mandibular okluzal düzlem ve mandibular üçüncü moların okluzal yüzeyi arasındaki açı ölçüldü. 11° ile 30° arasında bir değere sahip mesioangular üçüncü molar dişler Grup 1 olarak, 31° ve 50° arasındakiler Grup 2 olarak, 51° ve 70° arasındakiler Grup 3 olarak sınıflandırıldı. Ardından komşu ikinci molar dişin distal temas noktasındaki çürük varlığı tespit edildi.

Bulgular: Mesioangular pozisyonda toplam 816 adet mandibular üçüncü molar diş analiz edildi. Bunlardan 439'u (%53,8) kadınlarda, 377'si (%46,2) erkeklerde görüldü. İkinci molar dişin distalinde çürük prevalansı erkeklerde %34,5, kadınlarda %21,4 idi ($p < 0,001$). Açısal değerlere göre oluşturulan gruplar arasında istatistiksel olarak anlamlı bir fark görüldü ($p < 0,05$). Sonuçlar, 51° ile 70° arasında bir eğime sahip mandibular üçüncü molar dişlerin, ikinci molar dişlerin distal yüzeyinde çürük oluşumu için daha yüksek bir risk arzettiğini gösterdi.

Sonuç: 51° ile 70° arasında bir eğime sahip gömülü mandibular üçüncü molar dişlerin profilaktik olarak erken çekimi, komşu ikinci molar dişlerin distal yüzeyinde çürük oluşumunu önleyebilir.

Anahtar Kelimeler: Oral cerrahi, diş çürükleri, üçüncü molar diş

¹ Department of Oral and Maxillofacial Surgery, Faculty of Dentistry, Gaziosmanpaşa University, Tokat / Turkey

² Department of Oral and Maxillofacial Surgery Faculty of Dentistry, Erciyes University, Kayseri / Turkey

INTRODUCTION

Teeth that are completely or partially within the bone and soft tissue with no placed in occlusion for various reasons, despite passing the normal eruption age, are called impacted teeth. Impacted teeth may cause various pathologies, such as pericoronitis, infection, unrestorable caries, root resorption in adjacent teeth, periodontal bone loss, cystic lesions, and neoplasms.¹ The impacted position can be horizontal, vertical, mesioangular, distoangular, buccolingual, or inverted.² Shiller stated that when the angle between the mandibular occlusal plane and the occlusal plane of the third molar is between 11° and 70° , the tooth position is mesioangular.³ Mesioangular and horizontal positions are more frequently associated with pathological conditions.¹

The teeth with the highest impaction rate are mandibular third molar teeth.⁴ Removal of an impacted third molar is one of the most commonly performed procedures in oral surgery. These teeth are surgically removed for prophylactic, orthodontic, and prosthetic reasons, or for the diagnosis of associated pathologies. The caries formed in the distal part of the second molar teeth justify prophylactic removal of the third molar teeth. McArdle and Renton⁵ reported that distal caries in the second molar will not develop in the absence of the third molar. Furthermore, there is a higher risk of caries formation in the second molar distal associated with partially-erupted mesioangular mandibular third molar teeth.⁶

The purpose of this study was to examine the correlation between the degree of mesioangular mandibular third molar teeth and the presence of distal caries in the second molar teeth by measurements performed on panoramic radiographs.

MATERIALS AND METHODS

In this retrospective study, panoramic radiographs of 617 patients (328 females, 289 males) with impacted teeth in partially erupted

mesioangular position were examined. All patients were transferred to the Department of Oral and Maxillofacial Surgery, Faculty of Dentistry of Gaziosmanpasa University between September 2013 and August 2017. This study included 816 mandibular third molar teeth in the mesioangular position. This study was approved by the local Ethics Committee (Project no: 17KAEK160).

Shiller's method³ was used to determine if teeth were in the mesioangular position. According to this method, the angle between the mandibular occlusal plane and the occlusal surface of the mandibular third molar was measured (Figure 1).

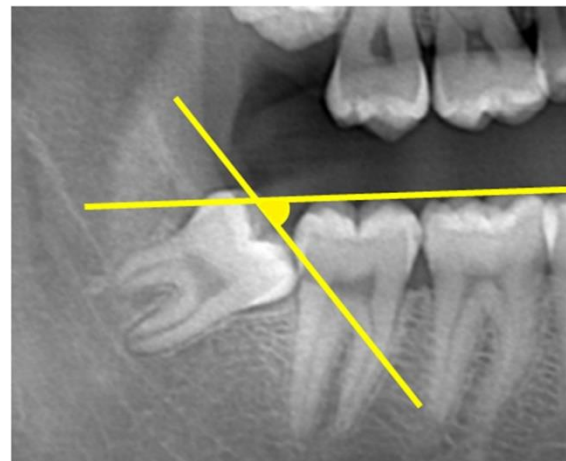


Figure 1: Orthopantomograph showing how angulation of the third molar was measured.

Angular measurements were made using the Image J software (National Institutes of Health, Bethesda, MD, USA). Values between 11° and 70° were determined as being mesioangular positions. The mandibular third molar teeth in mesioangular positions were then categorized into three groups. Third molar teeth with an angle between 11° and 30° were classified as Group 1, an angle between 31° and 50° as Group 2, and an angle between 51° and 70° as Group 3. For each group, the presence of caries in the distal contact point of adjacent second molar teeth was detected from the panoramic radiographs. Patients with pre-existing restorations in adjacent second molar teeth were excluded from the study.

Two of the authors reviewed the panoramic radiographs. Prior to the investigation, calibration of the examiners was undertaken until intra-examiner reliability and reproducibility was achieved. To evaluate intra-examiner agreement, Cohen's Kappa test applied. When those X-rays causing a difference of opinion were analysed by both clinicians together, a consensus was reached by discussion.

IBM SPSS Statistics for Windows, version 20.0 (IBM Corp, Armonk NY, 10504, USA) was used for statistical analyses of the study data. Normality and variance were tested using the one-sample Kolmogorov-Smirnov test. In multiple comparison of measurements of the groups with normal distribution, One-way ANOVA test and Tukey post hoc test were used. When the p value was less than 0.05, the difference between the variables was considered statistically significant.

RESULTS

Panoramic radiographs of 617 patients were examined in this study. The age of the patients ranged from 16 to 54 (average: 25.64 ± 7.03) years. Age and gender distributions are shown in Table 1.

Table 1: Age and gender distribution of patients with mandibular third molar teeth in the mesioangular position

Age groups	Female	Male	Total
16-20	101	55	156
21-25	135	78	213
26-30	45	71	116
31-35	30	43	73
≥ 36	17	42	59
Total	328	289	617

A total of 816 mandibular third molar teeth in the mesioangular position were analyzed. Of these, 439 (53.8%) were in females and 377 (46.2%) were in males. The prevalence of caries in the distal aspect of adjacent second molar teeth was 27.5% ($n = 224$). There was a

statistically significant difference between the gender of the patients and the prevalence of caries in the distal second molar teeth ($p < 0.001$). The prevalence of caries in the distal aspect of the second molar teeth was 34.5% in males and 21.4% in females (Table 2).

Table 2: Presence of caries on second molar distal aspect associated with gender

	Distal caries in second molar		Total
	Yes	No	
Female	94 (21.4%)	345 (78.6%)	439
Male	130 (34.5%)*	247 (65.5%)	377
Total	224 (27.5%)	592 (72.5%)	816

* $p < 0.001$

A statistically significant difference was found between the groups when the prevalence of caries in the distal aspect of the adjacent second molar teeth was evaluated. Group 3 had the highest ratio of the three groups (Table 3).

Table 3: Presence of caries in the distal aspect of the second molar teeth

	Groups						p values			
	Group 1 11-30 (mean 20.8 ± 5.1)		Group 2 31-50 (mean 40.3 ± 5.4)		Group 3 51-70 (mean 60.6 ± 5.9)		p	p _{1,2}	p _{1,3}	p _{2,3}
	Yes	No	Yes	No	Yes	No				
Distal caries in second molar	22 (15.1%)	124 (84.9%)	81 (24.8%)	246 (75.2%)	121 (35.3%)	222 (64.7%)	<0.05	0.070	0.000*	0.006*

* $p < 0.05$

DISCUSSION

The prophylactic removal of an impacted tooth is defined as the surgical removal of the tooth when there is no pathology or symptom associated with the impacted tooth. The removal of a third molar tooth associated with a pathological condition is usually an easy decision. Some authors advocate prophylactic extraction of impacted third molar teeth due to the possibility of causing pathological conditions, such as caries and periodontal disorder.^{1,7-9} However, some researchers believe there is insufficient evidence to

prophylactically extract these teeth.^{10, 11} Distal caries of mandibular second molar teeth are a common complication associated with impacted third molar teeth. In this study, the relationship between the third molar teeth in the mesioangular position and the presence of caries in the distal aspect of second molar teeth was examined. We found that the prevalence of caries was highest in teeth with a slope between 51° and 70°.

There is a higher risk of caries formation in the distal aspect of adjacent second molars associated with partially sustained mesioangular mandibular third molar teeth compared with other angulations.^{6, 12} In previous studies, the prevalence of caries formation in the distal aspect of adjacent mandibular second molar teeth has varied between 7% and 32%.^{7-9, 13} In this study, the prevalence rate was 27.5%. This range of rates may be related to cultural differences between patients, such as oral hygiene habits, socio-economic status, and diagnostic methods used. In this study, we believe that the evaluation of the mandibular teeth, in the mesioangular position only, may result in a higher rate.

The relationship between the slopes of the impacted third molar teeth and caries formation in the distal aspect of second molar teeth was examined in this study. Ozec *et al.*⁹ reported that values of 31° and 70° led to a significant risk of second molar distal caries. Falci *et al.*¹⁴ reported that when the angulation of mandibular third molar was between 31° and 108° there was a greater possibility of distal caries on the second molar. Chang *et al.*⁸ emphasized that mesial angulation of 41°- 80° causes a higher incidence of adjacent second molar caries than in other angulations in the Korean population. The increase of the slope can increase plaque retention and food package on the distal surface of adjacent second molar teeth. In our study, mesioangular values between 11° and 70°, which were measured according to the Shiller³ method, were divided

into subgroups. We found the highest caries risk in the distal aspect of second molar teeth between 51° and 70° (average: 60.61° ± 5.91) in Turkish population. The results of this study are similar with the literature.

Caries formation in the distal aspect of second molar teeth is a long-lasting process that evolves over time and increases with continued exposure to the oral cavity. It has been reported that the incidence rate of caries in the distal aspect of second molar teeth increases with age.^{5, 9, 14} In this study, the prevalence of caries in the distal aspect of second molar teeth was higher in males than in females. We believe this is because of the number of young people between the ages of 16 and 25 was higher among women.

Extraoral radiographs have lower sensitivities than intraoral radiographs in detecting proximal caries.^{15,16} Demineralization is important in the detection of caries by radiography. Panoramic radiography may not detect early caries lesions with inadequate demineralization; however, deep caries lesions that have advanced to the dentine can be detected. Akarslan *et al.*¹⁶ reported that when interproximal caries were detected in mandibular molar teeth, there was no significant difference between bitewing and periapical radiographies, but panoramic radiographs were less accurate for this diagnosis. Intraoral radiographs, such as bitewing, are not routinely used in the impacted third molar tooth surgery. In this study, which was conducted with panoramic radiographs of patients with complaints of impacted third molars, the detection of caries by extraoral radiography can be considered a weakness of the study.

CONCLUSIONS

The results of this study showed that a slope of 51° to 70° in mandibular third molar teeth in the mesioangular position presents a higher risk for caries formation in the distal aspect of adjacent second molar teeth. This data will

help clinicians in making decision on prophylactic extraction of third molar teeth without symptoms. Early prophylactic extraction of impacted mandibular teeth with a slope between 51° and 70° may prevent caries formation in the distal aspect of adjacent second molar teeth.

REFERENCES

1. Polat HB, Ozan F, Kara I, Ozdemir H, Ay S. Prevalence of commonly found pathoses associated with mandibular impacted third molars based on panoramic radiographs in Turkish population. *Oral Surg Oral Med Oral Pathol Oral Radiol Endod* 2008; 105, e41-47.
2. Gaddipati R, Ramisetty S, Vura N, Kanduri RR, Gunda VK. Impacted mandibular third molars and their influence on mandibular angle and condyle fractures-a retrospective study. *J Craniomaxillofac Surg* 2014; 42, 1102-1105.
3. Shiller WR. Positional changes in mesio-angular impacted mandibular third molars during a year. *J Am Dent Assoc* 1979; 99,460-464.
4. Damlar İ, Altan A, Tatlı U, Arpağ OF. Retrospective Investigation of the Prevalence of Impacted Teeth in Hatay. *Cukurova Med Journal* 2014; 39, 559-565.
5. McArdle LW, Renton TF. Distal cervical caries in the mandibular second molar: an indication for the prophylactic removal of the third molar? *Br J Oral Maxillofac Surg* 2006; 44, 42-45.
6. Pepper T, Grimshaw P, Konarzewski T, Combes J. Retrospective analysis of the prevalence and incidence of caries in the distal surface of mandibular second molars in British military personnel. *Br J Oral Maxillofac Surg* 55, 2017; 160-163.
7. Chu FC, Li TK, Lui VK, Newsome PR, Chow RL, Cheung LK. Prevalence of impacted teeth and associated pathologies--a radiographic study of the Hong Kong Chinese population. *Hong Kong Med J* 2003; 9, 158-163.
8. Chang SW, Shin SY, Kum KY, Hong J. Correlation study between distal caries in the mandibular second molar and the eruption status of the mandibular third molar in the Korean population. *Oral Surg Oral Med Oral Pathol Oral Radiol Endod* 2009; 108, 838-843.
9. Ozec I, Herguner Siso S, Tasdemir U, Ezirganli S, Goktolga G. Prevalence and factors affecting the formation of second molar distal caries in a Turkish population. *Int J Oral Maxillofac Surg* 2009; 38, 1279-1282.
10. Song F, Landes DP, Glennly AM, Sheldon TA. Prophylactic removal of impacted third molars: an assessment of published reviews. *Br Dent J* 1997; 182, 339-346.
11. Adeyemo WL. Do pathologies associated with impacted lower third molars justify prophylactic removal? A critical review of the literature. *Oral Surg Oral Med Oral Pathol Oral Radiol Endod* 2006; 102, 448-452.
12. Srivastava N, Shetty A, Goswami RD, Apparaju V, Bagga V, Kale S. Incidence of distal caries in mandibular second molars due to impacted third molars: Nonintervention strategy of asymptomatic third molars causes harm? A retrospective study. *Int J Appl Basic Med Res* 2017; 7, 15-19.
13. van der Linden W, Cleaton-Jones P, Lownie M. Diseases and lesions associated with third molars. Review of 1001 cases. *Oral Surg Oral Med Oral Pathol Oral Radiol Endod* 1995; 79, 142-145.
14. Falci SG, de Castro CR, Santos RC, de Souza Lima LD, Ramos-Jorge ML, Botelho AM *et al.* Association between the presence of a partially erupted mandibular third molar and the existence of caries in the distal of the second molars. *Int J Oral Maxillofac Surg* 2012; 41, 1270-1274.
15. Clark HC, Curzon ME. A prospective comparison between findings from a clinical examination and results of bitewing and panoramic radiographs for dental caries diagnosis in children. *Eur J Paediatr Dent* 2004; 5, 203-209.

16. Akarslan ZZ, Akdevelioglu M, Gungor K, Erten H. A comparison of the diagnostic accuracy of bitewing, periapical, unfiltered and filtered digital panoramic images for approximal caries detection in posterior teeth. Dentomaxillofac Radiol 2008; 37, 458-463.

Corresponding Author

Ahmet ALTAN

Gaziosmanpasa University,

Ali Sevki EREK Yerleskesi,

Tokat / TURKEY

Tel : +905057013189

Fax : +90356212 4225

E-mail : dt.ahmetaltan@gmail.com



BİR NANOHİBRİT KOMPOZİTİN TAMİRİNDE KULLANILAN FARKLI YÜZEY İŞLEMLERİ VE KOMPOZİT REZİNLERİN MİKROSIZINTIYA ETKİSİ

Effect of Different Surface Treatments and Composite Resins Used for Repairing Nanohybrid Resins on Microleakage

Canan ARSLAN AYDOĞAN¹ Diğdem EREN²

Makale Kodu/Article Code : 449364

Makale Gönderilme Tarihi : 31.07.2018

Kabul Tarihi : 14.09.2018

ABSTRACT

Objective: The purpose of this study was to evaluate the effect of eight different surface treatment and three different composite resin on the microleakage in the repair of a nanohybrid composite resin.

Materials and Methods: For repair procedure standard size blocks prepared with nanohybrid composite resin Filtek Z550 (3M ESPE) were classified into Group 1 (control), Group 2 (frez), Group 3 (frez + silane), Group 4, Group 5 (Al₂O₃ + silane), Group 6 (tribochemical silica coating), Group 7 (lazer), Group 8 (lazer + silane). The prepared samples were subjected to 5000 thermal cycles and surface treatments. Each group was divided into three subgroups for application of repair composites (Filtek Z550, G-aenial Flo (GC) and Vertise Flow (Kerr)) the lower subgroup was separated. After the repair treatment, the samples were again subjected to thermal cycling. Then, a microleakage test was made and the data evaluated statistically.

Results: The surface treatments for each composite resins were not statistically different when evaluated among themselves (p>0.05). The composite resins for each surface treatments were not statistically different when evaluated among themselves (p>0.05).

Conclusion: Additional equipment and costly methods for surface treatment in composite restorations did not make any difference due to microleakage.

Key Words: Composite repair, Cojet, Er:YAG lazer, Al₂O₃ air abrasion, microleakage, self-adhesive composit resin

ÖZ

Amaç: Nanohibrit bir kompozit rezinin tamirinde sekiz farklı yüzey işlemi ve üç farklı kompozit rezinin mikrosızıntı üzerine etkisini değerlendirmektir.

Materyal ve Metot: Tamir işlemi için nanohibrit kompozit rezin Filtek Z550 (3M ESPE) ile hazırlanan standart boyutlardaki bloklar yüzey işlemlerine göre Grup 1 (kontrol), Grup 2 (frez), Grup 3 (frez+silan), Grup 4 (Al₂O₃), Grup 5 (Al₂O₃+silan), Grup 6 (tribokimyasal silika kaplama), Grup 7 (lazer), Grup 8 (lazer+silan) olmak üzere ayrıldı. Hazırlanan örnekler 5000 kez termal siklus işlemi ve ardından yüzey işlemleri uygulandı. Her grup tamir kompozitleri (Filtek Z550, G-aenial Flo (GC), Vertise Flow (Kerr)) uygulanmak üzere 3'er alt gruba ayrıldı. Tamir işleminden sonra örnekler tekrar termal siklus işlemine tabi tutuldu. Daha sonra mikrosızıntı testi yapıp veriler istatistiksel olarak değerlendirildi.

Bulgular: Her bir kompozit için yüzey işlemleri kendi arasında değerlendirildiğinde istatistiksel olarak farklılık yoktur (p>0,05). Her bir yüzey işlemi için kompozit rezinler kendi aralarında değerlendirildiğinde istatistiksel olarak farklılık yoktur (p>0,05).

Sonuç: Kompozit restorasyonların tamirinde yüzey işlemleri için ek cihaz ve maliyet gerektiren yöntemler mikrosızıntı yönünden farklılık yaratmamışlardır.

Anahtar kelimeler: Kompozit tamiri, Cojet, Er:YAG lazer, Al₂O₃ hava abrazyonu, mikrosızıntı, kendinden adezivli kompozit rezin

¹ Ankara Sincan Ağız ve Diş Sağlığı Merkezi, Ankara, Türkiye.

² Cumhuriyet Üniversitesi Diş Hekimliği Fakültesi Restoratif Diş Tedavisi AD., Sivas, Türkiye.

GİRİŞ

Kompozit restorasyonlar estetik özellikleri, standart kavite preparasyonu gerektirmemeleri, civa ile ilgili kaygıları ortadan kaldırmaları nedeni ile posterior bölgede amalgamdan fazla tercih edilir olmuştur.¹ Adeziv prosedür ve kompozit rezinlerdeki gelişmelerde çok büyük aşamalar kaydedilse de halen mikrosızıntı, aşınma, kırık, renklenme ve sekonder çürük gibi başarısızlıklar çeşitli nedenlerle oluşabilmektedir.² Bu gibi durumlarda restorasyonun tamamen yenilenmesi; zaman, daha fazla diş dokusu kaybı, pulpal travma ihtimali ve yüksek maliyet gibi dezavantajları da beraberinde getirecektir. Bu nedenlerle restorasyonunun yenilenmesi yerine daha konservatif bir yaklaşım olan tamir işlemine öncelik verilmesi önerilmektedir.^{3,4}

Tamir işleminin başarısı eski ve yeni kompozit arasındaki bağlanmanın gücüne bağlıdır. İki kompozit tabakası arasındaki bağlanma polimerize olmamış oksijen inhibisyon tabakası sayesinde gerçekleşir.^{5,6} Ancak yaşlanma ve su emilimi, oksijen inhibisyon tabakasının kalkmasına, doymamış çift karbon-karbon bağlarının azalmasına dolayısıyla tamir işlemi gerektiğinde eski ve yeni kompozit arasındaki bağlanma gücünün olumsuz etkilenmesine neden olur.^{7,8} Bu durumun önüne geçmek için tamir edilecek restorasyon yüzeyine makromekanik, mikromekanik ve kimyasal olmak üzere çeşitli yüzey işlemleri uygulanır.^{9,10} Frez, air abrazyon, lazer, asitleme gibi yöntemlerle yüzey pürüzlendirilerek mekanik bağlanma, adeziv rezin, silan gibi ajanlar uygulanarak ıslanabilirlik ve kimyasal bağlanma, tribokimyasal kaplama ile hem mekanik hem de kimyasal bağlanma arttırılmaya çalışılır.¹¹⁻¹³ Ancak halen en etkin kompozit tamir protokolü ile ilgili fikir birliğine varılamamıştır.¹⁴ Bütün bu yüzey işlemleri arasında elmas frez ile aşındırma ve ardından adeziv rezin uygulaması klinikte en yaygın kullanılan yöntemdir. Kompozitin elmas frezlerle pürüzlendirilmesinin yüzeyel tabakayı kaldırarak kompozitin yüzey enerjisini yükselttiği ve böylece tamir materyalinin mekanik

retansiyonunu arttırdığı bildirilmiştir.^{15,16} Yüzeyin pürüzlendirilmesi için alternatif bir metot olan air abrazyon uygulaması, cihaz içindeki haznede bulunan aşındırıcı alüminyum oksit partiküllerinin basınçlı hava yardımı ile dar bir tüpten geçirilerek yüzeye püskürtülmesidir.¹⁷ Ağrı hissini ve lokal anestezi ihtiyacı azaltması, ısı, vibrasyon, basınç, ses ve koku oluşturmaması, gibi avantajları vardır.¹⁸

Günümüz diş hekimliğinde kullanım alanı yaygın olan Er:YAG lazerler yumuşak doku tedavisi ve kavite preparasyonunun yanı sıra tamir işleminde yüzey hazırlığı için de kullanılmaktadırlar.^{19,20} Er:YAG lazer ışınması sırasında enerji, su molekülleri ve biyolojik dokunun su içeren bileşenleri tarafından seçici olarak soğurulmaktadır. Bu durum, suyun ve su bazlı organik bileşenlerin buharlaşmasıyla birlikte bu işlem esnasında ortaya çıkan ısı miktarına göre çeşitli termal etkiler ile sonuçlanmaktadır (Fototermal buharlaşma). Sert doku işlemlerinde su buharı üretimi, doku içindeki iç basıncın artmasını tetiklemekte ve mikropatlama adı verilen bir patlamayla genleşmeye sebep olmaktadır.²¹ Bu dinamik etkiler, dokunun çökmesine neden olarak termomekanik veya fotomekanik kesimin gerçekleşmesini sağlar. Er:YAG lazer ile sert doku kesiminde; inorganik bileşenlerin ısıyı biriktirmeye başlamasından önce, su ve su bazlı organik bileşenler, lazer enerjisini hızlı bir biçimde soğurmaya başlamaktadır.²²

Tamir işleminde mekanik preparasyona ek olarak adeziv ve silan gibi kimyasal ajanların da bağlanmayı arttırdığı bildirilmiştir.^{9,23} Silanın iki fonksiyonel grubu vardır. Silanol grubu kompozitin doldurucu partiküllerindeki silikaya bağlanırken metakrilat grubu rezindeki metakrilat grubu ile kopolimerize olur. Bu olay ilave polimerizasyon reaksiyonu ile gerçekleşir.^{24,25}

Tribokimyasal silika kaplama işlemi, kimyasal olarak daha reaktif bir yüzey elde edebilmek için silika kaplı alumina parçacıklarının basınç altında püskürtme ile

yüzeyle gömülmesidir ve rezinlerin restorasyona adezyonunu arttırmak için etkili bir yöntem olarak önerilmektedir.²⁶

Kompozit rezin ile bağlandığı yüzey arasında meydana gelen mikro aralıktan bakteriler, ağız sıvıları, moleküller, iyonlar ve hava geçişi gerçekleşmektedir. Bu durum mikrosızıntı olarak adlandırılmaktadır.²⁷ Mikrosızıntı ile beraber restorasyonda renklenme, sekonder çürükler, postoperatif ağrı ve pulpa iltihabı gibi komplikasyonlar, daha ileri durumlarda ise restoratif materyallerde kırılmalar ve restorasyon kaybı görülebilmektedir. Yeterli bir bağlanma arayüzdeki mikrosızıntıyı önleyebilmelidir.²⁸ Bu nedenle mikrosızıntı, tamir restorasyonlarının klinik başarılarının değerlendirilmesinde önemli bir parametredir.

Çalışmamızın amacı nanohibrit bir kompozit rezinin tamirinde, sekiz farklı yüzey işlemi ve üç farklı kompozit rezinin mikrosızıntı üzerine etkisinin incelemesidir.

Bu bağlamda sıfır hipotezlerimizi aşağıdaki gibi kurduk.

H₀₁: Her bir yüzey işlemi için kullanılan kompozit rezinler mikrosızıntı skorlarını etkilemez.

H₀₂: Her bir kompozit için kullanılan yüzey işlemleri mikrosızıntı skorlarını etkilemez.

MATERYAL VE METOT

Örneklerin Hazırlanması

Araştırmamızda kullanılan materyallerin içerikleri ve firma isimleri Tablo 1'de verilmiştir. Standart boyutlarda örnek hazırlanabilmesi için silikon ölçü maddesinde 4x4x4 ve 4x4x8 mm boyutlarında negatif boşluklar oluşturuldu. 4x4x4 mm'lik boşluk yaşlandırılacak örnekler için, diğeri yaşlandırılan örneklerin tamiri için kullanıldı. Filtek Z550 (3M ESPE, St Paul, MN, ABD) iki tabaka halinde 4x4x4 mm'lik boşluğa yerleştirilerek 500 mW/cm² ışık yoğunluğundaki halojen ışık kaynağı (Hilux

Ultra Plus, Benlioğlu Dental, Ankara, Türkiye) ile 20 sn polimerize edildi. Kompozit bloklar hazırlanırken yıpranan silikon ölçü boşlukları yenilendi. Bu şekilde, yüzey işlemleri uygulanıp tamir edilmek üzere 192 adet nanohibrit kompozit blok hazırlandı. Standart bir yüzey oluşturmak amacı ile örneklerin tamir işlemi için kullanılacak yüzeylerine su soğutması altında 15 sn boyunca sarı lastiklerle polisaj işlemi yapıldı (Reddish Stone, La Loggia, İtalya). Dört örnekte bir lastikler değiştirildi. Ardından 24 saat 37°C'de serum fizyolojikte bekletildi.

Tablo 1. Çalışmada kullanılan materyaller ve içerikleri

Materyal, üretici firma	İçerik
Filtek Z550 3M ESPE, Almanya	Bis-GMA, Bis-EMA, UDMA, PEGDMA, TEGDMA, silika, zirkonya/silika parçacıkları
Vertise Flow Kerr, ABD	GPDM, HEMA, 4-Metoksi fenol, Nano-iterbiyum florür, baryum cam, nano-boyutta koloidal silika, çinko oksit, aktivatör, stabilizatör ve renklendiriciler
G-aenial Flo GC, Japonya	UDMA, bis-MEPP, dimetakrilat, silikon dioksit, stronsiyum cam, lanthanoid florid, pigment, foto initatör
Clearfil SE Bond Kuraray, Japonya	Primer: MDP, HEMA, hidrofilik dimetakrilat, kamforokinon, N,N-Dietanol-p-toluidin, su Bond: MDP, Bis-GMA, HEMA, hidrofobik dimetakrilat, kamforokinon, N,N-Dietanol-p-toluidin, silanlanmış koloidal silika
Bis Silane BISCO, ABD	3-(trimetoksisilil) propil-2-metil-2-propenik asit, etanol

Yüzey işlemleri uygulanmadan önce kompozit bloklar termal siklus cihazında (Gökçeler Makine, Sivas, Türkiye) 5.000 kez ısıl döngüye tabi tutuldu. Termal siklus uygulaması örneklerin, sırasıyla 5°C ve 55°C ($\pm 2^\circ\text{C}$) sıcaklığındaki banyolarda transfer süresi 5 sn ve bekleme süresi 30 sn olacak şekilde gerçekleştirildi.

Yüzey İşlemlerinin Uygulanması

Kompozit bloklar farklı yüzey işlemleri uygulanmak üzere 8 gruba, bu sekiz grubun her biri de farklı kompozitlerle tamir görmek üzere üçer alt gruba (n=8) ayrıldı (Tablo 2). Böylece mikrosızıntı testi için toplamda 24 grup elde edildi.

Tablo 2. Gruplar

	Yüze İşlemleri	Tamir Kompozitleri
Filtek Z550	Grup 1: Kontrol	Filtek Z550 (Grup 1 Z550) G-aenial Flo Universal (Grup 1 GA) Vertise Flow (Grup 1 VF)
	Grup 2: Frez	Filtek Z550 (Grup 2 Z550) G-aenial Flo Universal (Grup 2 GA) Vertise Flow (Grup 2 VF)
	Grup 3: Frez+Silan	Filtek Z550(Grup 3 Z550) G-aenial Flo Universal (Grup 3 GA) Vertise Flow (Grup 3 VF)
	Grup 4: Al ₂ O ₃	Filtek Z550 (Grup 4 Z550) G-aenial Flo Universal (Grup 4 GA) Vertise Flow (Grup 4 VF)
	Grup 5: Al ₂ O ₃ +silan	Filtek Z550 (Grup 5 Z550) G-aenial Flo Universal (Grup 5 GA) Vertise Flow (Grup 5 VF)
	Grup 6: Tribokimyasal silika kaplama	Filtek Z550 (Grup 6 Z550) G-aenial Flo Universal (Grup 6 GA) Vertise Flow (Grup 6 VF)
	Grup 7: Lazer	Filtek Z550 (Grup 7 Z550) G-aenial Flo Universal (Grup 7 GA) Vertise Flow (Grup 7 VF)
	Grup 8: Lazer+silan	Filtek Z550 (Grup 8 Z550) G-aenial Flo Universal (Grup 8 GA) Vertise Flow (Grup 8 VF)

Aşağıda belirtilen yüze işlemleri küp şeklinde hazırlanan kompozit örneklerinin sadece tamir edilecek yüzeylerine uygulandı.

Grup 1 (Kontrol); Bu gruptaki örneklere herhangi bir işlem uygulanmadı.

Grup 2 (Frez); Her bir yüze su soğutması altında 2 mm çapında elmas fissür frez (837314111534012C, M&A Diatech, Heerbrugg, İsviçre) kullanılarak 5 kez aşındırıldı. Her 4 örnekten sonra grenlerinin aşınma ihtimaline karşı frez yenisi ile değiştirildi.

Grup 3 (Frez+silan); Frez uygulaması bir önceki gruptaki gibi yapıldı. Frezle pürüzlendirildikten sonra her bir örneğe ince bir tabaka silan (BIS-Silane, BISCO, Inc. 1100 W. Irving Park Rd. Schaumburg, IL 60193, ABD) uygulandı ve üretici talimatları doğrultusunda 30 sn bekletildi. Hava spreyi ile 5 sn kurutularak silan uygulaması bitirildi.

Grup 4 (Al₂O₃); Hazırlanan örnekler air abrazyon cihazı (Kavo Rondoflex 360, KaVo Dental GmbH · D 88400 Biberach, Germany) ile 2,5 bar hava basıncı ve su soğutması altında 50 µm partikül boyutlu Al₂O₃ tozu (Kavo, KaVo Dental GmbH · D 88400 Biberach, Germany) kullanılarak pürüzlendirildi. Püskürtme başlığı örneklere 5 mm mesafede ve dik açı yapacak şekilde tutuldu. Pürüzlendirme süresi 5 sn ile sınırlandırıldı.

Grup 5 (Al₂O₃+silan); Al₂O₃ uygulaması bir önceki gruptaki gibi yapıldı. Her bir örnek pürüzlendirildikten hemen sonra silan uygulamasına geçildi. Üretici talimatları doğrultusunda silan ince bir tabaka sürüldükten sonra 30 sn bekletildi ve hava spreyi ile 5 sn kurutuldu.

Grup 6 (Tribokimyasal silika kaplama); Cojet kullanılarak (3M ESPE AG · ESPE Platz 82229 Seefeld · Almanya) aynı firma tarafından cihaz için özel üretilen 30 µm partikül boyutlu toz (Cojet Sand, 3M ESPE AG · ESPE Platz 82229 Seefeld · Almanya) 2,5 bar hava basıncı ile püskürtüldü. Püskürtme başlığı örnek yüzeylerine 5 mm uzaklıkta ve dik açıyla tutuldu. Pürüzlendirme süresi 5 sn ile sınırlandırıldı. Her bir örneğe, pürüzlendirildikten hemen sonra silan uygulandı. Diğer gruplarda olduğu gibi silan ince bir tabaka olarak sürüldü, 30 sn bekletildi ve hava spreyi ile 5 sn kurutuldu.

Grup 7 (Lazer); Er:YAG lazer (Smart 2940D Plus, Deka Laser; Florence, İtalya) uygulamasında parametreler 150 mJ enerji düzeyi, 10 Hz frekans ve 700 ms uzun atım olarak belirlendi. Pürüzlendirme 10 mm mesafeden 10 sn boyunca uygulandı.

Grup 8 (Lazer+silan); Er:YAG lazer yüze işleminden sonra yukarıda anlatıldığı gibi silan uygulandı.

Kompozit Örneklerin Tamiri

Tamir için yüze işlemi uygulanan örnekler 3 alt gruba ayrıldı. Tamir kompozitleri Filtek Z550, G-aenial Flo (GC Dental Products Corp, Kasugai, Aichi 486-0844, Japonya) ve Vertise Flow (Kerr Italia, Salerno, İtalya) olarak belirlendi. Vertise Flow kendinden adezivli bir kompozit rezin sistem olduğu için Vertise Flow ile tamir edilecek örneklerde ayrıca adeziv sistem uygulanmadı. Diğer kompozit blokların işlem yüzeylerine ise tamir kompoziti eklenmeden hemen önce iki aşamalı kendinden asitli adeziv sistem (Clearfil SEBond, Kuraray Medical, Tokyo, Japan) uygulandı. Üretici

firmanın talimatları doğrultusunda primer aplikatör yardımı ile 20 sn uygulandı ve hava ile hafifçe inceltildi. Daha sonra adeziv başka bir aplikatör yardımı ile uygulandı ve o da hava ile hafifçe inceltirilerek ışıkla 10 sn polimerize edildi. Her bir örnek adeziv uygulandıktan hemen sonra 4x4x8'lik silikon ölçü boşluğuna ilk konumuna uygun olarak yerleştirildi. Ölçü boşluğunun kalan yarı hacmi de tamir kompozitleri ile dolduruldu. Bütün tamir kompozitleri 2 mm kalınlığında iki tabaka halinde yerleştirildi. Üst tabakanın işlem görmüş kompozit yüzeyine taşmaması için bitim sınırına dikkat edildi. Her bir tabaka 20 sn ışınıldı. Örnekler kalıplardan çıkarılarak tekrar 20 sn ışınıldı. Yukarıda anlatıldığı şekilde polisaj yapıldıktan sonra üst yüzey hariç diğer yüzeyler çift kat tırnak cilası ile kapatıldı.

Tamir işlemi gören kompozit rezin bloklara mikrosızıntı testinden önce termal siklus cihazında 1000 kez, 5°C ve 55°C ($\pm 2^\circ\text{C}$) sıcaklığındaki banyolarda transfer süresi 5 sn ve bekleme süresi 30 sn olacak şekilde ısı döngüsü uygulandı.

Mikrosızıntı Testi

Boya penetrasyon yöntemi için termal siklustan çıkarılan örnekler %0,5'lik konsantrasyonda bazik fuksin solüsyonunda 24 saat bekletildi. Örnekler yıkanıp kurutulduktan sonra tamir hattına dik olarak orta noktasından her iki yüzeyi de kesici olan separelerle ayrıldı. Bir örnekten elde edilen iki yüzeyde boya penetrasyonu tamir hattı boyunca stereomikroskop (SMZ 800, Nikon, Tokyo, Japonya) ile x40 büyütmede incelendi. Sonuçlar şu kriterlere göre skorlandı:

Skor 0; tamir ara yüzü boyunca hiç sızıntı yok.

Skor 1; tamir ara yüzü boyunca yarıya kadar sızıntı var.

Skor2; tamir ara yüzü boyunca yarıdan fazla sızıntı var.

Skor 3; tamir ara yüzünün tamamında sızıntı var.

İstatistiksel Değerlendirme

Verilerin analizi SPSS for Windows 11.5 paket programında yapıldı. Sürekli değişkenlerin dağılımı Kolmogorov Smirnov testiyle, varyansların homojenliği ise Levene testiyle araştırıldı. Tanımlayıcı istatistikler ortanca (en az- en çok) biçiminde gösterildi.


Gruplar arasındaki farklılıkların değerlendirilmesinde Kruskal Wallis testi kullanıldı. Aksi belirtilmedikçe $p < 0,05$ için sonuçlar istatistiksel olarak anlamlı kabul edildi. Olası bütün çoklu karşılaştırmalarda tip I hatayı kontrol edebilmek için Bonferroni Düzeltmesi yapıldı.

BULGULAR


Yüzey işlemleri ve materyallere göre mikrosızıntı skorları değerlendirildiğinde gruplar arasında istatistiksel olarak önemli farklılık yoktur ($p > 0,05$). Bütün gruplar ortalama Skor 0 sonucu göstermiştir (Tablo 3). Bir grubun dışında diğer bütün gruplar 0 (Resim 1) ve 1 skorunu (Resim 2) göstermişlerdir. Sadece bir grupta (Grup 1 VF) 2 skoru (Resim 3) görülmüş, skor 3'e hiçbir grupta rastlanmamıştır.

Tablo 3. Mikrosızıntı testine ait bulgular. Yüzey işlemleri sabit tutulduğunda materyaller arasında yapılan karşılaştırmalar, Kruskal Wallis testi, Bonferroni Düzeltmesine göre $p < 0,00625$ için sonuçlar istatistiksel olarak anlamlı kabul edildi. Materyaller sabit tutulduğunda yüzey işlemleri arasında yapılan karşılaştırmalar, Kruskal Wallis testi, Bonferroni Düzeltmesine göre $p < 0,017$ için sonuçlar istatistiksel olarak anlamlı kabul edildi.

	Z550+Z550	Z550+GA	Z550+VF	p-değeri †
Grup 1 (Kontrol)	0 (0-0)	0 (0-1)	0 (0-2)	0,007
Grup 2 (Frez)	0 (0-1)	0 (0-1)	0 (0-1)	0,804
Grup 3 (Frez+sılan)	0 (0-0)	0 (0-1)	0 (0-0)	0,130
Grup 4 (Al_2O_3)	0 (0-1)	0 (0-1)	0 (0-1)	0,318
Grup 5 (Al_2O_3 +sılan)	0 (0-0)	0 (0-0)	0 (0-0)	1,000
Grup 6 (Tribokimyasal silika kaplama)	0 (0-0)	0 (0-1)	0 (0-0)	0,044
Grup 7 (Lazer)	0 (0-1)	0 (0-1)	0 (0-1)	0,358
Grup 8 (Lazer+sılan)	0 (0-1)	0 (0-1)	0 (0-1)	0,056
p-değeri ‡	0,155	0,781	0,110	



Resim 1. Skor 0



Resim 2. Skor 1



Resim 3. Skor 2

TARTIŞMA

Bu çalışmada kompozit restorasyon tamirinde sekiz farklı yüzey işlemi ve biri eski kompozit ile aynı diğer ikisi farklı olmak üzere üç kompozit rezinin (nanohibrit, kendinden adezivli, yüksek dolduruculu) mikrosızıntıya etkisi değerlendirilmiştir. Mikrosızıntı testi sonucunda elde ettiğimiz verilere göre sıfır hipotezlerimiz; “Her bir yüzey işlemi için kullanılan kompozit rezinler mikrosızıntı skorlarını etkilemez.” ve “Her bir kompozit resin için kullanılan yüzey işlemleri mikrosızıntı skorlarını etkilemez.” kabul edilmiştir. En yüksek mikrosızıntı skoru olan 2,

yalnızca Grup 1 VF’de (kontrol, Filtek Z550+Vertise Flow) tek bir örnekte görülmüştür.

İstatistiksel olarak fark oluşturmamakla birlikte skor 2 sadece kontrol grubunda Filtek Z550’nin Vertise Flow ile tamir edildiği grupta görülmüştür. Vertise Flow gliserol fosfat dimetakrilat (GPDM) monomeri içerir. GPDM hidrofilikliği yüksek güçlü asitleme etkisi olan bir monomerdur.²⁹ Geleneksel kompozitlerle karşılaştırıldığında self-adeziv materyallerin hidrofilik monomerleri su absorpsiyonuna daha eğilimlidir. Bu durum matriksin şişmesine ve polimer zincirin kırılmasına neden olarak kendinden adezivli kompozitlerin mekanik özelliklerini zayıflatır. Böylece termal siklus gibi yaşlandırma yöntemlerinden sonra kompozit-kompozit arası bağlanma dayanımları azalır.^{30,31}

Kullandığımız kompozitlerin hepsi için yüzey işlemleri arasındaki farklılık önemsiz çıkmıştır. Hosani ve ark. Er:YAG lazer ve elmas frezle açtıkları kaviterlerde mikrosızıntı değerlendirmesi yapmışlar, gruplar arasında istatistiksel fark olmadığını bildirmişlerdir. Uygulamaların zaman kıyaslamasını da yapan yazarlar lazerin frezden birkaç kat uzunlukta zaman aldığını da belirtmişlerdir.³² Kompozit yüzeyine Er:YAG lazer uygulanan başka çalışmalarda da lazerin yüzeyde, dental dokulardakinin aksine iyi sınırlı, konik mikrokaviterlerden oluşan uniform bir pürüzlülük oluşturduğu, bunun mekanik bağlanma için istenmeyen bir durum olduğu bildirilmiştir.^{33,34,35} Tabatabaei ve ark.³⁶ yaptığı araştırmada frez preparasyonunun hem mikro hem de makro-retantif alanlar oluşturarak bağlanma için daha güvenli yüzeyler yarattığı sonucuna varmıştır. Yaman ve ark.’da³⁷ yüzey işlemi olarak Er:YAG lazer ve elmas frezi karşılaştırdıkları çalışmalarında bizim çalışmamıza paralel olarak gruplar arasında mikrosızıntı açısından istatistiksel fark bulamamışlardır. Vertise Flow’ un yüzey işlemi uygulanan gruplarında mikrosızıntı skorları

biraz daha iyidir. Bu kompozit rezinin kullanıldığı gruplarda ek adeziv sistem uygulaması yapılmamıştır. Daha önce yapılan pek çok çalışmada Vertise Flow'un bağlanma dayanımı diğer gruplara göre özellikle ek adeziv kullanılmadığında daha düşük çıkmıştır.³⁸⁻⁴⁰ Bizim çalışmamızda frez+silan, Al₂O₃+silan ve tribokimyasal kaplama ek yüzey işlemleri bu kompozitin bağlanma dayanımını arttırarak mikrosızıntı skorlarını kontrol grubuna göre düşürmüş olabilir.

Çalışmamızda incelediğimiz diğer bir yüzey işlemi de Al₂O₃ ile hava abrazyonudur. Kompozit yüzeyine air abrazyon uygulandığında alüminyum oksit partiküllerinin kinetik enerjisi ısıya dönüşerek matriks doldurucu bağlantısında degregasyona ve doldurucuların organik matriksten kopmasına neden olur. Böylece eski restorasyonun yüzeyinde bağlantı için uygun bir yüzey oluşur.⁴¹ Bir çalışmada⁴² air abrazyon uygulanan yüzeylerin bağlanma için daha elverişli olduğunu belirtilirken başka bir çalışmada⁴³ frez ile air abrazyona göre daha yüksek bağlanma dayanımı elde ettikleri bildirilmiştir.

Tribokimyasal silika kaplama yöntemi bağlanma dayanımını arttırmada iki farklı mekanizma ile Al₂O₃ ile air abrazyon yönteminden ayrılır.^{12,44} Birincisi, Cojet ile yüzeye püskürtülen silika bağlanma alanının artmasını sağlar. İkincisi, metotla kombine kullanılan silan ek olarak kimyasal bağlanma sağlar. Böylelikle Cojet sistemi bağlama dayanımını arttırmada avantajlı hale gelir. Rodrigues ve ark. SEM ile inceledikleri örneklerde, tribokimyasal silika kaplama yönteminde daha düz ancak topografik olarak mekanik retansiyona daha uygun yüzeyler görüldüğünü söylemişlerdir.¹² Ancak bizim çalışmamızda mikrosızıntı yönünden fark yaratmamıştır. Wendler ve ark.'da⁴⁵ (elmas frez, fosforik asit, silan, tribokimyasal silik kaplama) beş farklı yüzey işlemini

karşılaştırdıkları çalışmalarında bağlanma dayanımı açısından fark bulamamışlardır.

Tamir görecekt kompozit rezinin markasını veya içeriğini bilmek çoğu kez mümkün değildir. Bu nedenle çalışmamızda eski kompozit ile aynı ve iki tane de farklı kompozit kullandık. Farklı kompozitler iyi ıslatma özelliği ile kavite duvarlarına kolayca adapte olabilen akışkan kompozitlerden (G-aenial Flo ve Vertise Flow) tercih edildi.⁴⁵ Lazaridou ve ark. G-aenial Flo'nun oklüzal kontak alanlarında amalgam tamiri için güvenilir olduğunu ifade etmiştir.⁴⁶ Bizim çalışmamızda da G-aenial Flo'nun mikrosızıntı skor ortalaması sıfırdır ve hiçbir örneğinde skor 2'ye rastlanmamıştır. G-aenial flo'nun akışkanlık özelliği ile yüzeyi iyi ıslatması, uygulama sırasında hava kabarcığı oluşma riskinin azalması ve stresi absorbe edebilmesi mikrosızıntı sonuçlarını olumlu etkilemiş olabilir.^{47,48}

Çalışmamızda silan kullanılan ve kullanılmayan grupların mikrosızıntı skorları arasında anlamlı bir farklılık bulunmamıştır. Literatürde silan ile ilgili çelişen sonuçlar vardır. Mobarak ve El-deeb siloran bazlı kompozitlerde yaptıkları tamir çalışmalarında silanın sızıntıya etkisinin olmadığını belirtmişlerdir.⁴⁹ Silanın bağlanmaya olumlu etkisinden bahseden araştırmacılar, bağlanma dayanımının rezin ve doldurucular arasında kurulan kimyasal siloksan bağ ile arttığını ifade ederler.^{8,50} Silanın ayrıca yüzey ıslanabilirliğini artırarak, adeziv rezinin infiltrasyonunu kolaylaştırdığı bildirilmiştir.²⁴ Özellikle tribokimyasal silika kaplama işleminden sonra silan kullanımının bağlanmayı arttırdığı ifade edilmiştir.⁵¹⁻⁵³ Ancak bizim çalışmamızda silika kaplama uygulanan gruplarda da mikrosızıntı açısından fark oluşturmamıştır. El Askary gerçekleştirdiği tamir çalışmasında, silanın bağlanma dayanımındaki etkisizliğinin kalın ara yüz tabakası nedeniyle oluşabileceğini söylemişlerdir.⁵⁴ Bizim sonuçlarımızda bu kalın tabaka ile birlikte, silan-zirkonyum ilişkisi ile

açıklanabilir. Filtek Z550 zirkonyum doldurucu içermektedir. Silan zirkonyum ile reaksiyona girmediğinden zirkonyum doldurucular rezin matrikse mikro poroziteler aracılığı ile tutunur.⁵⁵ Dolayısıyla zirkonyum doldurucular nedeni ile silan tam olarak etkisini gösterememiş olabilir.

Çalışmamızda yaşlandırma yöntemi olarak en sık kullanılan yapay yaşlandırma yöntemlerinden termal siklusu tercih ettik. İSO TR 11450 standartları örneklere 5°C ve 55°C deki su banyolarında 500 siklus uygulanmasını uygun bir yapay yaşlandırma test biçimi olarak göstermiştir.⁵⁶ Gün içinde ağız ortamında 20-50 kez termal siklusun tekrarlandığı düşünülmektedir.⁵⁷ Addison ve ark.⁵⁸ ise, aşırı ısıl değişimlerin günde en fazla 10 defa gerçekleştiğini ve 3500 defalık ısıl çevirimin yaklaşık olarak 1 yıllık klinik kullanıma eşit olacağını bildirmişlerdir. Mikrosızıntı çalışmalarında kullanılan siklus sayısı literatürde 100-50000 arasında değişkenlik göstermektedir. Crim ve ark.⁵⁹ ve Gale ve ark.⁵⁷ siklus sayısı ile süresinin mikrosızıntıyı etkilemediğini belirtmişlerdir. Literatürdeki bu bilgiler dikkate alınarak bizim çalışmamızda üzerine tamir işlemi yapacağımız kompozit bloklarını yaşlandırmak için termal siklus sayısı 5000 seçilirken, tamir işlemi sonrası 1000 olacak şekilde belirlenmiştir.

SONUÇLAR

Çalışmamız sınırları içerisinde kompozit restorasyonların tamirinde farklı yüzey işlemleri ve kompozit rezinler arasında mikrosızıntı açısından fark yoktur. Tüm yüzey işlemleri için silan kullanımı ve tamir kompozitinin eski kompozit ile aynı ya da farklı olması mikrosızıntı skorlarında anlamlı bir değişiklik oluşturmamıştır. Ek materyal-cihaz kullanımını gerektiren ve buna bağlı olarak da maliyeti arttıran yüzey işlemleri yerine daha pratik olan ve kliniklerde hali hazırda bulunan frez ile pürüzlendirme ve adeziv rezin kullanımı önermekteyiz. Ek olarak tamir işlemi eski kompozit rezinden farklı geleneksel ya da

kendinden adezivli akışkan kompozitler ile de yapılabilir. Ancak bu sonuçların klinik araştırma sonuçları ile de desteklenmesine ihtiyaç vardır.

KAYNAKLAR

1. Rasines Alcaraz MG, Veitz-Keenan A, Sahrman P, Schmidlin PR, Davis D, and Iheozor-Ejiofor Z. Direct composite resin fillings versus amalgam fillings for permanent or adult posterior teeth. The Cochrane Database of Syst Rev 2014; 31: Cd005620.
2. Tezvergil A, Lassila LV, and Vallittu PK. Composite-composite repair bond strength: effect of different adhesion primers. J Dent 2003; 31: 521-525.
3. Denehy, Bouschlicher, and Vargas, Intraoral repair of cosmetic restorations. Dent Clin of North Am. 1998; 42(4): 719-737
4. Tyas MJ, Anusavice KJ, Frencken JE, and Mount, GJ. Minimal intervention dentistry--a review. FDI Commission Project 1-97. Int Dent J 2000; 50(1): 1-12.
5. Gordan VV, Mjor IA, Blum IR, and Wilson N. Teaching students the repair of resin-based composite restorations: a survey of North American dental schools. Journal of the American Dental Association 2003; 134(3): 317-323; quiz 338-319.
6. Gordan VV, Mondragon E, and Shen C. Replacement of resin-based composite: evaluation of cavity design, cavity depth, and shade matching. Quintessence Int 2000; 33(4): 273-278.
7. Cavalcanti AN, De Lima AF, Peris AR, Mitsui FH, and Marchi GM, Effect of surface treatments and bonding agents on the bond strength of repaired composites. J Esthet Restor Dent 2007; 19(2): 90-98.
8. Jafarzadeh Kashi TS, Erfan M, Rakhshan V, Aghabaigi N, and Tabatabaei FS. An in vitro assessment of the effects of three surface treatments on repair bond strength of aged composites. Oper Dent 2011; 36(6): 608-617.

9. Bouschlicher MR, Reinhardt JW, and Vargas MA Surface treatment techniques for resin composite repair. *Am J Dent* 1997; 10(6): 279-283.
10. Brosh T, Pilo R, Bichacho N, and Blutstein R. Effect of combinations of surface treatments and bonding agents on the bond strength of repaired composites. *J Prosthet Dent* 1997; 77(2): 122-126.
11. Duran İ, Ural Ç, Yılmaz B, and Tatar N. Effects of Er:YAG Laser Pretreatment with Different Energy Levels on Bond Strength of Repairing Composite Materials. *Photomed Laser Surg.* 2015; 33(6): 320-325.
12. Rodrigues SA Jr, Ferracane JL, and Della Bona A. Influence of surface treatments on the bond strength of repaired resin composite restorative materials. *Dent Mater* 2009 25(4): 442-451.
13. Nassoohi N, Kazemi H, Sadaghiani M, Mansouri M, and Rakhshan V. Effects of three surface conditioning techniques on repair bond strength of nanohybrid and nanofilled composites. *Dent Res J* 2015; 12(6): 554-561.
14. Gupta S, Parolia A, Jain A, Kundabala M, Mohan M, and De Moraes Porto ICC. A comparative effect of various surface chemical treatments on the resin composite-composite repair bond strength. *J Indian Soc Pedod and Prev Dent* 2015; 33(3): 245-249.
15. Valente LL, Silva MP, Fonseca AS, Munchow EA, Isolan CP, and Moraes RR. Effect of Diamond Bur Grit Size on Composite Repair. *The journal of adhesive dentistry* 2015; 17(3): 257-263.
16. Kimyai S¹, Mohammadi N, Navimipour EJ, Rikhtegaran S. Comparison of the effect of three mechanical surface treatments on the repair bond strength of a laboratory composite. *Photomed Laser Surg.* 2010 Oct;28 Suppl 2:S25-30. doi: 10.1089/pho.2009.2598.
17. Liebenberg WH. A useful evacuation aid for intraoral air-abrasive devices. *Quintessence Int* 1997; 28(2): 105-108.
18. Yeşilyurt A. Kompozit rezinlerin mine ve dentine makaslama dayanımları üzerine air-abrazyonun etkisi. *A.Ü. Diş Hek. Fak. Derg* 2005; 32(3): 191-200.
19. Ader C and Krejci I. Indications and limitations of Er:YAG laser applications in dentistry. *Am J Dent* 2006; 19(3): 178-186.
20. Eren D, Bektaş Ö, Siso Ş. Can Er:YAG laser be an alternative to conventional methods for repairing composite resins? *Cumhuriyet Dent J* 2013;16(2): 125-132.
21. Coluzzi DJ. An overview of laser wavelengths used in dentistry. *Dent Clin North Am* 2000; 44(4): 753-765.
22. Göknar, Er:YAG laser tekniği ile diş sert dokusunda kavite oluşturulmasına ilişkin çalışma şartlarının incelenmesi ve optimal parametrelerin tayini, in *Nükleer Mühendislik*. 2006, İstanbul Teknik Üniversitesi: İstanbul. p. 1-105.
23. Papacchini F, Dall'oca S, Chieffi N, Goracci C, Sadek FT, Suh BI, Tay FR, Ferrari M. Composite to composite bond strength in the repair of micro-filled hybrid resin: Effect of surface treatment and oxygen inhibition. *Journal of Adhesive Dentistry* 2007;9(1):25-31
24. Goracci C, Raffaelli O, Monticelli F, Balleri B, Bertelli E, and Ferrari M. The adhesion between prefabricated FRC posts and composite resin cores: microtensile bond strength with and without post-silanization. *Dental materials* 2005; 21(5): 437-444.
25. Blatz MB, Sadan A, and Kern M. Resin-ceramic bonding: a review of the literature. *J Prosthetic Dent* 2003; 89(3): 268-274.
26. <http://Multimedia.3m.Com/Mws/Media/219219o/Cojet-Product-Dossier-in-English.Pdf>. [cited 2016].

- 27.**Altun C. Restoratif diş hekimliğinde mikrosızıntı. *Gülhane Tıp Dergisi* 2004; 46: 264-269.
- 28.**Hadavi F, Hey JH, Ambrose ER, and Elbadrawy HE. Effect of different adhesive systems on microleakage at the amalgam/composite resin interface. *Oper Dent* 1993; 18(1): 2-7.
- 29.**Wang R, Shi Y, Li T, Pan Y, Cui Y, Xia W. Adhesive interfacial characteristics and the related bonding performance of four selfetching adhesives with diferent functional monomers applied to dentin. *J Dent.* 2017;62:72–80
- 30.**Wei Y, Silikas N, Zhang Z, Watts D. Hygroscopic dimensional changes of self-adhering and new resin-matrix composites during water sorption/desorption cycles. *Dent Mater.* 2011;27:259–66.
- 31.**Brueckner C, Schneider H, Haak R. Shear bond strength and tooth-composite interaction with self-adhering fowable composites. *Oper Dent* 2017;42:90–100.
- 32.**Hossain M, Yamada Y, Nakamura Y, Murakami Y, Tamaki Y, and Matsumoto K. A study on surface roughness and microleakage test in cavities prepared by Er:YAG laser irradiation and etched bur cavities. *Lasers Med Sci* 2003; 18(1): 25-31.
- 33.**Lizarelli FZ. Ablation rate and morphological aspects of composite resins exposed to Er:YAG laser. *J Oral Laser Appl* 2005; 5(3): 151-160.
- 34.**Rossato DM, Bandeca MC, Saade EG, Lizarelli RFZ, Bagnato VS, Saad JRC. Influence of Er:YAG laser on surface treatment of aged composite resin to repair restoration. *Laser Physics* 2009;19:2144-2149.
- 35.**Batista G, Kamozaki M, Gutierrez N, Caneppele T, Torres C. Effect of different surface treatments on composite repairs. *J Adhes Dent* 2015; 17(5): 421-426.
- 36.**Hasani Tabatabaei M, Alizade Y, Taalim S. Effect of various surface treatment on repair strength of composite resin. *J Dent* 2004; 1:5-11
- 37.**Yaman BC, Guray BE, Dorter C, Gomec Y, Yazicioglu O, and Erdilek D. Effect of the erbium:yttrium-aluminum-garnet laser or diamond bur cavity preparation on the marginal microleakage of class V cavities restored with different adhesives and composite systems. *Lasers med sci* 2012; 27(4): 785-794.
- 38.**Peterson J, Rizk M, Hoch M, Wiegand A. Bonding Performance of self-adhesive flowable composites to enamel, dentin and a nano-hybrid composite. *Odontology* 2018; 106(2): 171-180
- 39.**Hamdy TM. Interfacial microscopic examination and chemical analysis of resin-dentin interface of self-adhering flowable resin composite. *Version 3. F1000Res* 2017 ;6 :1688
- 40.**Tuloglu N, Sen Tunc E, Ozer S, Bayrak S. Shear bond strength of self-adhering flowable composite on dentin with and without application of an adhesive system. *J Appl Biomater Funct Mater* 2014; 5(12): 97-101.
- 41.**D'Arcangelo C, Vanini L. Effect of three surface treatments on the adhesive properties of indirect composite restorations. *J Adhes Dent* 2007; 9: 319-26.
- 42.**Hemadri M, Saritha G, Rajasekhar V, Pachlag KA, Purushotham R, and Reddy UK. Shear Bond Strength of Repaired Composites Using Surface Treatments and Repair Materials: An In vitro Study. *J Int Oral Health* 2014; 6(6): 22-25.
- 43.**Bonstein T, Garlapo D, Donarummo J Jr., Bush PJ. Evaluation of varied repair protocols applied to aged composite resin. *J Adhes Dent* 2005; 7: 41-9.
- 44.**Ozcan M, Barbosa SH, Melo RM, Galhano GA, and Bottino MA. Effect of surface conditioning methods on the microtensile bond strength of resin composite to composite after aging conditions. *Dent Mater* 2007; 23(10): 1276-1282.

45. Frankenberger R, Lopes M, Perdigao J, Ambrose WW, and Rosa BT. The use of flowable composites as filled adhesives. *Dental materials* 2002; 18(3): 227-238.
46. Lazaridou D, Belli R, Petschel A, and Lohbauer U. Are resin composites suitable replacements for amalgam? A study of two-body wear. *Clin Oral Investig* 2015; 19(6): 1485-1492.
47. Papacchini F, Radovic I, Magni E, Goracci C, Monticelli F, Chieffi N, Polimeni A, Ferrari M. Flowable composites as intermediate agents without adhesive application in resin composite repair. *Am J Dent* 2008; 21: 53-58.
48. Wendler M, Belli R, Panzer R, Skibbe D, Petschelt A, Lohbauer U. Repair Bond Strength of Aged Resin Composite after Different Surface and Bonding Treatments. *Materials (Basel)* 2016; 7:9(7).
49. Mobarak E and El-Deeb H. Two-year interfacial bond durability and nanoleakage of repaired silorane-based resin composite. *Oper Dent* 2013; 38(4): 408-418.
50. Mitsaki-Matsou H, Karanika-Kouma A, Papadoyiannis Y, and Theodoridou-Pahine S. An in vitro study of the tensile strength of composite resins repaired with the same or another composite resin. *Quintessence international* 1991; 22(6): 475-481.
51. Hannig C, Laubach S, Hahn P, Attin T. Shear bond strength of repaired adhesive filling materials using different repair procedures. *J Adhes Dent* 2006; 8: 35-40
52. Ozcan M, Barbosa SH, Melo RM, Galhano GA, Bottino MA. Effect of surface conditioning methods on the microtensile bond strength of resin composite to composite after aging conditions. *Dent Mater* 2007; 23: 1276-1282.
53. Rinastiti M, Ozcan M, Siswomihardjo W, Busscher HJ. Immediate repair bond strengths of microhybrid, nanohybrid and nanofilled composites after different surface treatments. *J Dent* 2010; 38: 29-3.
54. El-Askary FS, El-Banna AH, van Noort R. Immediate vs delayed repair bond strength of a nanohybrid resin composite. *J Adhes Dent* 2012; 14(3): 265-74
55. Derand P and Derand T. Bond strength of luting cements to zirconium oxide ceramics. *Int J Prosthodont* 2000; 13(2): 131-5.
56. Çöteli, Farklı termosiklus döngüsü ve hızlandırılmış yaşlandırmanın tek basamaklı adeziv sistemlerin dentine bağlanması üzerine olan etkisi,, in Sağlık Bilimleri Enstitüsü. 2008, Yeditepe Üniversitesi: İstanbul. p. 67.
57. Gale MS, Darvell BW. Thermal cycling procedures for laboratory testing of dental restorations. *J Dent* 1999; 27: 89-99.
58. Addison O, Fleming GJ, Marquis PM. The effect of thermocycling on the strength of porcelain laminate veneer (PLV) materials. *Dent Mater* 2003; 19: 291-7.
59. Crim GA, Shay JS. Microleakage pattern of a resin-veneered cavity liner. *J Prosthet Dent* 1987; 58: 273-6.

Sorumlu Yazar

Diğdem Eren

Cumhuriyet Üniversitesi

Diş Hekimliği Fakültesi

Restoratif Diş Tedavisi AD

SİVAS

Tel : +90 346 2191010/2791

E-mail : digdemisin@hotmail.com



THE EFFECT OF DIFFERENT FACTORS ON STRESS DISTRIBUTION IN A MOLAR TOOTH

Bir Molar Dişin Stres Dağılımı Üzerinde Farklı Faktörlerin Etkisi

Mehmet Sami GULER¹, Sadri SEN²

Makale Kodu/Article Code : 440789

Makale Gönderilme Tarihi : 04.07.2018

Kabul Tarihi : 24.07.2018

ABSTRACT

Objectives: The aim of present study was to evaluate the effect of different factors on the stress distribution of a molar tooth by finite element analysis.

Materials and Methods: A 3D tooth model of a maxillary molar tooth was created for present study. The cavities (Class I and Class II) were created in the computer model. The cavities were restored with three different restorative materials (resin composite, amalgam and glass ionomer cement) in the computer model. Two thermal load (5 °C and 55 °C) and two mechanical load (mechanical singular load-perpendicular and mechanical distributed load-perpendicular) used in this study. Twelve study groups were created. The von Mises stress distribution was evaluated.

Results: Von Mises stress values were not statistically significant different among the groups for restorative material and mechanical load factors ($p>0.05$) while there were statistically significant differences among the groups for cavity geometry and thermal load factors ($p<0.05$).

Conclusions: Within the limitations of our study, the higher Von Mises stress values were found in Class I cavity for cavity geometry and 5°C for thermal load.

Keywords: Cavity geometry, restorative material, thermal load, mechanical load, finite element analysis.

ÖZ

Amaç: Bu çalışmanın amacı bir molar dişin stres dağılımı üzerinde farklı faktörlerin etkisini sonlu elemanlar analizi ile değerlendirmektir.

Gereç ve Yöntem: Çalışma için bir maksiller molar dişin 3 boyutlu diş modeli oluşturuldu. Kaviteler (Sınıf I ve Sınıf II) bilgisayar ortamında oluşturuldu. Kaviteler bilgisayar ortamında üç farklı restoratif material ile (kompozit rezin, amalgam ve cam iyonomer siman) restore edildi. Bu çalışma için iki termal yük (5 °C ve 55 °C) ve iki mekanik yük (mekanik tekil yük-dik ve mekanik yayılı yük-dik) kullanıldı. On iki çalışma grubu oluşturuldu. Von Mises stres dağılımı değerlendirildi.

Bulgular: Restoratif materyal ve mekanik yük faktörleri için gruplar arasında Von Mises stres değerleri istatistiksel olarak anlamlı bir farklılık göstermezken ($p>0,05$), kavite geometrisi ve termal yük faktörleri için gruplar arasında istatistiksel olarak anlamlı bir farklılık vardı ($p<0,05$).

Sonuçlar: Çalışmamızın sınırları dahilinde, en yüksek Von Mises stres değeri kavite geometrisi için Sınıf I kavitede ve termal yük için 5 °C'de bulundu.

Anahtar Kelimeler: Kavite geometrisi, restoratif material, termal yük, mekanik yük, sonlu elemanlar analizi.

¹ Ordu University, Department of Machinery and Metal Technologies, Vocational School of Technical Sciences, Ordu, Turkey

² Ataturk University, Faculty of Mechanical Engineering, Department of Construction and Manufacturing, Erzurum, Turkey.

INTRODUCTION

The aim of restorative dentistry is to provide a natural teeth appearance, accurate diagnose and treatment. Different restorative materials may be used for the dental treatment.¹ However, the restorative materials present certain drawbacks such as thermal and mechanical stress. Restored teeth are exposed to mechanical stress at different levels since occlusal forces, and the durability of the restorations mostly depends upon these stresses.

In addition, many factors such as the type of the restorative material, cavity geometry, and thermal fluctuations, affect the stress that occurs on restored teeth.² The oral cavity can be exposed to thermal fluctuations. These rapid fluctuations create thermal stress.^{3,4}

The Finite Element Analysis (FEA) method, which uses advanced computing and modeling techniques, provides a reliable means of determining the biomechanics of restorative materials. Computer-aided quantitative studies have also become a very important tool in dentistry, particularly in the identification of the source of failure, offering satisfying and reliable results when combined with FEA. In addition, experiments that could not be performed on patients can be done in the computer environment using FEA. Moreover, analyzing the durability of the restorative materials when exposed to occlusal forces by this method could be quick and cost-effective.^{5,6}

There are different studies related to the effect of variable cavity geometry, occlusal forces and thermal changes on stress distribution.⁶⁻¹¹ However, study related to thermal stress distribution at tooth-restorative material interface bonding has been very limited.⁶ The aim of present study was to evaluate the effect of different factors such as cavity geometry, restorative material, thermal and mechanical load factors on the stress distribution of a molar tooth.

MATERIAL AND METHOD

Modeling of Tooth

An extracted maxillary left first molar tooth was used for the 3D tooth model. The 3D tooth model procedures were made according to Toparli *et al.*⁴ and Hashemipour *et al.*⁷ recommendations (Fig. 1).

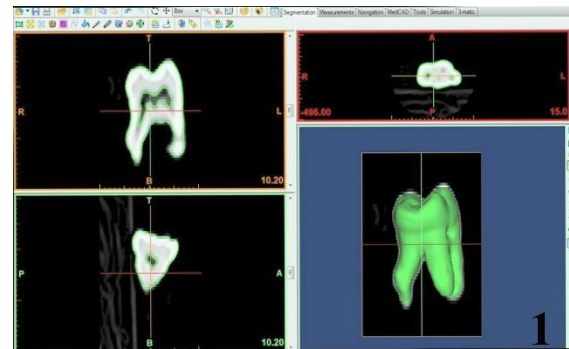


Figure 1: Preparing a three-dimensional model using the Mimics program before Solidworks program.

Meshing

Mesh (72.621 elements and 104.665 nodes) was obtained automatically using the ANSYS 13 Workbench (Swanson Ansys Inc., Houston, USA). Figure 2 is shown the meshed model.

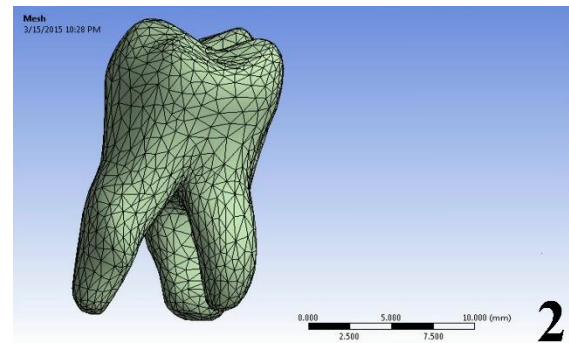


Figure 2: The meshed model.

Cavity Preparation

The cavities were prepared in the computer model.

Class I cavity (5x3x2 mm³) was prepared on the occlusal surface of the tooth (Fig. 3).

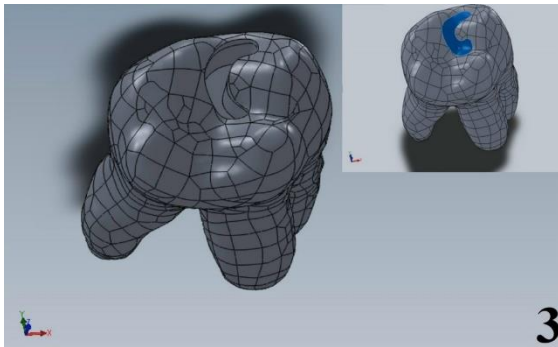


Figure 3: The preparation of Class I cavity.

Class II cavity ($5 \times 3 \times 2 \text{ mm}^3$) was prepared with the cervical margin 1 mm below the cementum-enamel junction (Fig. 4).

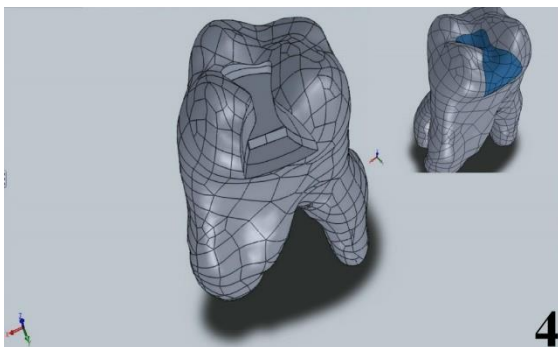


Figure 4: The preparation of Class II cavity.

The cavity was restored with three different restorative materials (resin composite, amalgam and glass ionomer cement) in the computer model. The restorative materials commonly used for restoration in dentistry are preferred for this study. Table 1 presents the mechanical properties of restorative materials used in present study.^{4,7}

Table 1. The mechanical and thermal properties of the tooth and the restorative materials used in this study.

Materials	Modulus of Elasticity (GPa)	Poisson's Ratio	Specific Heat (J/kg °C)	Thermal Expansion Coefficient ($1/^\circ\text{C}$)	Thermal Conductivity (W/m °C)	Densi (kg/m ³)
Enamel	80	0.33	750	11×10^{-6}	0.84	280
Dentine	20	0.31	1302	11.4×10^{-6}	0.63	200
Pulp	0.003	0.45	4200	180.1×10^{-6}	0.0418	100
Resin Composite	15	0.24	820	34×10^{-6}	1.26	200
Glass Ionomer	10.8	0.30	1177	35×10^{-6}	0.615	210
Amalgam	35	0.35	240	25×10^{-6}	23.1	1050

Thermal and Mechanical Load

To simulate the sudden intake of hot and cold food and drink, two thermal load (5°C and 55°C) used in this study.¹² The tooth was assumed to initially have a uniform temperature of 36.5°C , the temperature was assumed to change from 36.5 to 5 or 55°C , respectively.

Mechanical loads were within the ranged 10 - 431 N in the intraoral.¹³ Two mechanical load (mechanical singular load-perpendicular and mechanical distributed load-perpendicular) used in this study. Mechanical singular or distributed loads of 270 N at an angle of 90° were then applied on the restorative material in the longitudinal axis of the tooth at temperatures of 5 or 55°C .

The von Mises stress distribution was calculation using ANSYS 13 Workbench software.

Study Groups

Table 2 presents the twelve experimental groups created in present study.

Table 2: The distribution of study groups

Study Groups	Cavity Geometry	Restorative Material	Thermal Load	Mechanical Load
Group 1	Group 1.1	Class I Composite Resin	5°C	Mechanical Singular Load-Perpendicular
	Group 1.2	Class I Composite Resin	5°C	Mechanical Distributed Load-Perpendicular
Group 2	Group 2.1	Class I Composite Resin	55°C	Mechanical Singular Load-Perpendicular
	Group 2.2	Class I Composite Resin	55°C	Mechanical Distributed Load-Perpendicular
Group 3	Group 3.1	Class II Composite Resin	5°C	Mechanical Singular Load-Perpendicular
	Group 3.2	Class II Composite Resin	5°C	Mechanical Distributed Load-Perpendicular
Group 4	Group 4.1	Class II Composite Resin	55°C	Mechanical Singular Load-Perpendicular
	Group 4.2	Class II Composite Resin	55°C	Mechanical Distributed Load-Perpendicular
Group 5	Group 5.1	Class I Amalgam	5°C	Mechanical Singular Load-Perpendicular
	Group 5.2	Class I Amalgam	5°C	Mechanical Distributed Load-Perpendicular
Group 6	Group 6.1	Class I Amalgam	55°C	Mechanical Singular Load-Perpendicular
	Group 6.2	Class I Amalgam	55°C	Mechanical Distributed Load-Perpendicular
Group 7	Group 7.1	Class II Amalgam	5°C	Mechanical Singular Load-Perpendicular
	Group 7.2	Class II Amalgam	5°C	Mechanical Distributed Load-Perpendicular
Group 8	Group 8.1	Class II Amalgam	55°C	Mechanical Singular Load-Perpendicular
	Group 8.2	Class II Amalgam	55°C	Mechanical Distributed Load-Perpendicular
Group 9	Group 9.1	Class I Glass Ionomer Cement	5°C	Mechanical Singular Load-Perpendicular
	Group 9.2	Class I Glass Ionomer Cement	5°C	Mechanical Distributed Load-Perpendicular
Group 10	Group 10.1	Class I Glass Ionomer Cement	55°C	Mechanical Singular Load-Perpendicular
	Group 10.2	Class I Glass Ionomer Cement	55°C	Mechanical Distributed Load-Perpendicular
Group 11	Group 11.1	Class II Glass Ionomer Cement	5°C	Mechanical Singular Load-Perpendicular
	Group 11.2	Class II Glass Ionomer Cement	5°C	Mechanical Distributed Load-Perpendicular
Group 12	Group 12.1	Class II Glass Ionomer Cement	55°C	Mechanical Singular Load-Perpendicular
	Group 12.2	Class II Glass Ionomer Cement	55°C	Mechanical Distributed Load-Perpendicular

Statistical Analysis

The effect of different factors on stress distribution were analyzed with Kruskal-Wallis and Mann-Whitney U tests using SPSS 13.0 for Windows (SPSS Inc, Chicago, IL, USA).

RESULTS

Von Mises stress values were not statistically significant different among the groups for restorative material and mechanical load factors ($p > 0.05$) while there were statistically significant differences among the groups for cavity geometry and thermal load factors ($p < 0.05$).

Von Mises stress distribution of according to cavity geometry and thermal load factors are shown in Table 3 and Table 4, respectively.

Table 3: Distribution of descriptive statistical data according to cavity geometry factor (MPa).

Cavity Geometry	Von Mises Stress Distribution (σ_M)					
	Mean	Median	Standard Deviation	Standard Error	Minimum	Maximum
Class I Cavity	73.73	72.60	26.17	7.55	38.1	106.9
Class II Cavity	49.60	45.90	17.18	4.96	30.2	75.2
p	0.024					

Table 4: Distribution of descriptive statistical data according to thermal load factor (MPa).

Thermal Load	Von Mises Stress Distribution (σ_M)					
	Mean	Median	Standard Deviation	Standard Error	Minimum	Maximum
5°C	80.20	77.90	20.19	5.83	48.9	106.9
55°C	43.13	41.35	11.84	3.42	30.2	64.6
p	0.001					

The higher Von Mises stress values were found in Class I cavity for cavity geometry and 5°C for thermal load (Figure 5 and 6). Von Mises stress distribution according to study groups are shown in Figure 7.

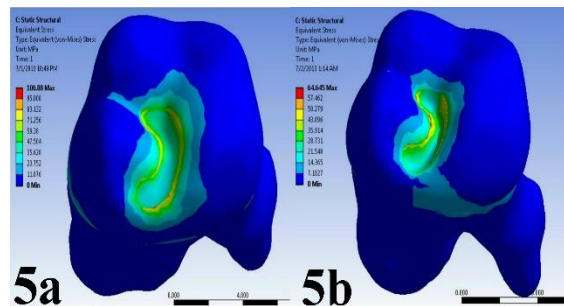


Figure 5: a- Von Mises stress distribution of Class I cavity in Group 1.1. b- Von Mises stress distribution of Class I cavity in Group 2.1.

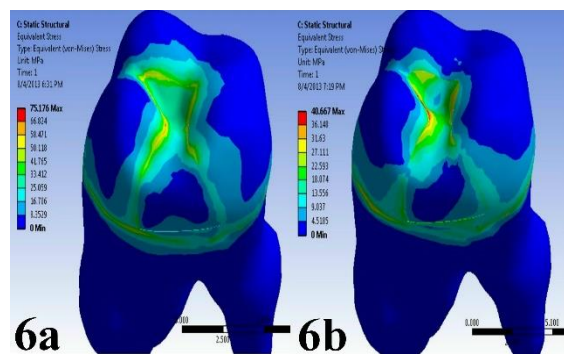


Figure 6: a- Von Mises stress distribution of Class II cavity in Group 3.1. b- Von Mises stress distribution of Class II cavity in Group 4.1.

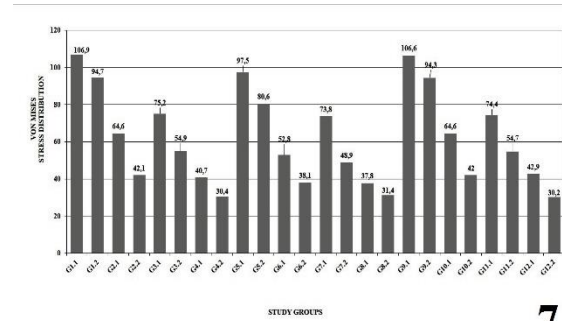


Figure 7: Von Mises stress distribution according to groups.

DISCUSSION

Restorative materials and tooth structures in the oral cavity expand when exposed to cold or hot food and drink.¹⁴ Temperature changes create thermal stress on restored teeth. Differences in the thermal and mechanical properties between the tooth structures and restorative materials promote the development of stress.¹⁵⁻¹⁷ The induced stress may cause cracking within the tooth or failure in the tooth-restorative material interface bonding.¹⁸⁻²⁰ The type, elastic modulus, and rigidity of restorative material are very important to the tooth-restorative material interface bonding. Our study mainly focused on stress and thermal analysis of a restored molar tooth, using FEA and calculate the stresses and thermal fields present.

The thermal expansion coefficients of restorative materials and tooth are used in the thermal stress analysis. When there is a mismatch between the restorative materials and the thermal expansion coefficients of the tooth, there will be expansion or contraction in the restorative material during thermal changes.²¹ The present study demonstrated that stress distribution created by cold exposure was greater than with hot exposure. This result was comparable to the other studies.^{9,22}

Evidence shows that the depth and width of cavity play important roles in fracture resistance of restorations.^{23,24} Valian *et al.*²⁵ reported that by occlusal extension of the Class II cavities, the amount of stress at the interface increased. However, Chang *et al.*²⁶ found that

by increasing the cavity dimensions, the stress at the interface did not increase. We found that the higher Von Mises stress values were found in Class I cavity for cavity geometry.

In vivo studies have reported different findings on occlusal forces at the posterior region. In addition, practical occlusal force in clinic is sometimes larger than the normal occlusal force. Fu *et al.*²⁷ reported that the biggest occlusal force can achieve 480 N for the maxillary first molar. Two mechanical load (mechanical singular load-perpendicular and mechanical distributed load-perpendicular) used in the present study. Using of different mechanical load may cause different von Mises stress distribution.

Tooth decay can be treated with various restorative materials and different restorative application techniques. Today, the use of aesthetically pleasing materials has increased in response to patient demand. However, clinicians should consider not only the aesthetics of the restorative material but also its biomechanics and durability when selecting a material.²⁸ The cavity was restored with three different restorative materials (resin composite, amalgam and glass ionomer cement) in this study. However, we found that the stress distribution of this restorative materials were similar. Using of restorative materials with different mechanical and thermal properties may cause different von Mises stress distribution. However, our study results should be supported by clinical studies.

CONCLUSION

- The higher Von Mises stress values were found in Class I cavity for cavity geometry factor.
- The higher Von Mises stress values were found in 5°C for thermal load factor.

ACKNOWLEDGMENTS

The authors thank Prof. Dr. Saim Yologlu (Inonu University, Department of Biostatistics

and Medical Informatics) for providing statistically analysis in this study.

CONFLICTS OF INTEREST

The authors declare no potential conflicts of interest with respect to the authorship and/or publication of this article.

REFERENCES

1. Narayanaswamy S, Meena N, ShetTL A, et al. Finite element analysis of stress concentration in Class V restorations of four groups of restorative materials in mandibular premolar. *J Conserv Dent* 2008; 11(3): 121-126.
2. Hood JAA. Biomechanic of intact, prepared and restored tooth: some clinical implications. *Int Dent J* 1991; 41: 25-32.
3. Palmer DS, Barco MT, Billy EJ. Temperature extremes produced orally by hot and cold liquids. *J Prosthet Dent* 1992; 67(3): 325-327.
4. Toparli M, Gökay N, Aksoy T. An investigation of temperature and stress distribution on a restored maxillary second premolar tooth using a three-dimensional finite element method. *J Oral Rehabil* 2000; 27(12): 1077-1081.
5. Asmussen E, Peutzfeldt A. Class I and Class II restorations of resin composite: an FEM analysis of the influence of modulus of elasticity on stresses generated by occlusal loading. *Dent Mater* 2008; 24: 600-605.
6. Guler MS, Guler C, Cakici F, Cakici EB, Sen S. Finite element analysis of thermal stress distribution in different restorative materials used in class V cavities. *Niger J Clin Pract* 2016; 19: 30-34.
7. Hashemipour MA, Mohammadpour A, Nassab SA. Transient thermal and stress analysis of maxillary second premolar tooth using an exact three-dimensional model. *Indian J Dent Res* 2010; 21(2):158-164.
8. Vasudeva G, Bogra P, Nikhil V, Singh V. Effect of occlusal restoration on stresses around class V restoration interface: a finite-

element study. *Indian J Dent Res* 2011; 22(2): 295-302.

9. Çelik Köycü B, İmirzalıoğlu P. Heat transfer and thermal stress analysis of a mandibular molar tooth restored by different indirect restorations using a three-dimensional Finite Element Method. *J Prosthodont* 2017; 26(5): 460-473.

10. Koriouth TW, Versluis A. Modeling the mechanical behavior of the jaws and their related structures by finite element (FE) analysis. *Crit Rev Oral Biol Med* 1997; 8(1): 90-104.

11. Ausiello P, Franciosa P, Martorelli M, Watts DC. Numerical fatigue 3D-FE modeling of indirect composite-restored posterior teeth. *Dent Mater* 2011; 27(5): 423-430.

12. Arola D, Huang MP. The influence of simultaneous mechanical and thermal loads on the stress distribution in molars with amalgam restorations. *J Mater Sci Mater Med* 2000; 11(3):133-140.

13. Bayne SC, Thompson JY, Taylor, DF. Dental Materials. 133-233. In: Roberson TM, Heymann H, Swift EJ, Sturdevant CM (Eds). *Sturdevant's Art & Science of Operative Dentistry*. St. Louis: Mosby; 2002.

14. Yang SH, Lang LA, Guckes AD, Felton DA. The effect of thermal change on various dowel-and-core restorative materials. *J Prosthet Dent* 2001; 86: 74-80.

15. Lee SY, Chiang HC, Huang HM, Shih YH, Chen HC, Dong DR, Lin CT. Thermo-debonding mechanisms in dentin bonding systems using finite element analysis. *Biomaterials* 2001; 22(2): 113-123.

16. Sidhu SK, Carrick TE, McCabe JF. Temperature mediated coefficient of dimensional change of dental tooth-colored restorative materials. *Dent Mater* 2004; 20: 435-440.

17. Sideridou I, Achilias DS, Kyrikou E. Thermal expansion characteristics of light-cured dental resins and resin composites. *Biomaterials* 2004; 25: 3087-3097

18. Brown WS, Jacobs HR, Thompson RE. Thermal fatigue in teeth. *J Dent Res*. 1972; 51: 461-467.

19. Price RB, Derand T, Andreou P, Murphy D. The effect of two configuration factors, time, and thermal cycling on resin to dentin bond strengths. *Biomaterials* 2003; 24(6): 1013-1021.

20. Sakaguchi RL, Powers JM (Eds). *Craig's Restorative Dental Materials*. Philadelphia: Mosby, 2012.

21. Oskui IZ, Ashtiani MN, Hashemi A, Jafarzadeh H. Effect of thermal stresses on the mechanism of tooth pain. *J Endod* 2014; 40(11): 1835-1839.

22. Güngör MA, Küçük M, DüNDAR M, Karaoğlu C, Artunç C. Effect of temperature and stress distribution on all-ceramic restorations by using a three-dimensional finite element analysis. *J Oral Rehabil* 2004; 31(2): 172-178.

23. Boushell LW, Roberson TM, Wilder Jr AD. Complex Amalgam Restorations. In: Heymann HO, Swift, Jr EJ, Ritter AV (eds). *Sturdevant's Art and Science of Operative Dentistry*. St. Louis: Mosby, 2012: 429-454.

24. Moorthy A, Hogg CH, Dowling AH, Grufferty BF, Benetti AR, Fleming GJP. Cuspal deflection and microleakage in premolar teeth restored with bulk-fill flowable resin-based composite base materials. *J Dent* 2012; 40(6): 500-5.

25. Valian A, Moravej-Salehi E, Geramy A, Faramarzi E. Effect of extension and type of composite-restored class II cavities on biomechanical properties of teeth: a three dimensional Finite Element Analysis. *J Dent (Tehran)* 2015; 12(2): 140-50.

26. Chang CH, Fang CL, Hsu JT, Chen CP, Chuang SF. Cavity dimension effect on MOD dental restoration filled with resin composite—A finite element interface stress evaluation. *J Med Biol Eng* 2004; 24: 195-200.

27. Fu G, Deng F, Wang L, Ren. The three-dimension finite element analysis of stress in posterior tooth residual root restored with postcore crown. *Dent Traumatol* 2010; 26(1): 64-9.

28.Cortellini D, Canale A, Giordano A, Bergantini B, Bergantini D. The combined use of all-ceramic and conventional metal-ceramic restorations in the rehabilitation of severe tooth wear. Quint Dent Technol 2005; 28: 205-214.

Corresponding Author

Assist. Prof. Dr. Mehmet Sami GÜLER

Ordu University

Department of Machinery and Metal Technologies

Vocational School of Technical Sciences,

52200 Ordu - Turkey

Tel : +90 452 233 48 65 (work)

Fax : +90 452 233 52 30

E-mail : mehmetmamiiguler@yandex.com



EVALUATION OF CYTOTOXICITY OF QMIX, ETHYLENE DIAMINETETRAACETIC ACID AND CHLORHEXIDINE ON HUMAN OSTEOBLAST CELL LINE

Human Osteoblast Hücre Hattı Üzerinde Qmix, Etilen Diamintetraasetik Asit ve Klorheksidin'in Sitotoksitesininin Değerlendirilmesi

Zeliha UĞUR AYDIN¹, Kerem Engin AKPINAR²,
Ceylan HEPOKUR³, Demet ALTUNBAŞ²

Makale Kodu/Article Code : 438506

Makale Gönderilme Tarihi : 29.06.2018

Kabul Tarihi : 03.08.2018

ABSTRACT

Objectives: In this study, the time-dependent toxic effects of QMix™, ethylene diaminetetraacetic acid and chlorhexidine irrigation solutions on human osteoblast cells were as evaluated.

Methods and Materials: Human osteoblast cells were grown as monolayer cultures at 37°C in an atmosphere of 5% CO₂ in air and 100% relative humidity. Cells were exposed to ethylene diaminetetraacetic acid (EDTA), chlorhexidine (CHX) and QMix™ for 4 hours and 24 hours. Cell viability was assessed by a 2,3-bis(2-methoxy-4-nitro-5-sulfophenyl)-5-[(phenylamino)carbonyl]-2H-tetrazolium hydroxide kit (XTT) assay. The differences in the mean viability of human osteoblast cells were evaluated statistically.

Results: There was a statistically significant difference between the mean percentage of viable cells in the test solutions and control group, both after 4 hour (p<0.001) and 24 hour exposure (p=0.004). The mean percentage of viable cells decreased statistically significantly with the increase in the time of exposure in the EDTA, CHX and QMix™ groups (p<0.05). After 4 hours' exposure, the EDTA and QMix showed statistically a less toxic effect than did CHX (p<0.05). There was no statistically significant difference between the toxicity of the irrigation solutions after 24 hours' exposure (p>0.05).

Conclusion: All irrigation solutions tested showed various toxic effects on the human osteoblast cell line. The increase in exposure time also increased the toxicity of irrigation solutions on the human osteoblast cell line.

Keywords: Chlorhexidine; Ethylene Diaminetetraacetic acids; Toxicity; QMix™.

ÖZ

Amaç: Bu çalışmada, QMix™, etilen diamintetraasetik asit ve klorheksidin irrigasyon solüsyonlarının human osteoblast hücreleri hattı üzerindeki zamana bağlı toksik etkisi değerlendirildi.

Materyal ve metod: Human osteoblast hücreleri, %5 CO₂ ve %100 bağıl nem içeren bir ortamda 37°C'de tek tabakalı olacak şekilde kültüre edildi. Hücreler 4 saat ve 24 saat boyunca etilen diamintetraasetik asit (EDTA), klorheksidin (CHX) ve QMix™ 'e maruz bırakıldı. Hücre canlılığı 2,3-bis(2-methoxy-4-nitro-5-sulfophenyl)-5-[(phenylamino)carbonyl]-2H-tetrazolium hydroxide kiti (XTT) ile değerlendirildi. Human osteoblast hücrelerinin ortalama yaşayabilirliğindeki farklılıklar istatistiksel olarak değerlendirildi.

Bulgular: Deney solüsyonlarındaki ve kontrol grubundaki canlı hücrelerin ortalama yüzdesi arasında hem 4 saatlik (p<0,001) hem de 24 saatlik (p=0,004) uygulamanın sonrasında istatistiksel olarak anlamlı fark görüldü. Canlı hücrelerin ortalama yüzdesi, EDTA, CHX ve QMix™ grubunda uygulama süresinin artması ile istatistiksel olarak anlamlı derecede azaldı (p<0,05). 4 saat süresince uygulamanın ardından CHX'e göre EDTA ve QMix istatistiksel olarak anlamlı derecede daha az toksik etki gösterdi (p<0,05). 24 saat süresince uygulamanın ardından ise irrigasyon solüsyonlarının toksisitesi arasında istatistiksel olarak anlamlı fark bulunmadı (p>0,05).

Sonuç: Bu çalışmada kullanılan irrigasyon solüsyonları human osteoblast hücre hattı üzerinde çeşitli derecede toksik etki gösterdi. Uygulama süresinin artması kullanılan irrigasyon solüsyonlarının human osteoblast hücre hattı üzerindeki toksisitesini de arttırdı.

Anahtar Kelimeler: Klorheksidin, Etilen diamintetraasetik asit, Toksikite, QMix™.

¹ Department of Endodontics, Faculty of Dentistry, University of Abant İzzet Baysal, Bolu, Turkey

² Department of Endodontics, Faculty of Dentistry, Cumhuriyet University, Sivas, Turkey

³ Department of Biochemistry, Faculty of Pharmacy, Cumhuriyet University, Sivas, Turkey

INTRODUCTION

The inability to completely clean root canals by mechanical shaping has increased the interest in irrigation solutions.¹ There are many irrigation solutions with different contents in endodontics, but none of these solutions can provide all the properties expected from an ideal irrigation solution. For this reason, efforts to determine the ideal solution are continuing.²⁻⁴

EDTA is a commonly-used chelating agent in endodontic treatment. It is used to remove the smear layer by acting on the inorganic components of dentin.⁵ However, EDTA is used in combination with NaOCl in endodontic treatment because of a lack of sufficient antibacterial activity against endodontic bacteria when used alone.^{6, 7}

Another irrigation solution commonly used in endodontic treatment is chlorhexidine (CHX). Being the most effective member of the bisguanide group, CHX is a cationic detergent with a broad antimicrobial spectrum.⁸ The substantivity which allows the antimicrobial effect of CHX to persist even after application, gives it a unique feature advantage.⁹ In addition, this feature prevents the formation of resistant microorganisms, and provides a great advantage in endodontic treatment.^{10, 11}

QMix™ is a new solution containing EDTA, CHX, and a detergent. This newly-developed solution has the ability to remove the smear layer through the use of EDTA, contains the antimicrobial and substantivity properties of CHX, and has low surface tension due to its detergent content. Thus, all the positive properties of the included solutions are collected in QMix™.¹²⁻¹⁴

One of the most studied topics in dentistry is to find the most appropriate materials that can be used in treatment, and to use them in the most appropriate way. In this sense, biocompatibility is accepted as one of the basic requirements when it comes to the use of any

dental restorative material in clinical practice.^{15, 16}

The lack of biocompatibility with regard to the materials used, leads to the possibility that degeneration may occur in terms of structure, proliferation, adhesion and enzyme systems, and therefore in all vital functions of the cells in the related tissue.¹⁷ Furthermore, the biological properties of the materials used have a significant effect on the success of endodontic treatment.¹⁸ For this reason, we aimed to investigate the biocompatibility of the EDTA, CHX and QMix™ used in root canal irrigation *in vitro*. The null hypothesis of the study tested was that there is no difference among the tested irrigation solutions in terms of toxicity.

MATERIALS AND METHODS

Cell cultures

Human osteoblast (hFOB 1.19; American Type Culture Collection, Manassas, VA; #ATCC CRL-11372) cell lines were obtained from commercial sources for these studies. Cells were cultured in Dulbecco's Modified Eagles Medium (DMEM; Sigma Chemical Co., St. Louis, MO) supplemented with 10% fetal bovine serum (Sigma, St. Louis, MO, USA), penicillin (100 U/ml; Sigma, St. Louis, MO, USA), and streptomycin (100 g/ml; Sigma, St. Louis, MO, USA) at 37 °C in a humidified atmosphere of 5% CO₂ in air. The culture medium was changed every 3 to 4 days.

96-well plastic tissue culture plates (Linbro, Flow Laboratories Inc, McLean, VA) were filled with 200 µl of medium containing 2x10⁴ hGFs in each well. The plates were then incubated at 37 °C in a humidified atmosphere of 5% CO₂ and 95% air for 24 hours to permit attachment of the cells to the plates (Figure 1). After 24 hours, the medium was removed, and the hGFs were rinsed three times with 200 µl phosphate buffered saline (PBS). All manipulations of the specimens were performed under a laminar flow hood

(NUAIRE, Plymouth, MN) to avoid contamination from outside organisms.

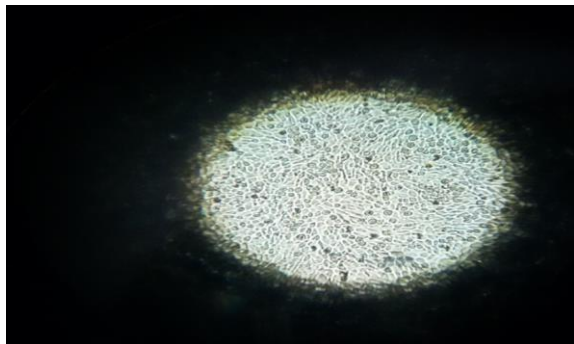


Figure 1: Inverted microscope images of cultured human osteoblast cells before processing.

The study groups were identified as follows:

Group 1: Control (Fetal bovine serum)

Group 2: 2% CHX (Drogsan, Ankara, Turkey)

Group 3: 17% EDTA (Imident Med, Konya, Turkey)

Group 4: QMix™ (DENTSPLY Tulsa Dental Specialties, Tulsa, OK, USA)

Cytotoxicity assay

2,3-bis(2-methoxy-4-nitro-5-sulfo-phenyl)-5-[(phenylamino)carbonyl]-2H-tetrazoliumhydroxide kit (XTT) (AppliChem, Darmstadt, Germany) was used for cytotoxicity testing. An XTT solution was prepared by mixing the XTT agent (Labeling reagent)/activation agent (electron coupling reagent) at a 50/1 ratio. The intensity of the orange resulting from formazan is proportional to the number of live cells (Figure 2). The cell viability was determined by an assessment of the intensity of the orange color observed at the end of the incubation period, which was done using a micro plate reader (Multiskan™ FC Microplate Photometer, Thermo Scientific, USA) in the reference range of 490 nm. The incidence of live cells was calculated using the following formula: Cell viability (%) = (sample/negative control) * 100 (OD 490 nm).

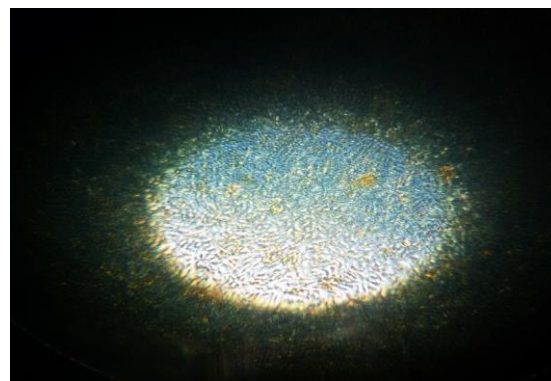


Figure 2: Inverted microscope image of the formazan crystals formed after XTT assay applied after application of test solutions on human iosteoblast cells.

At the end of the first 4 hours, the XTT solution was added to the plate to measure the 4-hour effect, and the viability of the cells in each test group was analyzed through the use of an ELISA reader (Multiskan™ FC Microplate Photometer, Thermo Scientific, USA).

The same procedure was also applied to measure the 24-hour effect at the end of the first 24 hours, and the viability of the cells was analyzed. Thus, XTT outputs showing cell viability obtained by living and dead cells at 4 and 24 hours were obtained. For each irrigation solution used and for the control group, 5 specimens were prepared.

Statistical analysis

The data were analyzed using SPSS 13.0 (SPSS Inc, Chicago, IL) statistical software. The results of the XTT assays was calculated as percentages relative to the control (100% = no toxicity). The results were submitted to the Kolmogorov-Smirnov's test to evaluate the normal distribution. It was found that the data did not show a normal distribution. Therefore, the cytotoxicity data were analyzed using Kruskal-Wallis and Mann-Whitney's tests. The level of significance was set at 0.05.

RESULTS

The toxic effect of the test solutions on the human osteoblast cell line based on exposure time is shown in Table 1.

Table 1: The viability of human osteoblast cells after exposure to EDTA, CHX and QMix™ solutions for 4 hours and 24 hours.

	Control	EDTA	CHX	QMix™
	Mean ±SD	Mean ±SD	Mean ±SD	Mean ±SD
4 hours	99.4 ± 0.8 ^{Aa}	73 ± 8.6 ^{Ab}	53.6 ± 7.3 ^{Ac}	57.2 ± 6.5 ^{Abc}
24 hours	98.6 ± 2.1 ^{Aa}	38.6 ± 5.7 ^{Bb}	35 ± 4.8 ^{Bb}	29 ± 6.5 ^{Bb}

Results are expressed as the percentage of cell viability relative to control group. Data are shown as a mean ± standard deviation. Different superscript uppercase letters in the same column indicate a statistically significant difference ($p < .05$). Different superscript lowercase letters in the same row indicate a statistically significant difference ($p < .05$).

As a result of the study, when the exposure time was 4 hours, there was a significant difference in the toxicity of the solutions ($p = 0.001$). When the exposure time was 4 hours, CHX was more toxic than EDTA ($p = 0.008$). However, there was no significant difference between EDTA and QMix™ ($p = 0.16$) and CHX and QMix™ ($p = 0.421$). When the exposure time was 24 hours, all solutions were more toxic than the control group ($p = 0.004$). However, there was no statistically significant difference in the toxicity between EDTA and CHX ($p = 0.31$), between EDTA and QMix™ ($p = 0.56$), and between CHX and QMix™ ($p = 0.151$).

DISCUSSION

Not only the antibacterial and smear removal properties of the irrigation solutions but also the biological effect of the surrounding tissues have an important role in the success of endodontic treatment.¹⁹ In this study, the time-dependent cytotoxicity of three different endodontic irrigation solutions (EDTA, CHX, and QMix™) was evaluated. As a result of the study, there was a statistically significant difference among the test solutions in terms of toxicity. For this reason, the null hypothesis of this study was not accepted.

No matter how much prevention is attempted during endodontic treatment, there is a risk that the solutions used may extrude from apical to periapical tissues. As a result, if the solutions are not biocompatible, they can cause damage to the surrounding tissue or delay healing in the event of an existing pathology.²⁰

Osteoblast cells are important in the regeneration of bone tissue, so damage to osteoblast cells may delay the healing of periapical pathology.^{21, 22} For this reason, a human osteoblast cell line is preferred in this study.

In vitro cell culture studies assess systemic, local, and other reactions that can be caused by dental materials in animal and human experimental models, thus providing information on the biocompatibility of materials. *In vitro* cell, culture cytotoxicity assays are commonly used in biocompatibility studies because they are reliable, reproducible, controllable, simple and provide short-term results.^{19, 23} Various methods have been used for the evaluation of cytotoxicity, including the evaluation of flow cytometry, MTT or XTT, WST-1, WST-8 assay and lactate dehydrogenase (LDH) activity.²⁴ In this study, the XTT test method which is reliable and easy to use in the evaluation of cytotoxicity, was used. This test method has been used in many studies evaluating *in vitro* toxicity.²⁵

In this study, except for the control group, increased exposure time with regard to all test solutions increased toxicity. Vouzara *et al.*²⁶ reported that an increase in the exposure time of EDTA and CHX on human lung fibroblasts cell line (6, 24 hours) increased toxicity. Li *et al.*²⁷ reported that CHX toxicity on the murine macrophage cell line increased with the increase in exposure time (1, 2, 4 hours). Similarly, Giannelli *et al.*²⁸ reported that an increase in exposure time (1, 5, 15 minutes) increased the toxicity of CHX on osteoblastic, endothelial and fibroblastic cell lines. AlKahtani *et al.*²⁹ reported that the toxicity of QMix™ on the human bone marrow mesenchymal stem cell line increased with increased exposure time. The result of these studies is compatible with those of our study.

Similar to the results of our study, Mollashahi *et al.*³⁰ have shown that the toxicity of EDTA and QMix™ solutions on human

apical papilla cell lines increased with increased exposure time, whereas in the case of the CHX group, toxicity did not increase with an increase in exposure time. This is in contrast to our study findings. This can be explained by differences in the cell line, concentration of the solution, evaluation assay, and exposure time in the two studies.

As a result of our study, when the exposure time was 4 hours, CHX and QMix™ showed higher toxicity on the osteoblast cell line than did EDTA, and in the control group. When the exposure time was 24 hours, the toxicity of the test solutions was not statistically significant. Prado *et al.*³¹ and Vouzara *et al.*²⁶ reported that CHX was more toxic than EDTA on the human lung cell line when the exposure time was 4 hours and on the Balb/c3T3 cell line when exposure times were 6 and 24 hours, respectively. Trevino *et al.*³² reported that CHX is more toxic than EDTA on Human Stem Cells of the Apical Papilla in organotype root canal models. In contrast to the results of our study, Mollashahi *et al.*³⁰ found that EDTA and QMix™ were more toxic than CHX, and that EDTA was more toxic than QMix™ on the stem cell of human apical papilla cell line. This may be due to method differences involving different exposure times and different cell lines. Although the intrinsic mechanism leading to the high toxicity of CHX is not completely known, this may be related to the inhibition of DNA and protein synthesis, mitochondrial activity, and cell proliferation.³³ The low toxicity of EDTA can be explained by the release of dentin-derived growth factors, which are important for the survival, proliferation, and differentiation of cells, as noted in various studies.³²

CONCLUSION

All the irrigation solutions used in this study showed toxic effects when compared to the control group. Increasing the contact time of the solutions used in the study with the

osteoblast cells leads to increased toxicity. When exposure time was 4 hours, CHX was found to be more toxic than the other solutions. But further *in vivo* and *in vitro* investigations are needed to obtain more information about the biocompatibility of these solutions.

Source of funding

None declared.

Conflict of Interest

None declared.

REFERENCES

1. Haapasalo M, Shen Y, Qian W, Gao Y. Irrigation in Endodontics. *Dent Clin North Am* 2010;54: 291-312.
2. Kimura Y, Wilder-Smith P, Matsumoto K. Lasers in endodontics: a review. *Int Endod J* 2000;33: 173-185.
3. Desai P, Himel V. Comparative Safety of Various Intracanal Irrigation Systems. *J Endod* 2009;35: 545-549.
4. Virtej A, MacKenzie CR, Raab WHM, Pfeffer K, Barthel CR. Determination of the performance of various root canal disinfection methods after *in situ* carriage. *J Endod* 2007; 33: 926-929.
5. Lui J-N, Kuah H-G, Chen N-N. Effect of EDTA with and without surfactants or ultrasonics on removal of smear layer. *J Endod* 2007;33: 472-475.
6. Ozdemir HO, Buzoglu HD, Calt S, Stabholz A, Steinberg D. Effect of ethylenediaminetetraacetic acid and sodium hypochlorite irrigation on *Enterococcus faecalis* biofilm colonization in young and old human root canal dentin: *in vitro* study. *J Endod* 2010; 36: 842-846.
7. Soares JA, de Carvalho MAR, Santos SMC, Mendonça RMC, Ribeiro-Sobrinho AP, Brito-Júnior M, Magalhães PP, Santos MH, de Macêdo Farias L. Effectiveness of chemomechanical preparation with alternating

use of sodium hypochlorite and EDTA in eliminating intracanal *Enterococcus faecalis* biofilm. *J Endod* 2010; 36: 894-898.

8. Gomes BP, Vianna ME, Zaia AA, Almeida JFA, Souza-Filho FJ, Ferraz CC. Chlorhexidine in endodontics. *Braz Dent J* 2013; 24: 89-102.

9. Souza M, Cecchin D, Farina AP, Leite CE, Cruz FF, da Cunha Pereira C, Ferraz CCR, Figueiredo JAP. Evaluation of chlorhexidine substantivity on human dentin: a chemical analysis. *J Endod* 2012; 38: 1249-1252.

10. Cousido MC, Carmona IT, García-Caballero L, Limeres J, Álvarez M, Diz P. In vivo substantivity of 0.12% and 0.2% chlorhexidine mouthrinses on salivary bacteria. *Clin Oral Investig* 2010; 14: 397-402.

11. Rôças IN, Siqueira JF. Comparison of the in vivo antimicrobial effectiveness of sodium hypochlorite and chlorhexidine used as root canal irrigants: a molecular microbiology study. *J Endod* 2011; 37: 143-150.

12. Dai L, Khechen K, Khan S, Gillen B, Loushine BA, Wimmer CE, Gutmann JL, Pashley D, Tay FR. The effect of QMix, an experimental antibacterial root canal irrigant, on removal of canal wall smear layer and debris. *J Endod* 2011; 37: 80-84.

13. Eliot C, Hatton JF, Stewart GP, Hildebolt CF, Gillespie MJ, Gutmann JL. The effect of the irrigant QMix on removal of canal wall smear layer: an ex vivo study. *Odontology* 2014; 102: 232-240.

14. Elakanti S, Cherukuri G, Rao VG, Chandrasekhar V, Rao AS, Tummala M. Comparative evaluation of antimicrobial efficacy of QMix™ 2 in 1, sodium hypochlorite, and chlorhexidine against *Enterococcus faecalis* and *Candida albicans*. *J Conserv Dent* 2015; 18: 128.

15. Gulati N, Chandra S, Aggarwal PK, Jaiswal JN, Singh M. Cytotoxicity of eugenol in sealer

containing zinc-oxide. *Endod Dent Traumatol* 1991; 7: 181-185.

16. Wataha JC, Hanks CT, Strawn SE, Fat JC. Cytotoxicity of components of resins and other dental restorative materials. *J Oral Rehabil* 1994; 21: 453-462.

17. Cohen BI, Pagnillo MK, Musikant BL, Deutsch AS. An in vitro study of the cytotoxicity of two root canal sealers. *J Endod* 2000; 26: 228-229.

18. Saw TY, Cao T, Yap AU, Lee Ng MM. Tooth slice organ culture and established cell line culture models for cytotoxicity assessment of dental materials. *Toxicol In Vitro* 2005; 19: 145-154.

19. Hanks CT, Wataha JC, Sun Z. In vitro models of biocompatibility: a review. *Dent Mater* 1996; 12: 186-193.

20. de Sermeno RF, da Silva LA, Herrera H, Herrera H, Silva RA, Leonardo MR. Tissue damage after sodium hypochlorite extrusion during root canal treatment. *Oral Surg Oral Med Oral Pathol Oral Radiol Endod* 2009; 108: 46-49.

21. Rodrigues C, Costa-Rodrigues J, Capelas JA, Fernandes MH. Behaviour of co-cultured human osteoclastic and osteoblastic cells exposed to endodontic sealers' extracts. *Clin Oral Investig* 2014; 18: 479-488.

22. Khayat A. Histological observations of periradicular healing following root canal treatment. *Aust Endod J* 2005; 31: 101-105.

23. Schmalz G. Concepts in biocompatibility testing of dental restorative materials. *Clin Oral Investig* 1998; 1: 154-162.

24. Chung H-J, Kim D-W. Cell proliferation and Cytotoxicity Assays. *Korean Journal of Crop Science* 2004; 49: 208-216.

25. Putnam KP, Bombick DW, Doolittle DJ. Evaluation of eight in vitro assays for assessing the cytotoxicity of cigarette smoke condensate. *Toxicol In Vitro* 2002; 16: 599-607.

26. Vouzara T, Koulaouzidou E, Ziouti F, Economides N. Combined and independent cytotoxicity of sodium hypochlorite, ethylenediaminetetraacetic acid and chlorhexidine. *Int Endod J* 2016; 49: 764-73.

27. Li YC, Kuan YH, Lee SS, Huang FM, Chang YC. Cytotoxicity and genotoxicity of chlorhexidine on macrophages in vitro. *Environ Toxicol* 2014; 29: 452-458.

28. Giannelli M, Chellini F, Margheri M, Tonelli P, Tani A. Effect of chlorhexidine digluconate on different cell types: a molecular and ultrastructural investigation. *Toxicol In Vitro* 2008; 22: 308-317.

29. AlKahtani A, Alkahtany SM, Mahmood A, Elsafadi MA, Aldahmash AM, Anil S. Cytotoxicity of QMix™ endodontic irrigating solution on human bone marrow mesenchymal stem cells. *BMC oral health* 2014; 14: 27.

30. Farhad Mollashahi N, Saberi E, Karkehabadi H. Evaluation of Cytotoxic Effects of Various Endodontic Irrigation Solutions on the Survival of Stem Cell of Human Apical Papilla. *Iran Endod J* 2016; 11: 293-297.

31. Prado M, Silva EJ, Duque TM, Zaia AA, Ferraz CC, Almeida JF, Gomes BP. Antimicrobial and cytotoxic effects of

phosphoric acid solution compared to other root canal irrigants. *J Appl Oral Sci* 2015; 23: 158-163.

32. Trevino EG, Patwardhan AN, Henry MA, Perry G, Dybdal-Hargreaves N, Hargreaves KM, Diogenes A. Effect of irrigants on the survival of human stem cells of the apical papilla in a platelet-rich plasma scaffold in human root tips. *J Endod* 2011; 37: 1109-1115.

33. Faria G, Celes MR, De Rossi A, Silva LA, Silva JS, Rossi MA. Evaluation of chlorhexidine toxicity injected in the paw of mice and added to cultured I929 fibroblasts. *J Endod* 2007; 33: 715-722.

Corresponding Author

Zeliha Ugur Aydın

Abant İzzet Baysal University

Faculty of Dentistry

Department of Endodontics

Bolu, Turkey

Tel : +90 374 253 8455

Fax : +90 374 253 6600

Email : zlhugur@gmail.com



ACCURACY OF DIGITAL PANORAMIC RADIOGRAPHS ON THE VERTICAL MEASUREMENTS OF DENTAL IMPLANTS

Dijital Panoramik Radyografilerin Dental İmplantların Dikey Ölçümleri Üzerindeki Doğruluğu

Burak Kerem APAYDIN¹, Füsün YASAR²,
Alper KIZILDAĞ³, Osman Ufuk TASDEMİR⁴

Makale Kodu/Article Code : 421453

Makale Gönderilme Tarihi : 17.05.2018

Kabul Tarihi : 17.09.2018

ABSTRACT

Objectives: Panoramic radiography (PR) is the most commonly used technique to evaluate the dental and associated structures. The aim of this study was to determine the accuracy of panoramic radiographic images (PRIs) in planning the dental implant treatment and the magnification rate of a panoramic device for anterior, premolar and posterior regions.

Materials and Methods: Eighty-eight patients with PRIs were taken after implant surgery were included to the study. A total of 240 dental implants (53 anterior, 69 premolar, and 118 molar regions) of which actual vertical lengths were known, were re-measured on post-operative radiographic images using the scaling tools of the panoramic system to determine the magnification rate and the accuracy of PRIs. Because the data had normal distribution, the paired t test was used for the statistical analysis ($p < 0.05$). The magnification rates of the three regions were calculated as the ratio of the radiographically measured vertical length of the implants to the actual vertical length of the implants.

Results: A statistically significant difference was found between the actual and measured vertical length of the implants on the PRI ($p < 0.05$). However, the correlation rate was found close to 1 for all regions. The difference between the actual and measured vertical length of the implants on the PRI was 0.50 mm for the anterior region, 0.97 mm for the premolar region, and 0.83 mm for the molar region. The magnification rate of the panoramic system corrected by Cliniview™ (Instrumentarium Corp., Tuusula, FINLAND) software was found around 1 for all the regions.

Conclusions: Due to their readily accessible nature and low radiation dose, PRIs can be used in implant surgery for vertical measurements with 1 mm confidence interval.

Keywords: Dental implant, Panoramic radiography, Radiographic examination, Radiographic magnification, Vertical measurement

ÖZ

Amaç: Panoramik radyografi (PR), dental ve ilişkili yapıları değerlendirmek için en sık kullanılan tekniktir. Bu çalışmanın amacı, dental implant tedavisinin planlanmasında panoramik radyografik görüntülerin (PRI) doğruluğunu ve anterior, premolar ve posterior bölgeler için bir panoramik cihazın büyütme oranını belirlemektir.

Gereç ve Yöntem: İmplant cerrahisi sonrası PRI'ları alınmış olan 83 hasta çalışmaya dahil edildi. Önceden dikey uzunlukları bilinen toplam 240 adet dental implant (53 anterior, 69 premolar ve 118 molar bölge), PRI'nın büyütme oranını ve doğruluğunu belirlemek için, panoramik sistemin ölçüm araçları kullanılarak ameliyat sonrası radyografik görüntüler üzerinde tekrar ölçüldü. Verilerin normal dağılıma sahip olması nedeniyle, istatistiksel analiz için eşleştirilmiş t testi kullanıldı ($p < 0,05$). Üç bölgenin büyütme oranı, implantların ölçülen dikey uzunluğunun, implantların gerçek dikey uzunluğuna oranı bulunarak hesaplandı.

Bulgular: İmplantların gerçek dikey uzunluğu ve PRI'dan ölçülen dikey uzunluğu arasında istatistiksel olarak anlamlı fark bulundu ($p < 0,05$). Bununla birlikte, korelasyon oranı tüm bölgeler için 1'e yakın bulundu. İmplantların gerçek dikey uzunluğu ve PRI'den ölçülen dikey uzunluğu arasındaki fark, ön bölge için 0.50 mm, premolar bölge için 0,97 mm ve molar bölge için 0,83 mm idi. Cliniview™ (Instrumentarium Şti., Tuusula, FİNLANDİYA) yazılımı tarafından düzeltilen panoramik sistemin büyütme oranı, tüm bölgeler için 1 civarında bulundu.

Sonuçlar: PRI'lar, kolay ulaşılabilir olmaları ve düşük radyasyon dozları sayesinde, implant cerrahisi planlamasındaki dikey ölçümler için 1 mm'lik güven aralığı ile kullanılabilir.

Anahtar Kelimeler: Dental implant, Panoramik radyografi, Radyografik inceleme, Radyografik büyüme, Dikey ölçüm

¹ Department of Dentomaxillofacial Radiology, Faculty of Dentistry, Pamukkale University, Denizli, Turkey

² Department of Dentomaxillofacial Radiology, Faculty of Dentistry, Selcuk University, Konya, Turkey

³ Department of Periodontology, Faculty of Dentistry, Pamukkale University, Denizli, Turkey

⁴ Department of Dentomaxillofacial Surgery, Faculty of Dentistry, Pamukkale University, Denizli, Turkey

INTRODUCTION

Prior to dental implant surgery, it is necessary to determine the vertical height and width of the bucco-lingual bone in which the implant will be placed, location of the nasal and maxillary sinus floor, mandibular canal site, mental foramen, the submandibular gland fossa and the location of the possible lesions in the maxilla and mandible.¹⁻⁴ Determining the exact location of anatomical structures in relation to the size of dental implant increases the success rate of the implant surgery and avoids damage during surgery. This can only be possible with proper and careful radiological examination.^{2, 5}

To date, radiographic methods such as panoramic, periapical and occlusal radiographs, conventional tomography (T), computed tomography (CT) and cone beam computed tomography (CBCT) have been used for the pre-surgical implant planning. Clinicians should determine the optimal imaging method for every patient.⁶⁻⁸ Naturally, choosing a radiographic method that provides sufficient diagnostic information for treatment planning with least possible radiation dose (ALARA principle: as low as reasonably achievable) should be the goal.⁹

Determination of the bucco-lingual width of edentulous region needs cross-sectional images that can be obtained from T, CT, and CBCT.⁹ Recently, the use of CT and CBCT has been increased.¹ Studies showed that Ts and CTs are more reliable than intraoral and panoramic radiographs.^{10,11} However, expensive imaging devices have several disadvantages including having high radiation dose, formation of CT streak artifacts in the presence of pins or metal restorations, and inability of the patient to move during long exposure time. In addition, CBCT performs highly to visualize anatomical structures, periodontal and periapical bone defects, and evaluation of the implant sites.^{1, 5, 9}

Non-uniform magnification rate causes dimensional measurements to be restricted in

PRDs.^{4,5,12} Nevertheless, PR is an easily accessible and widely used technique. It provides imaging of both maxillary and mandibular dental arches along with their neighboring tissues; residual dental roots, apical or bone lesions and distance between remaining teeth with a low radiation dose in a short time.^{5, 13} Studies have reported that PRIs are reliable to assess the posterior mandibular bone height when the patient is appropriately positioned, and cross-sectional imaging is not necessary for each patient.^{1,14-17} Frei *et al.*¹⁸ stated that PR provided sufficient information for implant length selection. Sakakura *et al.*⁷ reported that the majority of dentists (82.6%) chose PR in the dental implant planning because of the broad coverage and economical reasons. However, having image distortion, and not giving the width of alveolar bone and the cross-sectional dimension of the bone are shortcomings of PRIs. The width of alveolar bone can be determined by various clinical tests. The width of alveolar ridge, the presence and size of lingual undercuts can be examined manually in an edentulous region. If necessary, an impression can be made for an accurate evaluation.¹ A well-trained surgeon can evaluate the width of the posterior mandible with his experience and decide whether it is suitable for implant placement. However, muscles and connective tissues can affect the clinical appearance.¹⁸

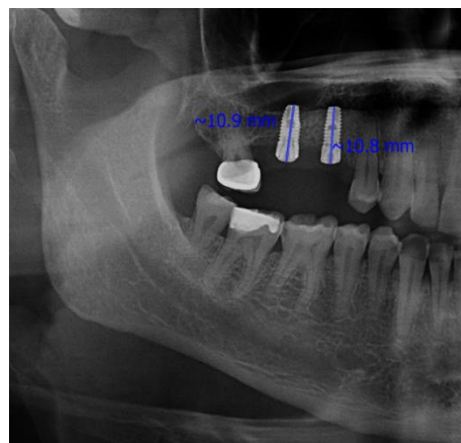
Vazquez *et al.*¹⁴ have studied the magnification rate of the Scanora® unit (Soredex Orion Corp., Helsinki, Finland) and they recommended that the magnification rate of other panoramic devices should be verified. Some authors have reported that the reference objects of known dimensions should be used to precisely determine the magnification rate.^{18, 19}

The purpose of this study was to determine the reliability of PR in vertical bone measurements prior to dental implant surgery and to determine the magnification rate of the Instrumentarium Dental™

ORTHOPANTOMOGRAPH™ OP200D (Instrumentarium Corp., Tuusula, FINLAND) (OP200D) instrument for anterior, posterior and molar regions. The null hypothesis of this study was 'there is no statistically significant difference between actual and measured vertical length of the implant on the PRI'.

MATERIALS AND METHODS

A letter confirming ethical approval for the study was obtained from Pamukkale University, Faculty of Medicine, Ethics Committee (number: 60116787-020/32012). Eighty-eight patients with no pathological lesions or bone disease who had undergone implant surgery at the Pamukkale University, Faculty of Dentistry (Denizli, Turkey) with a clear PRI taken in the correct position after the implant surgery were included in the study. PRIs were randomly chosen from the patient archive of the Dentomaxillofacial Radiology Clinic. None of the PRIs were obtained specifically for this study. All radiographs were taken by using the same panoramic machine (OP 200D) and by the same x-ray technician (S.C.) who used a standard exposure protocol (66kV/10mA/16s). All patients were positioned using a bite block according to the manufacturer's instructions during the exposure of PRIs. The 240 dental implants (53 anterior, 69 premolar and 118 molar region), which dimensions were previously known, were measured on the postsurgical PRIs by a dentomaxillofacial radiologist (BK. A. who didn't participate in the surgery) with the scaling tool of the panoramic system (Figure 1).



Using postsurgical PRIs, the magnification rate was determined for each region by the following formula:

$$\text{Measured length of the implant on PRI} / \text{Actual length of the implant}$$

Statistical data analysis was performed using a computer software (SPSS 21.0 version IBM Corp., Chicago, IL, USA). The Kolmogorov-Smirnov test was performed to determine whether the data showed a normal distribution. The paired t test was used to analyze the difference between the measured and actual vertical length of the implants ($p < 0.05$). Pearson correlation analysis was used to determine the correlation between the actual length and the measured length of the implant ($p < 0.05$).

RESULTS

A statistically significant difference was found between the measured and actual size of the implants in all regions ($p < 0.05$). The difference between the actual size and measured size of the implants were 0.50 mm in the anterior region, 0.97 mm in the premolar region and 0.83 mm in the molar region (Table 1).

Table 1. The relationship between the actual size of the implants and the measured size on the PRI of the implants according to the regions (M \pm SD).

Region	Measured size (M \pm SD)	Actual size (M \pm SD)	n	Averages of differences	t	p
Anterior	11.89 \pm 1.55	11.84 \pm 1.55	53	0.50 \pm 0.12	-2.97	0.005
Premolar	11.12 \pm 1.46	11.02 \pm 1.44	69	0.97 \pm 0.12	-6.40	<0.001
Molar	10.40 \pm 1.53	10.32 \pm 1.50	118	0.83 \pm 0.12	-7.47	<0.001

M: Mean; SD: Standard Deviation

The correlation coefficient was close to 1 for all regions (Table 2).

Table 2. Pearson correlation between actual and measured values according to the regions.

Variables	n	Correlation coefficient	P
Anterior Region Actual Length&Anterior Region Measured Length	53	0.997	<0.001
Premolar Region Actual Length &Premolar Region Measured Length	69	0.996	<0.001
Molar Region Actual Length &Molar Region Measured Length	118	0.997	<0.001

The magnification rates was close to 1 for all regions (Table 3).

Table 3. Magnification rates according to the regions.

Region of implant	Magnification rate
Anterior region	1.004 (ranging from 0.98 to 1.02)
Premolar region	1.008 (ranging from 0.98 to 1.03)
Molar region	1.007 (ranging from 0.98 to 1.03)

In the user manual of OP200D, the magnification rate is specified as 1.3. However the manual also states that Cliniview™ software automatically corrects the growth rate. In this study values corrected with Cliniview™ software were accounted.

DISCUSSION

The choice of implant length and width is generally determined by the volume and density of the existing alveolar ridge, the location of adjacent teeth and vital anatomical structures, the type of prosthesis, and the treatment protocol. Theoretically, longer and wider implants should be preferred in order to resist the loaded forces and avoid fracture risk after prosthetic treatment.⁹ On the other hand, studies involving new implant designs/surfaces have reported that the failure rate of short and long implants is comparable and there is no relationship between implant diameter and survival ratio.^{2, 9, 20} On the contrary, it has also been argued that cases with fresh sockets require larger and/or longer implants to ensure primary implant stability and to reduce the distance between implant and bone socket walls.²¹ However, Vazquez *et al.* pointed out that protecting the mandibular canal was always

their priority. They reported that the use of short implants does not jeopardize the long-term implant success rate and may reduce nerve injury risk associated with implant placement in the posterior segment of the mandible, especially when the mandibular canal is difficult to localize on the radiograph.²²

Schropp *et al.*⁹ argued that the choice of implant size was greatly influenced by the radiographic technique used for presurgical treatment planning. They also reported that the lack of cross-sectional information may lead to the use of shorter and narrower implant sizes.²³ However, they reported that the implants planned with cross-sectional imaging could not be considered more successful. In addition, they reported that there was no consensus on the need for cross-sectional imaging when a panoramic radiograph was already present.⁹

The information provided by cross-sectional images are valuable in giving detailed and 1:1 images, detecting lingual undercuts in the posterior zone of the mandible. If lingual perforation occurs during implant operation, this can result in life-threatening bleeding and/or airway obstruction due to the impact on the large arteries of the mandibular base.¹⁸ In order to avoid the complications associated with mandibular canal, it is recommended that the distance between the lower limit of the implant and the mandibular canal should be at least 2mm taking the magnification rate of the PR in consideration.^{6, 9, 14} Although CT and CBCT images are known to give detailed and 1:1 rearranged images, it is recommended that the distance between the implant and mandibular canal should be at least 1.7 mm. This value is similar to the recommended value for PR.¹⁵ CBCT may be preferred when 3D imaging is required, but effective radiation dose of CBCT is much higher and more expensive than traditional dental radiographs.^{1, 9} For these reasons; we preferred to plan this study on PR.

PRIs tend to underestimate the distance between the alveolar crest and the upper border

of the mandibular canal.²⁴ Underestimation of this distance is less harmful than overestimation. In the case of an overestimation, a long implant may damage the nerve.¹⁵ Frie *et al.*¹⁸ found a magnification rate of 1.27 ± 0.01 . They also showed that the height of the vertical bone measured by spiral tomogram was 1 mm longer than the height of the bone measured by PR. Because spiral tomograms tend to overestimate the distance, assessment of the vertical bone height can be risky if measured only by spiral CT.²²

There are also studies reporting that PR shows overestimation in posterior mandibular measurements.^{4, 5} Rockenbach *et al.*⁴ estimated that PR overestimated linear measurements on the mandibular field. Nevertheless, they stated that PR and linear tomography of implant site measurements can be used safely with a safety margin of 2 mm.

The accuracy of bone measurements on PR has been questioned because of the magnification and distortion (Table 4).^{14, 25}

Table 4. Magnification rates found with different PR devices.

Author (s)	Device / Company	Magnification rate
Kim et al [11]	Panoramic Radiograph/ Orthopantomograph® / Instrumentarium	1.26 (mandibular premolar region)
		1.25 (mandibular molar region)
Park et al [6]	Panoramic Radiograph/ Cranex® / Soredex	1.31 (mandibular premolar region)
		1.27 (mandibular molar region)
Yim et al [8]	Panoramic Radiograph/ Promax / Planmeca	1.171 ± 0.057 (not depending on region)
	Panoramic Radiograph/ Ortho Stage / Asahi	1.270 ± 0.051 (not depending on region)
Vazquez et al [14]	Panoramic Radiograph/ Scanora® / Soredex	1.28 ± 0.01 (premolar region)
		1.27 ± 0.01 (molar region)
Frie et al [18]	Panoramic Radiograph/ Cranex Tome®/ Soredex	1.27 ± 0.01 (not depending on region)
	Spiral Tomogram	1.52 ± 0.01 (not depending on region)

Knowing the correct magnification rate will allow more precise selection of implant size. A previous study on imaging procedures of implant treatment has suggested that the correct magnification rate should be determined for the calibration of the region to which the implant is to be applied.^{2, 9} For this reason, we aimed to determine the correct magnification rate for the OP200D in this study.

It has also been reported that the use of bite blocks reduces positional errors while PRIs are

taken.^{5, 6, 14} Therefore, in our study the patients used bite blocks and their positioning was done according to the manufacturer's instructions.

No single implant trademark was used in this study. In addition, grouping of maxilla and mandible was not performed in implant measurements. These are the shortcomings of this study.

CONCLUSIONS

Within the limitations of this study, following conclusions can be drawn; the magnification rate of OP200D is close to 1 and it gives errors less than 1 mm in vertical measurements made with Cliniview™ software. Therefore, except the cases where the location of the mandibular canal and lingual undercuts in the posterior region of the mandible cannot be clearly detected and cross sectional images are required; PRs with known magnification rates can be used with easy access, low radiation dose and low cost, in the vertical measurements with a 1mm confidence interval.

REFERENCES

1. Kim YK, Park JY, Kim SG, Kim JS, Kim JD. Magnification rate of digital panoramic radiographs and its effectiveness for pre-operative assessment of dental implants. *Dentomaxillofac Radiol* 2011;40:76-83.
2. Schropp L, Stavropoulos A, Gotfredsen E, Wenzel A. Calibration of radiographs by a reference metal ball affects preoperative selection of implant size. *Clin Oral Investig* 2009;13:375-381.
3. Mehra A, Pai KM. Evaluation of dimensional accuracy of panoramic cross-sectional tomography, its ability to identify the inferior alveolar canal, and its impact on estimation of appropriate implant dimensions in the mandibular posterior region. *Clin Implant Dent Relat Res* 2012;14:100-111.
4. Rockenbach MI, Sampaio MC, Costa LJ, Costa NP. Evaluation of mandibular implant sites: correlation between panoramic and linear tomography. *Braz Dent J* 2003;14:209-213.

5. Haghnegahdar A, Bronoosh P. Accuracy of linear vertical measurements in posterior mandible on panoramic view. *Dent Res J (Isfahan)* 2013;10:220-224.
6. Park JB. The evaluation of digital panoramic radiographs taken for implant dentistry in the daily practice. *Med Oral Patol Oral Cir Bucal* 2010;15:663-666.
7. Sakakura CE, Morais JA, Loffredo LC, Scaf G. A survey of radiographic prescription in dental implant assessment. *Dentomaxillofac Radiol* 2003;32:397-400.
8. Yim JH, Ryu DM, Lee BS, Kwon YD. Analysis of digitalized panorama and cone beam computed tomographic image distortion for the diagnosis of dental implant surgery. *J Craniofac Surg* 2011;22:669-673.
9. Schropp L, Stavropoulos A, Gotfredsen E, Wenzel A. Comparison of panoramic and conventional cross-sectional tomography for preoperative selection of implant size. *Clin Oral Implants Res* 2011;22:424-429.
10. Lindh C, Petersson A, Klinge B. Visualisation of the mandibular canal by different radiographic techniques. *Clin Oral Implants Res* 1992;3:90-97.
11. Sonick M. A comparison of the accuracy of periapical, panoramic, and computerized tomographic radiographs in locating the mandibular canal. *Int J Oral Maxillofac Implants* 1994;9:455-460.
12. Kitai N, Mukai Y, Murabayashi M, Kawabata A, Washino K, Matsuoka M, Shimizu I, Katsumata A. Measurement accuracy with a new dental panoramic radiographic technique based on tomosynthesis. *Angle Orthod* 2013;83:117-126.
13. Nikneshan S, Sharafi M, Emadi N. Evaluation of the accuracy of linear and angular measurements on panoramic radiographs taken at different positions. *Imaging Sci Dent* 2013;43:191-196.
14. Vazquez L, Nizam Al Din Y, Christoph Belser U, Combescure C, Bernard JP. Reliability of the vertical magnification factor on panoramic radiographs: clinical implications for posterior mandibular implants. *Clin Oral Implants Res* 2011;22:1420-1425.
15. Vazquez L, Nizamaldin Y, Combescure C, Nedir R, Bischof M, Dohan Ehrenfest DM, Carrel JP, Belser UC. Accuracy of vertical height measurements on direct digital panoramic radiographs using posterior mandibular implants and metal balls as reference objects. *Dentomaxillofac Radiol* 2013;42:20110429.
16. Tal H, Moses O. A comparison of panoramic radiography with computed tomography in the planning of implant surgery. *Dentomaxillofac Radiol* 1991;20:40-42.
17. Volohansky A, Cleaton-Jones P, Drummond S, Bönecker M. Technique for linear measurement on panoramic and periapical radiographs: a pilot study. *Quintessence Int* 2006;37:191-197.
18. Frei C, Buser D, Dula K. Study on the necessity for cross-section imaging of the posterior mandible for treatment planning of standard cases in implant dentistry. *Clin Oral Implants Res* 2004;15:490-497.
19. Stramotas S, Geenty JP, Petocz P, Darendeliler MA. Accuracy of linear and angular measurements on panoramic radiographs taken at various positions in vitro. *Eur J Orthod* 2002;24:43-52.
20. Renouard F, Nisand D. Impact of implant length and diameter on survival rates. *Clin Oral Implants Res* 2006;17:35-51.
21. Degidi M, Piattelli A, Iezzi G, Carinci F. Do longer implants improve clinical outcome in immediate loading? *Int J Oral and Maxillofac Surg* 2007;36:1172-1176.
22. Vazquez L, Saulacic N, Belser U, Bernard JP. Efficacy of panoramic radiographs in the preoperative planning of posterior mandibular implants: a prospective clinical study of 1527 consecutively treated patients. *Clin Oral Implants Res* 2008;19:81-85.
23. Schropp L, Wenzel A, Kostopoulos L. Impact of conventional tomography on prediction of the appropriate implant size. *Oral Surg Oral Med Oral Pathol Oral Radiol Endod* 2001;92:458-463.

24.Lindh C, Petersson A, Klinge B. Measurements of distances related to the mandibular canal in radiographs. Clin Oral Implants Res 1995;6:96-103.

25.Yassaei S, Ezoddini-Ardakani F, Ostovar N. Predicting the actual length of premolar teeth on the basis of panoramic radiology. Indian J Dent Res 2010;21:468-473.

Corresponding Author

Burak Kerem Apaydin

Pamukkale University

Faculty of Dentistry,

Department of Dentomaxillofacial Radiology,

Denizli, Turkey

Tel : +90 258 2964225

Fax : +90 258 2961763

E-mail : drkeremapaydin@gmail.com

Conflict of interest: The authors declare that they have no conflict of interest.



NUMBER OF FILE USAGE ON DENTINAL DEFECT INCIDENCE OF WAVEONE GOLD AND RECIPROC NITI INSTRUMENTS

WaveOne GOLD ve Reciproc NiTi Kanal Aletlerinin Kullanım Sayısının Dentin Defekti Oluşturma İnsidansı Üzerine Etkisinin İncelenmesi

Taha ÖZYÜREK¹, Koray YILMAZ², Gülşah USLU³

Makale Kodu/Article Code : 423644

Makale Gönderilme Tarihi : 15.05.2018

Kabul Tarihi : 26.07.2018

ABSTRACT

Objectives: To compare the incidences of dentinal defects caused by Reciproc and WaveOne GOLD NiTi files during root canal preparation and to exam the effect of number of file usage on the incidence of dentinal defect.

Materials and Methods: Two hundred seventy mandibular incisor teeth were randomly divided into 3 different groups as follows: negative control (no preparation performed) (n: 30), Reciproc (n: 120) and WaveOne GOLD (n: 120) groups. The specimens were sliced at 3, 6 and 9 mm from the apex. Microscopic pictures of the specimens were taken with the aid of light emitting diode and the dentinal defects were examined.

Results: There was no statistically difference among the WaveOne GOLD, Reciproc and control groups in terms of dentinal defect formation. The number of dentinal defects occurred in apical region in Reciproc group following 4th use was found to be statistically higher than 1st, 2nd, and 3rd use in WaveOne GOLD group (p < .05).

Conclusion: All the NiTi files tested in present study were found to cause defect in root canal dentin but there were not significant difference among the WaveOne GOLD, Reciproc and control groups in term of total dentinal defect formation

Keywords: Reciproc; WaveOne GOLD; Usage; Crack; Dentinal Defect

ÖZ

Amaç: Kök kanal preperasyonu sırasında Reciproc ve WaveOne GOLD NiTi kanal aletlerinin neden olduğu dentinal defekt vakalarını karşılaştırmak ve eğe kullanım sayısının dentinal defekt insidansı üzerindeki etkisini incelemek.

Materyal ve Metot: İki yüz yetmiş adet mandibular kesici diş çalışmaya dahi edildi ve rastgele 3 gruba ayrıldı. Negatif kontrol grubu (n = 30) herhangi bir işlem yapılmadı, 120'şer diş de reciproc ve waveone gold gruplarına yerleştirildi. Örneklerden apekten 3, 6 ve 9 mm uzakta olucak şekilde yatay kesitler alındı ve light emitting diode lazer yardımı ile çekilen fotoğraflarda dentinal defekt varlığı araştırıldı.

Bulgular: WaveOne GOLD, Reciproc ve kontrol grupları arasında dentinal defect oluşumu açısından istatistiksel olarak anlamlı bir fark yoktur. Resiproc egesinin 4. Kullanımı sonrası apical bölgede oluşturduğu dentinal defect sayısı WaveOne GOLD grubunun 1., 2. ve 3. Kullanımları sonrası oluşan sayudan istatistiksel olarak anlamlı derecede fazladır (p < ,05).

Sonuç: Çalışmamızda test ettiğimiz tüm NiTi eğerler kök kanal dentininde defect oluşumuna neden oldu ancak WaveOne GOLD, Reciproc ve kontrol grupları arasında toplam dentin defekti oluşumu açısından istatistiksel olarak anlamlı bir fark bulunmadı.

Anahtar Kelimeler: Reciproc; WaveOne Gold; Kullanım; Çatlak; Dentin defekti

¹ Department of Endodontics, Faculty of Dentistry, Medeniyet University, İstanbul, Turkey

² Department of Endodontics, Faculty of Dentistry, Mustafa Kemal University, Hatay, Turkey

³ Department of Endodontics, Faculty of Dentistry, Çanakkale Onsekiz Mart University, Çanakkale, Turkey

INTRODUCTION

Root canal preparation is one of the most important phases of a successful root canal treatment.¹ As a result of the contact between the file and the canal walls during root canal preparation, momentary stress accumulations may occur and these stresses may cause defects in dentin.² Occurring dentinal defects may result in vertical fractures due to recurrent endodontic treatments, restorative procedures, and occlusal loads.³

Under favor of their clockwise rotation, the reciprocal single-file systems, which drew attention and became popular since they were introduced to the market, decrease the level of stress that the files are exposed within the canal and increase their cyclic fatigue resistance in proportion to continuous rotation file systems.⁴ Reciproc (RPC; VDW, Munich, Germany) and WaveOne (WO; Dentsply Maillefer, Baillagues, Switzerland) are the most popular single-file systems that complete 360° with different degrees of rotation in clockwise and counterclockwise directions.⁵

WO files were recently modified to WaveOne GOLD (WOG; Dentsply Maillefer) files. While maintaining the reciprocation movement of file, its cross-section, dimensions and geometry were changed. The cross-section of file was altered to parallelogram having 2 cutting edges. Moreover, the off-center design that ProTaper Next (Dentsply Maillefer) files have was used also in WaveOne GOLD files. The most significant change in files is the production employing GOLD heat treatment. GOLD heat treatment is performed by reversing the M-Wire technology utilizing pre-production heat treatment, and by manually heating the file after production and then slowly cooling it. The manufacturer company claims that new GOLD heat treatment increases the flexibility of files.⁶

In many studies, it has been reported that the cyclic fatigue resistance of NiTi files significantly decreased following the clinic use for long time.^{7, 8} But, in literature, there is no

consensus on after how many uses the NiTi files should be discarded. In their *in vivo* study on examining the cyclic fatigue resistance of ProFile (Dentsply Maillefer) files after the use, Yared *et al.*⁹ have reported that there was no statistically significant difference between the files that have been used in molar teeth and the non-used files. Researchers have emphasized that ProFile files could be securely used in 4 molar teeth having averagely 3 canals. But, on the other hand, Wolcott *et al.*¹⁰ have reported in their *in vivo* study that the ProTaper Universal (Dentsply Maillefer) NiTi files, which they have used in shaping totally 4652 canals, can be securely used in up to 4 canals.

In comprehensive literature review, no study examining the effect of number of use of NiTi files on the incidence of dentinal defects was found. For this reason, the aim of present *in vitro* study was determined to be the comparison of incidences of dentinal defects caused by Reciproc and WaveOne GOLD NiTi files during shaping the mandibular incisor teeth's root canals and the examination of effect of number of file usage on the incidence of dentinal defect. The first null hypothesis of present study was that there would be no difference between the dentinal defect incidences of Reciproc and WaveOne GOLD files. Second null hypothesis was that the number of use of files would have no effect on the incidence of dentinal defect formation.

MATERIALS AND METHODS

Specimen Selection

Two hundred seventy mandibular incisor teeth having straight canals, which have been extracted due to periodontal reasons, were selected. The soft and hard tissues around the teeth were mechanically removed using a periodontal curette. The crowns of teeth were removed from the enamel-cement junction under water-cooling in the way allowing 14 mm of root length. The radiographic images of teeth were taken in mesio-distal and bucco-lingual directions. The teeth have calcification, having

history of previous root canal treatment, involving internal and/or external resorption, or fractured and/or having immature roots were excluded. The selected teeth were kept in distilled water at 4°C for the experimental procedures.

The roots of teeth were wrapped with aluminum foil and then embedded into acrylic resin (Imicryl, Konya, Turkey).¹¹ After the acrylic resin set, the teeth were taken out from the resin, and the foils were removed. To simulate the periodontal ligament, the resin blocks were filled with viscous silicon impression material (Express XT Light Body Quick; 3M ESPE, Neuss, Germany) and the specimens were then placed into the resin blocks again.

Root Canal Preparation

The canals of teeth were penetrated using #10 K-file (Dentsply Maillefer) until the tip of file is seen from the apex. The working length was set to 1 mm shorter than this length. For all of the specimens, the glide path was created ensuring the apical diameter of #15. For each of specimens, 20 ml 1% sodium hypochlorite (NaOCl) was used during the preparation. The entire procedure was executed by the same endodontist having 5 years of experience. Thirty non-treated specimens were assigned as negative control group.

Root Canal Preparation

Group 1: Reciproc

A hundred twenty specimens in this group were then divided into 4 sub-groups (1A, 2A, 3A and 4A), 30 specimens in each. The specimens in Group 1A were prepared using 30 non-used Reciproc R25 (25/.08) files and VDW Gold Reciproc (VDW) endodontic motor utilizing “Reciproc ALL” program of endodontic motor. And then, these files were used in preparation of specimens in Groups 2A, 3A and 4A, respectively. Thus, the dentinal defects on specimens in Group 1A were examined after 1st use, those of specimens in Group 2A after 2nd

use, those of specimens in 3A following 3rd use, and those of specimens in Group 4A after 4th use.

Group 2: WaveOne GOLD

A hundred twenty specimens in this group were then divided into 4 sub-groups (1B, 2B, 3B and 4B), 30 specimens in each. The specimens in Group 1B were prepared using 30 non-used WaveOne GOLD Primary (25/.07) files and VDW Gold Reciproc (VDW) endodontic motor utilizing “WaveOne ALL” program of endodontic motor. And then, these files were used in preparation of specimens in Groups 2B, 3B and 4B, respectively. Thus, the dentinal defects on specimens in Group 1A were examined after 1st use, those of specimens in Group 2A after 2nd use, those of specimens in 3A following 3rd use, and those of specimens in Group 4A after 4th use.

Assessment of Dentinal Defects

Under water-cooling (Isomet; Buehler Ltd, Lake Bluff, IL, USA), the roots of 270 specimens were cut perpendicular to tooth axis at 3, 6, and 9 mm distant from the apex, and 3 slices were obtained from each specimen. Trans-illumination was applied to the slices from 1 mm distance in mesial, distal, buccal, and lingual directions using light emitting diode (LED; LED Light; Denshine Technology, China) device. The digital images (4 images from each slice) were taken under x25 magnification using a digital camera connected to stereomicroscope (Olympus BX43, Olympus Co., Tokyo, Japan). Totally 3240 digital images, 360 from each sub-group, were examined in terms of the presence of any crack. The images obtained were randomly assigned to 2 experienced endodontists, who were not involved in the preparation of the specimens, in order to determine the presence or absence of dentinal defects. To define crack formation, 2 different categories were made (“no crack” and “crack”) in order to avoid the confusing description of root cracks. “No crack” was defined as the root dentin without cracks or

craze lines either at the internal surface of the root canal wall or the external surface of the root. “Crack” was defined as all lines observed on the slice that either extended from the root canal lumen to the dentin or from the outer root surface into the dentin.¹²

Statistical Analyses

In examining the intergroup incidence of dentinal defects, Chi-Square test was utilized. The level of statistical significance was set to 5%. The statistical analyses were performed using SPSS 21 (IBM-SPSS Inc., Chicago, IL, USA) software.

RESULTS

In present study, totally 3240 images from 810 tooth slices were examined. The distribution of the numbers dentinal defects caused following 1st, 2nd, 3rd, and 4th use in RPC and WOG groups by the apical, middle, and coronal regions are presented in Table 1.

Table 1. The Number and Percentage of Slices with Defect after Different Number of Usage at Each Level (n =30)

	Reciproc Group				WaveOne GOLD Group				
	3 mm n (%)	6 mm n (%)	9 mm n (%)	Total of specimens of presenting defects n (%)	3 mm n (%)	6 mm n (%)	9 mm n (%)	Total of specimens of presenting defects n (%)	
Control Group	8 (26.7%) ^a	12 (40%) ^a	10 (33.3%) ^a	14 (46.7%) ^a	8 (26.7%) ^a	12 (40%) ^a	10 (33.3%) ^a	14 (46.7%) ^a	
Number of Use	1st	10 (33.3%) ^a	15 (50%) ^a	10 (33.3%) ^a	15 (50%) ^a	9 (30%) ^a	14 (46.7%) ^a	8 (26.7%) ^a	15 (50%) ^a
	2nd	10 (33.3%) ^a	16 (53.3%) ^a	11 (36.7%) ^a	18 (60%) ^a	9 (30%) ^a	15 (50%) ^a	10 (33.3%) ^a	18 (60%) ^a
	3rd	16 (53.3%) ^a	18 (60%) ^a	14 (46.7%) ^a	22 (73.3%) ^a	14 (46.7%) ^a	17 (56.7%) ^a	12 (40%) ^a	20 (66.7%) ^a
	4th	22 (73.3%) ^a	18 (60%) ^a	15 (50%) ^a	26 (86.7%) ^a	20 (66.7%) ^a	18 (60%) ^a	13 (43.3%) ^a	25 (83.3%) ^a
Pvalue	< .05	> .05	> .05	> .05	> .05	> .05	> .05	> .05	

*Different superscripts indicate statistically different at p = .05.

It was determined that the total number of defects in RPC and WOG groups increased following 1st, 2nd, 3rd, and 4th use in proportion to control group but the difference was not statistically significant (p> .05) (Figure 1).

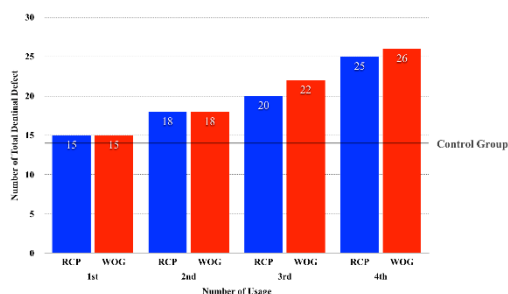


Figure 1. The number of total dentinal defects in the WaveOne GOLD and the Reciproc group after 1, 2, 3 and 4 usage. There was no significant difference among the groups (P > .05).

On the other hand, the number of dentinal defects occurred in apical region in RPC group following 4th use was found to be statistically higher than the control group and 1st, 2nd, and 3rd use in WOG group (p<.05). Furthermore, no statistically significant difference was observed between WOG and RPC groups in terms of total dentinal defect formation (p>.05).

DISCUSSION

In present study, it was aimed to compare the incidences of dentinal defect caused by Reciproc and WaveOne GOLD NiTi files during shaping the root canals of mandibular incisor teeth and to examine the effects of number of use of files on the defect formation incidence. According to the obtained results, it was determined that dentinal defects formed by all of the tested NiTi files but there was no statistically significant difference between the defect incidences among the RPC, WOG and control groups. For this reason, first null hypothesis of the present study was accepted. Moreover, it was determined that the number of the usage of files didn’t affected the total dentinal defect formation incidence during the root canal shaping procedures, second null hypothesis was also accepted.

The manufacturers of WOG and RPC NiTi files recommend using the files on single tooth. Based on the preparation of 4-canal maxillary first molar tooth, the files were assumed to be used for 4 times in the present study.¹³ It has been reported that use of larger files in shaping the root canals increased the incidence of dentinal defect formation.¹⁴ For this reason, in present study, the apical diameter of files was determined to be 0.25 mm, and no larger file was used. Moreover, in order to protect the microstructure of dentin, 1% NaOCl was used as irrigation solution. Thus, it was aimed to ensure most of the dentinal defects to be related with the mechanic preparation.

It has been reported that the forces applied while extracting the teeth and the stress during storing the teeth and obtaining the slices might

cause dentinal defect.¹⁵ This may explain the formation of dentinal defects in negative control group, where no intervention was made in present study. The studies employing classical method of sectioning have failed in determining these defects in negative control groups (16). When illumination was applied on the obtained dentin slices, the light moves along the dentin, but it stops at the point of any crack on dentin and thus the presence of crack and/or fracture can be determined.¹⁶ In study of Coelho *et al.*¹⁷, the dentinal defects could be determined in many specimens in negative control groups by employing LED. For this reason, LED trans-illumination was employed in present study.

The use of reciprocation movement with single-file NiTi systems in preparation of straight and curved root canals rather as an alternative to continuous rotation movement became very popular.¹⁸ Under favor of higher degree of reciprocation movement of file in counterclockwise (cutting) direction than the movement in clockwise (relax of file) direction, and the file moves towards the apical. It has been reported in many studies that the reciprocation movement increases the fatigue of file by declining the tension and compaction forces that the file is exposed to within the canal.¹⁹ According to the manufacturer, the single-use NiTi files can be use in up to 3-4 canals in the same molar teeth or for the same patient (6). But, however, the root canal preparation procedure may lead defects on the file's surface²⁰ and this might decrease the cutting efficiency of the file.²¹ Pirani *et al.*²² have reported that, in their study on examining the surficial properties of RPC and WO NiTi files after 1st and 3rd use, the number of use didn't significantly affect the amplitudes of defects seen on the files. Researchers have argued that the use of files up to 3 times would be safe. Similarly, Gambarini *et al.*²³ have examined the cutting efficiencies of Twisted File (Axis/SybronEndo, Orange, CA, USA) files after 1st and 10th use, and have reported that the number of use of files didn't significantly

influence the cutting efficiency. On the other hand, Seago *et al.*²⁴ have investigated and compared the cutting efficiencies and flexibilities of HyFlex CM (Coltene-Whaledent, Allstetten, Switzerland) files after 1st and 10th use and after sterilization and reported that the cutting efficiencies significantly declined after 2nd and 3rd use and 7th, 8th and 9th use. Moreover, the micro-cracks and defects on the surfaces of NiTi files used in SEM studies and the deteriorations on the cutting edges have been reported.²⁵ Although the differences were statistically non-significant, the deformation may be shown as a reason for the increase in the dentinal defect incidence seen in specimens alongside the increase in the number of use.

El Nasr and El Kader²⁶ have reported that the mechanical properties of the alloy, of which the files were made, affected the dentinal defects occurred while preparation of the root canals. Plotino *et al.*²⁷, in their study on comparing the cutting efficiencies of RPC and WO NiTi files, have reported that RPC files had statistically significantly better cutting efficiency than WO files. The authors have attributed this result to the cross-section of RPC file and its positive cutting angle. Moreover, the authors have argued that, regardless of the movement type of the files, the cross-section played significant role in their cutting efficiencies. Similar to the study of Plotino *et al.*²⁸, the studies have reported that NiTi rotary file systems having S-shaped cross-section and 2 cutting edges had advanced cutting properties²⁹ Besides the cross-section of files, also their efficiency in removal of debris play significant role, because unremoved debris within the canals would occlude the cutting blades of files.³⁰ It is thought that, under favor of the S-shaped cross-section of RPC file used in present study and the off-center design of WOG file, they have high level of dentin removal efficiencies and thus high level of cutting efficiencies, and that this caused

dentinal defect at the statistically same level with control group.

Similar to the results of present study, Coelho *et al.*¹⁸ have investigated the dentinal defects caused by ProFile (Dentsply Maillefer), TRUShape (Dentsply Maillefer) and WaveOne GOLD systems during shaping the mesial canals of mandibular molar teeth by using light-emitting diode and reported that there was no statistically difference between the experimental groups and the negative control groups. Moreover, Karataş *et al.*³¹ have also examined the dentinal cracks on mandibular incisor teeth caused by ProTaper Universal, ProFile Vortex (Dentsply Maillefer), ProTaper GOLD, Reciproc (VDW, Munich, Germany), and F360 (Komet Brasseler, Lemgo, Germany), and reported that there was statistically non-significant difference between ProTaper Universal, ProFile Vortex, ProTaper GOLD and Reciproc groups in terms of dentinal defect formation. These results corroborate the findings of present study.

Kim *et al.*³² have reported that the stress in apical region during root canal shaping was higher than the medial and coronal regions. Despite the results of that study, Versluis *et al.*³³ have reported that the level of stress occurring in coronal and middle third during root canal shaping was 3 times higher than the stress in apical third. Similar to the results of Versluis *et al.*'s study, even though the difference was statistically non-significant except for the 4th use groups, more dentinal defects were found in medial third in present study. The deformation at the tip of files is believed to be the reason for more dentinal defect in apical region after 4th use.

Even though it was paid importance to imitate the clinic conditions in laboratory environment in present study, especially in the studies on examining the mechanical properties of teeth, many external factors such as storing the teeth after extraction and until the sectioning procedure affect the results of study.³⁴ For this

reason, as stated in study of Coelho *et al.*³⁵, the use of teeth extracted using periodontal reasons, which require very low level of force during extraction, and the careful storage of these teeth until the sectioning procedures would allow more successful outcomes.

One of the limitations of present study is the difficulty of standardization of apical pressure applied by the operator during root canal shaping procedure.

CONCLUSION

All of the NiTi files tested in present study were found to cause defect in root canal dentin. However, it has not been revealed yet if the dentinal defects occurring root canal shaping have any effect or importance on the success of endodontic treatment from clinical aspect. For this reason, *in vivo* studies examining the role of dentinal defects, which occur during root canal shaping procedures, on the endodontic failure are needed.

ACKNOWLEDGEMENT

The author denies any conflicts of interest related to this study. his article was presented as an oral presentation at ESE 2017 congress.

REFERENCES

1. Peters OA. Current challenges and concepts in the preparation of root canal systems: a review. *J Endod* 2004;30:559-67.
2. Blum J, Cohen A, Machtou P, Micallef JP. Analysis of forces developed during mechanical preparation of extracted teeth using Profile NiTi rotary instruments. *Int Endod J* 1999;32:24-31.
3. Yoldas O, Yilmaz S, Atakan G, Kuden C, Kasan Z. Dentinal microcrack formation during root canal preparations by different NiTi rotary instruments and the self-adjusting file. *J Endod* 2012;38:232-5.
4. Kiefner P, Ban M, De-Deus G. Is the reciprocating movement per se able to improve the cyclic fatigue resistance of instruments? *Int Endod J* 2014;47:430-6.

5. Bürklein S, Hinschitzka K, Dammaschke T, Schäfer E. Shaping ability and cleaning effectiveness of two single-file systems in severely curved root canals of extracted teeth: Reciproc and WaveOne versus Mtwo and ProTaper. *Int Endod J* 2012;45:449-61.
6. WaveOne GOLD brochure. https://www.dentsply.com/content/dam/dentsply/pim/manufacturer/Endodontics/Obturation/Gutta_Percha_Points/WaveOne_Gold_Gutta_Percha_Points/W1G_Brochure_EN.pdf (Access in November 2016).
7. Gambarini G. Cyclic fatigue of ProFile rotary instruments after prolonged clinical use. *Int Endod J* 2001;34:386-9.
8. Bahia MGA, Bueno VTL. Decrease in the fatigue resistance of nickel-titanium rotary instruments after clinical use in curved root canals. *Oral Surg Oral Med Oral Pathol Oral Radiol Endod* 2005;100:249-55.
9. Yared G, Dagher F, Machtou P. Cyclic fatigue of ProFile rotary instruments after clinical use. *Int Endod J* 2000;33:204-7.
10. Wolcott S, Wolcott J, Ishley D, Kennedy W, Johnson S, Minnich S, et al. Separation incidence of protaper rotary instruments: a large cohort clinical evaluation. *J Endod* 2006;32:1139-41.
11. Capar ID, Arslan H, Akcay M, Uysal B. Effects of ProTaper Universal, ProTaper Next, and HyFlex instruments on crack formation in dentin. *J Endod* 2014;40:1482-84.
12. Shemesh H, Bier C, Wu MK, Tanomaru-Filho M, Wesselink P. The effects of canal preparation and filling on the incidence of dentinal defects. *Int Endod J* 2009;42:208-13.
13. Hin ES, Wu M-K, Wesselink PR, Shemesh H. Effects of self-adjusting file, Mtwo, and ProTaper on the root canal wall. *J Endod* 2013;39:262-4.
14. Capar ID, Uysal B, Ok E, Arslan H. Effect of the size of the apical enlargement with rotary instruments, single-cone filling, post space preparation with drills, fiber post removal, and root canal filling removal on apical crack initiation and propagation. *J Endod* 2015;41:253-6.
15. De-Deus G, Silva EJNL, Marins J, Souza E, de Almeida Neves A, Belladonna FG, et al. Lack of causal relationship between dentinal microcracks and root canal preparation with reciprocation systems. *J Endod* 2014;40:1447-50.
16. American Association of Endodontists. Transillumination: The "Light Detector." Chicago: AAE; 2008:1-2.
17. Coelho MS, Card SJ, Tawil PZ. Visualization Enhancement of Dentinal Defects by Using Light-Emitting Diode Transillumination. *J Endod* 2016;42:1110-3.
18. Coelho MS, Card SJ, Tawil PZ. Light-emitting Diode Assessment of Dentinal Defects after Root Canal Preparation with Profile, TRUShape, and WaveOne Gold Systems. *J Endod* 2016;42:1393-6.
19. Kim H-C, Kwak S-W, Cheung GS-P, Ko D-H, Chung S-M, Lee W. Cyclic fatigue and torsional resistance of two new nickel-titanium instruments used in reciprocation motion: Reciproc versus WaveOne. *J Endod* 2012;38:541-4.
20. Plotino G, Grande N, Testarelli L, Gambarini G. Cyclic fatigue of Reciproc and WaveOne reciprocating instruments. *Int Endod J* 2012;45:614-8.
21. Yamazaki-Arasaki A, Cabrales R, Santos MD, Kleine B, Prokopowitsch I. Topography of four different endodontic rotary systems, before and after being used for the 12th time. *Micros Res Tech* 2012;75:97-102.
22. Sattapan B, Nervo GJ, Palamara JE, Messer HH. Defects in rotary nickel-titanium files after clinical use. *J Endod* 2000;26:161-5.
23. Pirani C, Paolucci A, Ruggeri O, Bossù M, Polimeni A, Gatto MRA, et al. Wear and metallographic analysis of WaveOne and

Reciproc NiTi instruments before and after three uses in root canals. *Scanning* 2014;36:517-25.

24.Gambarini G, Rubini AG, Sannino G, Di Giorgio F, Piasecki L, Al-Sudani D, et al. Cutting efficiency of nickel–titanium rotary and reciprocating instruments after prolonged use. *Odontology* 2016;104:77-81.

25.Peng B, Shen Y, Cheung G, Xia T. Defects in ProTaper S1 instruments after clinical use: longitudinal examination. *Int Endod J* 2005;38:550-7.

26.Arantes WB, da Silva CM, Lage-Marques JL, Habitante S, da Rosa LCL, de Medeiros JMF. SEM analysis of defects and wear on Ni–Ti rotary instruments. *Scanning* 2014;36(4):411-418.

27.El Nasr HMA, El Kader KGA. Dentinal damage and fracture resistance of oval roots prepared with single-file systems using different kinematics. *J Endod* 2014;40:849-51.

28.Plotino G, Rubini AG, Grande NM, Testarelli L, Gambarini G. Cutting efficiency of Reciproc and WaveOne reciprocating instruments. *J Endod* 2014;40:1228-30.

29.Schäfer E, Erler M, Dammaschke T. Comparative study on the shaping ability and cleaning efficiency of rotary Mtwo instruments. Part 1. Shaping ability in simulated curved canals. *Int Endod J* 2006;39:196-202.

30.Bergmans L, Van Cleynenbreugel J, Wevers M, Lambrechts P. Mechanical root canal preparation with NiTi rotary instruments: rationale, performance and safety. *Am J Dent* 2001;14:324-33.

31.Karataş E, Gündüz H, Kırıcı D, Arslan H. Incidence of dentinal cracks after root canal preparation with ProTaper Gold, Profile Vortex, F360, Reciproc and ProTaper Universal instruments. *Int Endod J* 2016;49:905-10.

32.Kim H-C, Lee M-H, Yum J, Versluis A, Lee C-J, Kim B-M. Potential relationship between

design of nickel-titanium rotary instruments and vertical root fracture. *J Endod* 2010;36:1195-9.

33.Versluis A, Messer H, Pintado M. Changes in compaction stress distributions in roots resulting from canal preparation. *Int Endod J* 2006;39:931-9.

34.Bürklein S, Tsotsis P, Schäfer E. Incidence of dentinal defects after root canal preparation: reciprocating versus rotary instrumentation. *J Endod* 2013;39:501-4.

35.Coelho MS, Card SJ, Tawil PZ. Light-emitting Diode Assessment of Dentinal Defects after Root Canal Preparation with Profile, TRUShape, and WaveOne Gold Systems. *J Endod* 2016;42:1393-6.

Corresponding Author

Koray YILMAZ

Mustafa Kemal University

Faculty of Dentistry

Department of Endodontics

Hatay, Turkey

E-mail : koray1903@hotmail.com



EVALUATION OF CARABELLI'S TRAIT IN A GROUP OF TURKISH PATIENTS

Bir Grup Türk Hastada Karabelli Özelliğinin Değerlendirilmesi

Mağrur KAZAK

Makale Kodu/Article Code : 414992

Makale Gönderilme Tarihi : 13.04.2018

Kabul Tarihi : 06.08.2018

ABSTRACT

Purpose: Dental morphological characteristics are useful for providing information in phylogenetic and genetic studies and also for understanding variations within and among species. Carabelli cusp is expressed in several degrees and in different frequencies among humans; thus, it is helpful in comparing and characterizing populations. The objective of this retrospective study was to evaluate Carabelli's trait (CT) in a group of Turkish patients.

Materials and Methods: In this study, 213 patients between age of 14-65 (mean age 29.99 ± 10.04) were analyzed retrospectively according to presence or absence of CT on permanent maxillary first and second molars. All data were statistically analyzed using the IBM SPSS version 22 program (IBM SPSS, Turkey) and the chi-squared test; $p < 0.05$ was considered as statistically significant.

Results: Prevalence of CT was found to be 47.9% in the selected Turkish group. Incidence of CT in any of the teeth on #16/26 was 46.9% and 4.2% on #17/27. Incidence was detected more on #26 (43.2%) than on #16 (40.4%). Bilateral presence of CT on #16/26 was detected in 78%. CT was seen in 50.7% of females and in 42.9% of males. There was no statistically significant difference between genders ($p > 0.05$).

Conclusions: Expression of CT can be placed in moderate prevalence group. There was no sexual dimorphism in its occurrence in the studied group. CT can be a valuable criterion to determine differences among various populations and a significant insight into the migratory patterns in a selected geographical area.

Key Words: Carabelli's trait, Non-metric trait, Dental morphological feature, Sexual dimorphism, Maxillary molars

ÖZ

Amaç: Diş morfolojik özellikleri, filogenetik ve genetik çalışmalarda bilgi sağlamak ve ayrıca türler içinde ve türler arasında varyasyonları anlamak için yararlıdır. Karabelli tüberkülü insanlarda çeşitli derecelerde ve farklı frekanslarda tespit edildiğinden, popülasyonları karşılaştırmakta ve karakterize etmek de yararlıdır. Bu retrospektif çalışmanın amacı, bir grup Türk hastada Karabelli özelliklerini (KÖ) değerlendirmektir.

Materyal ve Metod: Bu çalışmada, 14-65 yaş arası 213 hastanın (ortalama yaş 29.99 ± 10.04), sürekli maksiller büyük azı dişleri KÖ'nin varlığına veya yokluğuna göre retrospektif olarak incelendi. Tüm veriler, IBM SPSS sürüm 22 programı (IBM SPSS, Türkiye) ve ki-kare testi kullanılarak istatistiksel olarak analiz edildi. $p < 0,05$ istatistiksel olarak anlamlı kabul edildi.

Bulgular: Seçilen bir grup Türk hastada KÖ sıklığı %47,9 bulundu. 16/26 numaralı dişlerin herhangi birinde Karabelli görülme oranı %46,9 iken 17/27 numaralı dişlerde bu oran %4,2 olarak belirlendi. KÖ'nin görülme oranı 26 numaralı dişte (%43,2) 16 numaralı dişten (%40,4) daha fazla bulundu. KÖ'nin iki taraflı olarak 16/26 numaralı dişlerde görülme oranı %78 olarak saptandı. KÖ, kadınların %50,7'sinde, erkeklerin ise %42,9'unda görüldü. Cinsiyetler arasında istatistiksel olarak anlamlı bir fark belirlenmedi ($p > 0,05$).

Sonuçlar: Çalışılan grup KÖ açısından orta derece prevalans grubu içinde değerlendirilebilir. KÖ'nin oluşumu açısından cinsiyet farklılığı bulunmamaktadır. KÖ, çeşitli popülasyonlar arasındaki farklılıkları belirlemek ve seçilmiş bir coğrafi alandaki göçmen gruplar hakkında önemli bir fikir edinmek için değerli bir kriter olabilir.

Anahtar Kelimeler: Karabelli özelliği, Metrik olmayan özellik, Diş morfolojik özellik, Cinsiyet farklılıkları, Maksiller büyük azı dişleri

INTRODUCTION

Carabelli is a tubercle, cusp, or groove usually found at the palatal surface of the mesiopalatal cusp of maxillary permanent first molars and maxillary deciduous second molars.^{1-3,4} It can also be detected on the maxillary permanent second and third molars, although considerably less frequently than on the first molars.⁴ Carabelli cusp has usually been found bilaterally.^{1,3} Although it was pointed out that the frequency appeared to be higher in men than in women, no significant sexual dimorphism was observed.³

Carabelli's cusp is absent in some people. Due to numerous variations in cusp size and shape, the term Carabelli's trait (CT) is customarily used.⁵

The phenotypical appearance of the CT is a result of interaction between genetic and environmental factors.⁶ The genetic factors underlying the expression of CT are best represented by the upper first molars, which are used as the key teeth for population comparisons.⁷

All human populations have some degree of dental morphological variation. It is commonly accepted that dental characteristics, such as size, shape, presence, number of cusps, and the size of the dental arches, are genetically determined.⁸

In the literature, it was found that the frequency of this structure varies from population to population.⁹⁻¹³ Interestingly, studies about the prevalence of CT in the Turkish population have not been reported to date. Substantially, this trait may provide a valuable criterion for racial differentiations among various populations and a significant insight into the migratory patterns of communities in a selected geographical area. Also, CT can be useful in establishing phylogenetic relationships among closely related populations.¹⁴ Therefore, it would be important to investigate this trait among nations which

were not previously considered. Herewith, the aim of this retrospective study was to evaluate the prevalence of CT on maxillary permanent first and second molar teeth in a group of Turkish patients.

MATERIALS AND METHODS

In this retrospective study, dental records of 420 patients referred to the Restorative Dentistry Department, Faculty of Dentistry, Istanbul Aydın University in Istanbul, Turkey from January 2014 to January 2015 were examined. The project has been reviewed and approved by the Ethical Committee of Istanbul Aydın University, Faculty of Dentistry, Istanbul (25.11.2015 and No: 073). All healthy permanent maxillary first (16/26) and second molars (17/27) as well as the 16/26 and 17/27 molars that did not have dental caries or restorations were included in the study. In addition, four permanent maxillary molars that missed on any side were also eliminated. After excluding improper data, a total of 213 patients between age of 14 to 65 were evaluated according to the presence or absence of CT.

Statistical analysis

All data were statistically analyzed with the IBM SPSS version 22 program (IBM SPSS, Turkey) and the chi-squared test. $P < 0.05$ was considered as statistically significant.

RESULTS

A total of 213 patients (852 teeth) between age of 14 to 65 (mean age 29.99 ± 10.04) were examined. Of the total patients, 36.2% were males (n:77) and 63.8% were females (n:36). The male/female ratio was 1:1.77. The prevalence of CT was 47.9% for the entire studied group. The incidence of CT in any of the teeth on #16/26 was 46.9% and 4.2% on #17/27 (Table 1).

Table 1. Prevalence of CT in the studied Turkish group

#	Presence	Absence	Total	%
16/26	100	113	213	46.9%
17/27	9	204	213	4.2%

The incidence of CT was detected more on #26 (43.2%) than on #16 (40.4%) (Table 2).

Table 2. Prevalence of CT on # 16, # 26, # 17, # 27

#	Presence	Absence	Total	%
16	86	127	213	40.4%
26	92	121	213	43.2%
17	7	206	213	3.3%
27	7	206	213	3.3%

The incidence of CT on #17 and #27 was the same (3.3%) (Table 2). Bilateral presence of CT on #16/26 was 78%; on #17/27 was 55.6% (Table 3); and on both #16/26/ and #17/27 simultaneously, it was found to be 1.9% (Table 4).

Table 3. Bilateral presence of CT on # 16/26, # 17/27

#	Bilateral presence	Total	%
16/26	78	100	78.0%
17/27	5	9	55.6%

Table 4. Bilateral presence of CT on all molar teeth

#	Bilateral presence	Total	%
16/26	78	213	36.6%
17/27	5	213	2.3%
16/26/17/27	4	213	1.9%

CT was observed in 50.7% of the females and in 42.9% of the males; there was no statistically significant difference between genders ($p > 0.05$) (Table 5).

Table 5. Incidence of CT according to gender

CT	Gender		p
	Female (n:136)	Male (n:77)	
	n (%)	n (%)	
Presence	50.7% (n:69)	42.9% (n:33)	0.269
Absence	49.3% (n: 67)	57.1% (n:44)	0.269

$p > 0.05$ Chi-Square test

DISCUSSION

Dental morphological traits are important because they are genetically determined, do not remodel during lifetime, and can be compared equally among different populations.¹⁵ CT is one of the non-metric traits that is considered to

be the most commonly occurring dental morphological feature.^{13,16} In European populations, the frequency of CT varies from 51 to 90%, which means it is included in the moderate to high prevalence group.^{3,4} However, the prevalence of this trait was 0% in Eskimos, 11% in Japanese, and 21% in Chinese populations, which means it is categorized in the low prevalence group.^{4,17-19} The prevalence of CT in the current study was found to be 47.9% which is lower than the European incidence and higher than the Arctic and Asian countries' averages. This result can be explained as follows: Turkey is an Eurasian country with land in both Asia and Europe.²⁰ Because it is located on two continents, it is necessary to focus on which groups the Turkish population belongs to. In 2001 Hanihara & Ishida²¹ divided the populations into six main groups (Eastern Asia, Arctic/New World, Pacific/Oceania, Central/South/West Asia, Europe, Africa) on the basis of linguistic, ethnological, and geographical backgrounds. In that study, Turkey was included in the West Asia group with two other countries (Israel and Cyprus); it was a subgroup of the Central/South/West Asia population. In another study by Hanihara²² Turkey was included in the West Asia group together with Afghanistan, Iran/Iraq, Israel, Syria/Palestine, and Cyprus. Reviewing the literature revealed that no studies have been conducted in Turkey about the prevalence of CT. Therefore, the studies previously done in the countries that were involved with the same group as Turkey should be focused on in order to correlate the presence of CT.

In one Iranian study, the cases of 500 adolescents were investigated, and the prevalence of CT was found to be 96.6%.¹⁰ In another Iranian study, 356 random cases were evaluated, and a total of 214 cases (61%) had Carabelli's cusp.²³ Although Turkish and Iranian populations were categorized in the same group, the prevalence of CT in both studies was found higher than in the present

study. These findings can be attributed to the fact that more individuals were evaluated in those studies. Different methods used in the studies could also have produced different results.

Cyprus is another country that should be evaluated for the prevalence of CT. Evaluating the first inhabitants of Cyprus and where they originated from, it was found that the most common origins of the early immigrants were from areas where the island was viewable from the mainland, including parts of present-day Turkey and Syria.²⁴ In 1977, Angel²⁵ evaluated the prevalence of CT in Cyprus and found that the frequency varied from 0% to 0.07% on M² and 0% to 0.37% on M¹. In the same study, Syria was examined for CT, and the frequency of this trait was found to be 0.07% on M² and 0.32% on M¹. Interestingly, the prevalence of CT in both studies was found to be lower than in the present study, even though Cyprus, Syria, and Turkey were categorized in the same population group. This can be attributed to the differences among the selected groups.

Peretz & Smith²⁶ evaluated the dental morphology and pathology of middle Bronze Age populations in Israel and observed the frequency of Carabelli's cusp on upper first molars. They found its incidence to be 25%–46%. The result of this study is consistent with the findings of our study.

In the literature, CT was found most frequently in first upper molars and was usually detected bilaterally.^{3,4,10,27-29} A correspondence between the higher prevalence of CT on 16/26 than on 17/27 and bilateralism is prominent in the literature, and this was found also to be the case in our study.

Simultaneous bilateral involvement of CT on maxillary permanent first and second molars accounted for 1.9% in the present study; this was in agreement with Falomo's findings.⁹

In some studies, no significant sexual dimorphism was observed in the occurrence of

the trait;^{3,9,30} however, in other studies, contrasting results were obtained.³¹⁻³³ In the present study, no statistically significant difference was detected between genders ($p > 0.05$) in terms of CT, although it was found that the trait was more frequent in females (50.7%) than in males (42.9%). Therefore, the results of the current study appear to confirm the suggestion made by Synder *et al.*³⁴ that sexual dimorphism varies between populations.

The limitation of this study was that it was conducted in a small group of patients who applied to the faculty. Therefore, based on the results of the present study, performing a study with more patients will benefit using Carabelli trait as a valuable criterion for determining differences between diverse populations and for gaining an important insight into groups of immigrants in a selected geographical area.

CONCLUSIONS

1. The expression of CT can be placed in the moderate prevalence group.
2. There was no sexual dimorphism in its occurrence in the studied group.
3. CT can be a valuable criterion to determine differences among various populations and a significant insight into the migratory patterns in a selected geographical area.

Acknowledgements

The author wishes to thank Ebru Osmanoğlu for the assistance in statistical evaluation.

Conflict of Interests

None declared.

REFERENCES

1. Subedi N, Sah S, Chataut T, Paudel S, Pradhan A. The prevalence of the Carabelli Trait in Selected Nepalese Population. *BJMMR* 2015;7:285-91.
2. Kraus BS. Carabelli's anomaly of the maxillary molar teeth; Observations on Mexicans and Papago Indians and an

- Interpretation of the Inheritance. *Am J Hum Genet* 1951;3:348-55.
3. Alvesalo L, Nuutila M, Portin P. The cusp of Carabelli. Occurrence in first upper molars and evaluation of its heritability. *Acta Odontol Scand* 1975;33:191-97.
 4. Sadatullah S, Odusanya SA, Mustafa A, Abdul Razak P, Abdul Wakab M, Meer Z. The prevalence of fifth cusp (Cusp of Carabelli) in the upper molars in Saudi Arabian school students. *Int J Morphol* 2012;30:757-60.
 5. Vodanovic M, Zukanovic A, Galic I, Harvey L, Savic Pavicin I, Dumancic J, Bedic Z, Njemirovskij V, Slaus M, Brkic H. Carabelli's trait in Croatian populations over 1800 years. *J Comp Hum Biol*, 2013; 64:273-85.
 6. Biggerstaff RH. Heritability of the Carabelli cusp in twins. *J Dent Res* 1973;52:40-4.
 7. Scott GR, Turner CG. The anthropology of modern human teeth. Dental morphology and its variation in recent human populations. Cambridge: Cambridge University Press, 1997.
 8. Brook AH, Jernvall J, Smith RN, Hughes TE, Townsend GC. The dentition: the outcomes of morphogenesis leading to variations of tooth number, size and shape. *Aust Dent J* 2014;59:131-42.
 9. Falomo OO. The cusp of Carabelli: frequency, distribution, size and clinical significance in Nigeria. *West Afr J Med* 2002;21:322-24.
 10. Ramin M. Prevalence of the carabelli trait in Iranian adolescents. *SRM J Res Dent Sci* 2013; 4:12-5.
 11. Lee GT, Goose DH. The inheritance of dental traits in a Chinese populations in the United Kingdom. *J Med Genet* 1972;9:336-39.
 12. Shaweesh, AI. Expression of Carabelli's trait in the Jordanian population. *J Stomat Occ Med* 2012;5:77-82.
 13. Mavrodisz K, Rozsa N, Budai M, Soos A, Pap I, Tarjan I. Prevalence of accessory tooth cusps in a contemporary and ancestral Hungarian population. *Eur J Orthod* 2007;29:166-69.
 14. Bermudez De, Castro JM. The Carabelli trait in human prehistoric populations of Canary Islands. *Biol Hum* 1989;61:117-31.
 15. Edgar HJ. Microevaluation of African American dental morphology. *Am J Phys Anthropol* 2007;132:535-44.
 16. Iriarte-Diaz J. Hominid Evolution, Dental Anthropology, and Human Variation, Copyright on text and original drawings, UIC Oral Sciences Osci 590, University of Illinois Chicago, 1999.
 17. Pederson PO. The east Greenland Eskimo dentition. Copenhagen, Blanco Lunos Bogtrykkeri., 1949;95-9.
 18. Carbonell VM. The tubercle of Carabelli in the Kish dentition, Mesopotamia, 3000 B. C. *J Dent Res* 1960;39:124-28.
 19. Oshima S. Dental anomalies of the Chinese. *J Orient Med* 1938;26:1149-150.
 20. Immerfall S, Therborn G. Handbook of European Societies: Social Transformations in the 21st Century. Springer, 2009. pp. 417.
 21. Hanihara T, Ishida H. Os incae: variation in frequency in major human population groups. *J Anat* 2001;198:137-52.
 22. Hanihara T. Morphological variation of major human populations based on nonmetric dental traits. *Am J Phys Anthropol* 2008;136:169-82.
 23. Kaviani R, Mackinejad SA, Rakhshan V, Falsafi M. Evaluating prevalence of talon and Carabelli's cusps in tooth examination of patients referred to Dental School of Islamic Azad University of Tehran: A 2-year study. *J Isfahan Dent Sch* 2014; 9:551-57.
 24. Fox Leonard SC. Comparative health from paleopathological analysis of the human skeletal remains dating the Hellenistic and Roman periods, from Paphos, Cyprus and Corinth, Greece, 1997 (Ph.D. Thesis).
 25. Angel JL. Appendix 5: Human Skeletons. In Kephala: A late neolithic settlement and cemetery, ed. JE Coleman, American School of Classical Studies, Princeton. 1977: pp 133-56.
 26. Peretz B, Smith P. Dental morphology and pathology of Middle Bronze Age populations in

Israel: Sasa and Jebel Qa'aqir. Atiqot 2004;46:45-9.

27.Hunter JP, Guatelli-Steinberg D, Weston TC, Durner R, Betsinger TK. Model of tooth morphogenesis predicts carabelli cusp expression, size, and symmetry in humans. PLoS ONE 2010;5: 11844.

28.Kamatham R, Nuvvula S. Expression of Carabelli trait in children from Southern India - A cross sectional study. J Forensic Dent Sci 2014;6:51-7.

29.Shethri SA. The prevalence of the Carabelli cusp in selected Saudi population. King Saud University Journal of Dental Science 2011; 2:13-6.

30.Kieser JA. An analysis of the Carabelli trait in the mixed deciduous and permanent human dentition. Arch Oral Biol, 1984;29:403-06.

31.Agnihotri G, Singla S, Singla R. Prevalence, expression, and dichotomous nature of Carabelli's trait in permanent dentition of contemporary Jat Sikhs. SRM J Res Dent Sci 2013; 4:97-100.

32.Hsu JH, Tsai PL, Hsiao TH, Chang HP, Lin LM, Liu KM, Yu HS, Ferguson D. The effect of

shovel trait on Carabelli's Trait in Taiwan Chinese and Aboriginal Populations. J Forensic Sci 1997;42:802-06.

33.Khraisat A, Taha ST, Jung RE, Hattar S, Smadi L, Al-Omari IK, Jarbawi M. Prevalence, association, and sexual dimorphism of Carabelli's molar and shovel incisor traits amongst Jordanian population. Odontostomatol Trop 2007;30:17-21.

34.Synder RG, Dahlberg AA, Snow CC, Dahlberg T. Trait analysis of the dentition of the Tarahumara Indians and Mestizos of the Sierra Madre Occidental, Mexico. Am J Phys Anthropol 1969;31:65-76.

Corresponding Author

Dr. Magrur Kazak

Bezmialem Vakif University

Dentistry Faculty

Restorative Dentistry Department

Tel : +90 5323325127

E-mail : magrur@hotmail.com



EFFECT OF OZONE PRETREATMENT ON THE MICROLEAKAGE OF CLASS V CAVITIES FOLLOWING OFFICE BLEACHING WITH DIODE LASER

Diyot Lazerle Yapılan Ofis Beyazlatma Tedavisi Sonrası Ozon Uygulamasının Sınıf V Kavitelerde Mikrosızıntı Üzerine Etkisi

Derya SÜRME LİOĞLU¹, Emine Şirin KARAARSLAN²

Eda ERBİL³, Osman DEMİR⁴

Makale Kodu/Article Code : 414896

Makale Gönderilme Tarihi : 12.04.2018

Kabul Tarihi : 26.07.2018

ABSTRACT

Objective: This study investigated the effect of ozone pre-treatment on the microleakage of class V composite restorations after using two different bleaching agents with laser activation.

Methods: Forty non-carious maxillary central incisor teeth extracted for periodontal disease were included and randomly divided into two main groups (n=20). *Group 1:* Bleaching agent including 40% H₂O₂ was activated with laser (Diode 980 nm, Gigaa Dental Laser Cheese, China). *Group 2:* Bleaching agent including 35% H₂O₂ was activated with the same laser. Then, the teeth were randomly divided into two subgroups (n=10). Ten specimens in each subgroup were subjected to ozone treatment (Ozonytron XP-OZ, MIO International, Germany) for 30 s, while the remaining untreated specimens were left as control group. Class V cavities were prepared on the buccal surfaces and restored with composite resin (Filtek Z550, 3M ESPE, USA). Following thermal cycling (5–55°C, 5000×), the specimens were kept in 0.5 % basic fuchsin for dye penetration within a period of 24h. Then, the teeth were sectioned longitudinally. The depth of staining along with the tooth-restoration interface was examine under a stereomicroscope and recorded.

Results: There were no significant differences between the two bleaching agents in terms of microleakage of restorations (p > 0.05). The ozone pre-treatment didn't decrease the microleakage values (p > 0.05). Significantly higher microleakage scores were determined at gingival margins compared to occlusal margins (p < 0.05).

Conclusion: Ozone pre-treatment did not affect microleakage scores of class V composite restorations following dental bleaching.

Keywords: Dental bleaching, diode laser, ozone, microleakage.

ÖZ

Amaç: Bu çalışmada, iki farklı beyazlatma ajanı kullanılarak yapılan lazer aktivasyonlu beyazlatma sonrası ozon uygulamasının, sınıf V kompozit restorasyonların mikrosızıntısı üzerindeki etkisi araştırılmıştır.

Metot: Çalışmada periodontal hastalık nedeniyle çekilen 40 tane çürüksüz maksiller santral diş kullanıldı ve rastgele iki ana gruba ayrıldı (n=20). *Grup 1:* %40 H₂O₂ içeren beyazlatma ajanı lazerle aktive edildi (Diode 980 nm, Gigaa Dental Laser Cheese, China) *Grup 2:* %35 H₂O₂ içeren beyazlatma ajanı aynı lazerle aktive edildi. Daha sonra dişler rastgele iki alt gruba ayrıldı (n=10). Her ana grubun, bir alt grubundaki 10 örnek kontrol grubu olarak ayrılırken, geri kalan 10 örneğe 30 saniye süreyle ozon (Ozonytron XP-OZ, MIO International, Germany) uygulandı. Bukkal yüzeylerde sınıf V kaviteler hazırlandı ve kompozit rezin (Filtek Z550, 3M ESPE, ABD) ile restore edildi. Termal siklattan (5-55 °C, 5000 ×) sonra örnekler, boyanın nüfuz etmesi için 24 saat boyunca %0,5 bazik fuksin içinde bekletildi. Ardından, değerlendirme için dişler vertikal olarak separe edildi. Diş ve restorasyonun arayüzü boyunca oluşan boyanma derinliği stereomikroskop altında incelendi ve kaydedildi.

Bulgular: Restorasyonların mikrosızıntısı açısından iki beyazlatma ajanı arasında anlamlı bir fark bulunamadı (p> 0,05). Ozon tedavisi mikrosızıntı değerlerini azaltmadı (p> 0,05). Okluzal marjinlerde, gingival marjinlere oranla anlamlı düzeyde daha fazla mikrosızıntı tespit edildi (p <0,05).

Sonuç: Beyazlatma sonrası ozon tedavisi sınıf V kompozit restorasyonların mikrosızıntı değerlerini etkilemedi.

Anahtar Kelimeler: Dental beyazlatma, diyet lazer, ozon, mikrosızıntı

¹ Gaziantep University, Dentistry Faculty, Department of Restorative Dentistry, Gaziantep/Turkey

² Gaziosmanpasa University, Dentistry Faculty, Department of Restorative Dentistry, Tokat /Turkey

³ Ege University, Dentistry Faculty, Department of Restorative Dentistry, Gaziantep/Turkey

⁴ Gaziosmanpasa University, Medicine Faculty, Department of Biostatistics, Tokat /Turkey

INTRODUCTION

Office bleaching is a conservative, effective and relatively safe esthetic treatment. In contemporary dental practice, agents containing 30-40 % hydrogen peroxide (H₂O₂) have been widely used for bleaching.¹ Although this chemical can be used for both home and office bleaching, the latter one has many advantages including professional control, avoiding the contact of agents with soft tissues, immediate results and bleaching of all surfaces of teeth.² H₂O₂ is a very unstable molecule and can be easily decomposed which results in the release of different oxygen species (e.g. perhydroxyl anion, hydroxyl radical). The amount of released oxygen radical depends on environmental conditions including pH, light, and temperature.³ For this reason, this agent can be used either alone or can be activated by heat or light in order to increase its efficiency.⁴

H₂O₂ may also alter the structure of both methacrylate-based composite resins and tooth including color, roughness and surface hardness. These changes may lead to decreased bond strength and increased microleakage throughout restorative material and dental hard tissue interface⁵ because these agents reduce polymerization if restoration carried out immediately after tooth bleaching.⁶ It is suggested that a period of time should be allowed between the end of bleaching treatment and placement of adhesive restorations. At least a period of 7 days is required for accomplishment of composite restoration immediately after bleaching.⁷

Today, the use of ozone in restorative dentistry has been used for pit and fissure caries and white spot lesion. Antibacterial property of ozone is due to high oxidation activity inducing the rupture of the cell membranes and destroying of intracellular components.⁸ The improving of equipment to utilize gaseous ozone in the dental practice has

allowed new therapeutic facilities in dental surface pre-treatment.⁹

Microleakage is one of the important factors that lead to the failure of resin restorations. It is defined as the penetration of bacteria, fluids, molecules or ions into the spaces between the cavity walls and the restorative materials.¹⁰ Clinically, microleakage can lead to postoperative sensitivity, staining around the margins of restorations, secondary caries, restoration failure, pulpal pathology or pulpal necrosis, partial or total loss of restoration.¹¹ It is known that there was a negative influence of bleaching on the marginal integrity of existing or new restorations.¹² On the current literature there have been many studies which related to the microleakage of composite resin restorations after tooth bleaching.^{13, 14} But, there is no available study about ozone treatment after bleaching in the literature. In the light of these informations, the aim of this study was to investigate effect of ozone application after office bleaching treatment on microleakage of class V composite resin restorations.

The null hypotheses to be investigated in this study are:

There are no differences between the microleakage values of different bleaching materials.

Ozone application doesn't affect the microleakage results of class V composite resin restorations.

MATERIALS AND METHODS

This study was approved by the ethical committee of Gaziantep University (2017/381). Forty non-carious maxillary central incisor teeth extracted for periodontal disease were included. External root surfaces of the teeth were cleaned with scalers to remove residual organic tissue. Then, the teeth

were randomly divided into two main groups (n=20).

Group 1: Bleaching agent including 40% H₂O₂ (Opalescence Boost, Ultradent Products) was activated with laser (980 nm Diode, Gigaa Dental Laser Cheese, China) for 3 cycles of 20 s with an output power of 4 w localized per teeth. The total bleaching procedure lasted 30 minutes totally.

Group 2: Bleaching agent including 35% H₂O₂ (Whiteness HP Blue, FGM Dental Products, Brazil) activated with laser (980 nm Diode, Gigaa Dental Laser Cheese, China) with the same procedure.

The teeth were further randomly divided into two subgroups (n=10);

Group 1a: Ozone pre-treatment following laser activated bleaching (40 % H₂O₂).

Group 1b: No ozone pre-treatment following laser activated bleaching (40 % H₂O₂).

Group 2a: Ozone pre-treatment following laser activated bleaching (35 % H₂O₂).

Group 2b: No ozone pre-treatment following laser activated bleaching (35 % H₂O₂).

Ozone was applied to external coronal surfaces of the teeth by using an ozone device (Ozonytron XP-OZ, MIO International, Germany) which has a plasma probe for caries treatment or prevention. The device was used with a concentration of 100 ppm for 30 seconds according to the manufacturer's instructions. Then, all specimens were immersed in distilled water and kept for 24 hours. Standardized class V cavities (2 mm depth, 4 mm mesiodistal, 2 mm occlusogingival) were prepared with cylindrical burs attached to aerator on the buccal surfaces in enamel over cement-enamel junction (CEJ) 24 hours later. Each cavity was etched for 30 s on enamel surface with 37% phosphoric acid (K-ETCHANT, Kuraray Noritake Dental Inc), then 40 s water rinsed, and excess water was blotted using an

absorbent paper. This was followed by the application of an adhesive system (3M ESPE Adper Single bond 2, USA) and polymerized with light for 10 s. All cavities were restored with composite resin (Filtek Z550 A2 3M ESPE, USA) in increments of 2 mm and each layer was polymerized for 20 s with a LED (Valo, Cordless, Ultradent, Germany). Apices of teeth were covered by flowable composite (Competence Flow Willmann & Pein GmbH, Germany) to prevent the leakage of dye throughout the foramen. All external surfaces of crowns and roots were covered with two coats of nail varnish up to a distance of 1 mm beyond the margins of the restorations.

All specimens were subjected to thermocycling (SD Mechatronik Thermocycler, SD Mechatronik GMBH, Westerham, Germany) for 5,000 thermal cycles between 5 and 55 °C with a dwelling time of 30 s in each bath and a transferring time of 5 s. Following thermal cycling, teeth were immersed in 0.5% basic fuchsine dye solution for 24h. After this procedure, the teeth were washed and dried. Each tooth was sectioned bucco-lingually along the center of the restorations using with a slow-speed diamond saw (Isomet 1000, Buehler Ltd., Lake Bluff, IL, USA) machine. Microleakage of the restorations was measured under stereomicroscope (Leica M125, Leica, Heerbrugg, Switzerland) with a magnification of x40.

Dye penetrations at the occlusal and gingival margins were assessed by one examiner to determine the extent of microleakage according to a five-point scale as follows.¹⁵

0 = no leakage (figure 1)




Figure 1: Image of section with score 0 staining.

2 = Leakage up to 2/3 of gingival/occlusal walls (figure 3)

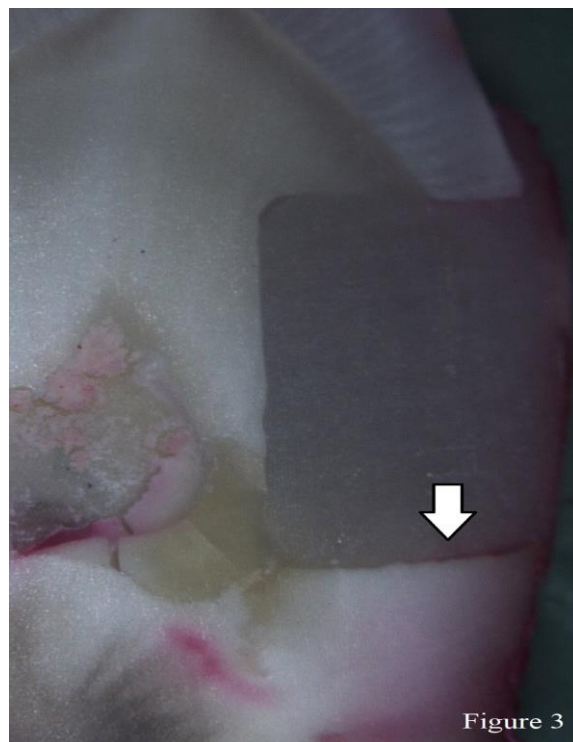


Figure 3: Image of section with score 2 staining

1 = Leakage up to 1/3 of gingival/occlusal walls (figure 2)




Figure 2: Image of section with score 1 staining

3 = Leakage up to base of the cavity (figure 4)

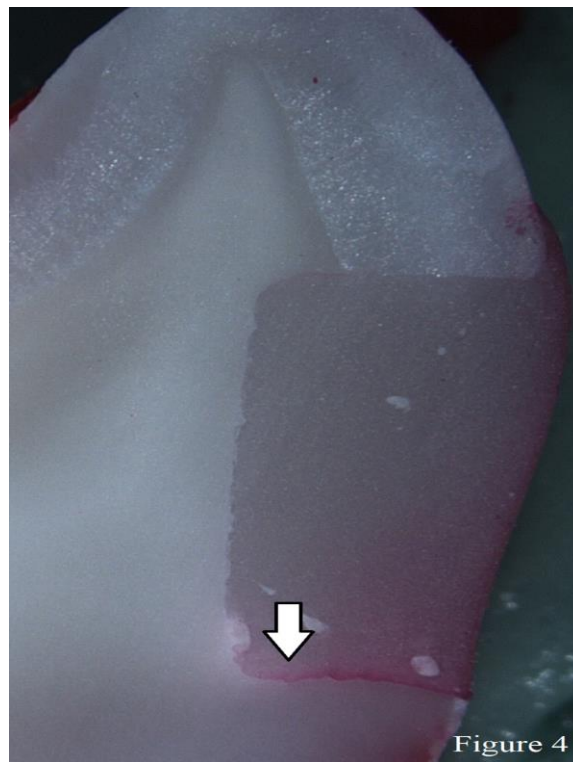


Figure 4: Image of section with score 3 staining

4 = Extensive dye penetration into axial wall (figure 5)




Figure 5: Image of section with score 4 staining

Statistical Analysis

Data was shown as median, interquartile range or frequency and percent. Prior to statistical analysis, the normality of the data was analyzed with Shaphiro Wilk test. Due to non-normal distribution of the data, statistical analysis was performed utilizing the Kruskal Wallis, One-way ANOVA followed by a Mann Whitney U test. Kruskal Wallis or Mann Whitney U test were used to compare the variables between/among groups. A p-value <0.05 was considered as significant. Analyses were performed using SPSS 19 (IBM SPSS Statistics 19, SPSS inc., an IBM Co., and Somers, NY).

RESULTS

The distribution of microleakage scores for groups and subgroups were represented on tables 1 and 2. At both on occlusal and gingival margins, microleakage could not be totally eliminated for all the groups.

Table 1. Distribution of microleakage scores according to the type of bleaching material and the inclusion of ozone on the occlusal and gingival margins of restorations.

Main Groups	Subgroups	Margin of Restoration	Scores					Median [25 - 75]
			0	1	2	3	4	
Opalescence Boost (40 % H ₂ O ₂)	Ozone	Occlusal	7	2	1	0	0	0[0-1] ^a
		Gingival	1	6	2	0	1	1[1-1] ^b
	Ozone-free	Occlusal	9	1	0	0	0	0[0-0] ^a
		Gingival	0	1	5	4	0	2[2-3] ^b
Whitess HP Blue (35 % H ₂ O ₂)	Ozone	Occlusal	8	2	0	0	0	0[0-0] ^a
		Gingival	1	6	1	1	1	1[1-1] ^b
	Ozone-free	Occlusal	7	1	1	1	0	0[0-1] ^a
		Gingival	1	2	3	3	1	2[1-3] ^b

Different superscript letters indicate significant difference among the groups.

Table 2. Distribution of microleakage scores according to the inclusion of ozone on the occlusal and gingival margins of restorations.

Subgroups	Margin of Restoration	Scores					Median [25-75]
		0	1	2	3	4	
Ozone	Occlusal	15	4	1	0	0	0[0-0.5] ^a
	Gingival	4	12	3	1	1	1[1-1] ^b
	Total	18	16	4	1	1	1[0-1] ^x
Ozone-free	Occlusal	16	2	1	1	0	0[0-0] ^a
	Gingival	1	3	8	7	1	2[1.5-3] ^b
	Total	18	5	9	8	1	1[0-2] ^x
Total	Occlusal	31	6	2	1	0	0[0-0] ^a
	Gingival	5	15	11	8	1	1[1-2] ^b

Different superscript letters indicate significant difference among the groups.

Statistical analysis (Kruskal Wallis and Mann Whitney U test) indicated that there were no significant differences between the two bleaching agents in terms of microleakage (p=0.675). Although there were no significant differences, the microleakage values of ozone-treated group were lower than values of ozone-free groups. In other words, the ozone treatment didn't significantly decrease the microleakage values (p=0.142). There were significant differences between the scores of microleakage at the occlusal and gingival margins regardless of the type of agent and ozone pre-treatment (p<0.001). Occlusal margins represented significantly lower

microleakage compared to gingival margins ($p < 0.001$).

DISCUSSION

With the increase of people's aesthetic expectations, the popularity of bleaching has been increasing in recent years. Vital office bleaching agents can be used successfully for discolored vital teeth.¹⁶ But, the effects of bleaching agents on tooth structure should be well known. Because, tooth whitening agents are able to penetrate into the tooth structure through the unsealed dentin margin at the tooth-restoration interface and thus, are capable of causing complications like tooth hypersensitivity and microleakage.¹⁷ This study investigated the effect of ozone application after office bleaching treatment on microleakage of composite resin restorations. The results of the present study stated that microleakage values of composite restorations following the use of different bleaching agents with or without ozone application were not statistically different. Neither the type of bleaching agent nor surface pre-treatment with ozone influenced microleakage values.

Bleaching agents can lead to the separation of polymer chains and break the double bonds because of these are highly unstable materials producing free radicals.¹⁸ The changes of the dental structure by oxidation of organic or inorganic elements is one of the probable side-effects of bleaching agents.¹⁹ Oxygen and oxidants can influence bonding to dental materials. Interactions between residual (per) oxide-related substances and restorative materials interfere with adhesion.²⁰ There have been reports regarding the interaction between bleaching agents and the bond strength of composite materials to enamel have shown that there is a significant decrease in the bond strength or increase in the microleakage when the composite resin is bonded to bleached enamel compared with unbleached enamel.²¹ The aim of laser bleaching treatment is to apply the most

effective energy source as prevention any adverse effect for achieving the latest power bleaching.²² It has been reported that bleaching treatment with laser irradiation improves both the whitening effect and preserve the change of enamel structure compared with bleaching treatment without laser-assisted.²³ Therefore, we aimed to evaluate the effects of laser-supported bleaching in the current study.

Ozone has the ability that lead to remineralization by gaining Ca and P ions through the tooth and remove proteins from carious lesions.²⁴ Dehydration of enamel is a reversible condition caused by ozone.²⁵ For this reason, removal of such residual moisture may notably improve adhesion of composite to the enamel structure. It has been reported that the dehydration resulting from ozone have no effect on the microhardness and surface-free energy of tooth surface, and have not influence on adhesion.²⁵ Cehreli *et al.*²⁶ reported that due to its strong oxidizing effect, ozone might have negative consequences on resin-tooth adhesion, since oxygen is a well-known polymerization inhibitor. Although the antibacterial efficacy of ozone treatment have been investigated in several studies^{27, 28}, there are only a few studies that have specifically evaluated the effects of ozone treatment on the microleakage and bond strength of adhesive systems.^{25, 29} Cehreli *et al.*³⁰ reported that fissure pretreatment with ozone led to a significant decrease in the microleakage values of both the bonded and conventional sealants, compared with their control (ozone-untreated) groups. In the current study, although there were no significant differences, the microleakage values of ozone-treated group were lower than values of ozone-less group. This effect may be due to the relatively high concentration of ozone in the present study.

The complex morphology of class V cavities with margins are partly in enamel as well as in root dentin presents difficulties for the restorative material.³¹ Mahrous *et al.*³² compared

the effect of the location of the gingival margin (enamel, dentin, or cementum) on the microleakage of posterior composite restoration and reported that the least microleakage was observed at the gingival margin located in the enamel while the most microleakage was detected at gingival margins located at cementum. Their results are partially in accordance with our result because our results demonstrated that occlusal (coronal) borders of the restorations represented lower microleakage compared to gingival margins. We assume that this is related with the higher bonding capacity of enamel to adhesive systems compared to dentine and cementum. Manhart *et al.*³³ also reported that marginal quality and sealing ability of adhesive systems to dentin was lower compared with occlusal margins.³³ According to the results of the current study, statistically significant differences were observed in dye penetration when occlusal margin and gingival margin were compared. All gingival margins showed higher microleakage score results compared to occlusal margins. These variations may also be explained by enamel thickness and structural differences. Increased tubule frequency and diameter at gingival margins may have interfered with adhesion of the restorations to dental hard tissues. Furthermore our findings are in accordance with the studies of Bektas *et al.*³⁴ and Moosavi *et al.*³⁵ who evaluated the effect of bleaching on the microleakage of Class V composite resin restorations. They reported that there was more microleakage in dentinal margins of composite restorations than in the occlusal margins in the test groups.

Microleakage should be evaluated to determine the clinical success of restorative materials and it is related to several factors, such as dimensional changes of materials due to polymerization shrinkage, thermal contraction, water absorption, mechanical stress and dimensional changes in tooth structure.³⁶ Different methods have been employed to evaluate microleakage around restorations in vitro such as including dye leakage method, the

use of color producing microorganisms, radioactive isotopes, the air pressure method, neutron activation analysis, electrochemical studies, scanning electron microscopy, thermal and mechanical cycling, and chemical tracers.³⁷ Thermocycling is an important procedure for testing the sealing ability of restorative material. Thermally induced stresses, which may lead to gap formation and microleakage, result from the mismatch between the coefficients of thermal expansion for the restorative material and the natural tooth structure.³⁸ Based on the studies, we used dye penetration method to investigate effects of bleaching treatment on microleakage after 5,000 thermal cycles.

CONCLUSION

Within the limitations of this study, the following conclusions were obtained:

- Applying immediately ozone after laser assisted vital bleaching didn't lead to decrease on microleakage of class V cavities. No significant differences were shown between the microleakage values of ozone-treated groups and ozone-free groups.
- At both occlusal and gingival margins, marginal microleakage was not eliminated completely in all the groups.

ACKNOWLEDGEMENT

The authors of the present study deny any financial support and conflict of interest related to this study.

Source of Funding

None

Conflict of Interest

None

REFERENCES

1. Sari T, Celik G, Usumez A. Temperature rise in pulp and gel during laser-activated bleaching: in vitro. *Lasers Med Sci.* 2015;30(2):577-82.

2. Gurgan S, Cakir FY, Yazici E. Different light-activated in-office bleaching systems: a clinical evaluation. *Lasers Med Sci.* 2010;25(6):817-22.
3. Minoux M, Serfaty R. Vital tooth bleaching: Biologic adverse effects—A review. *Quintessence Int.* 2008;39(8).
4. Joiner A. The bleaching of teeth: a review of the literature. *J Dent.* 2006;34(7):412-9.
5. Anagnostou M, Chelioti G, Chioti S, Kakaboura A. Effect of tooth-bleaching methods on gloss and color of resin composites. *J Dent.* 2010;38 Suppl 2:e129-36.
6. Attin T, Hannig C, Wiegand A, Attin R. Effect of bleaching on restorative materials and restorations—a systematic review. *Dent Mater.* 2004;20(9):852-61.
7. Da Silva Machado J, Cândido MSM, Sundfeld RH, De Alexandre RS, Cardoso JD. The influence of time interval between bleaching and enamel bonding. *J Dent Res.* 2007;19(2):111-8.
8. Muller P, Guggenheim B, Schmidlin PR. Efficacy of gasiform ozone and photodynamic therapy on a multispecies oral biofilm in vitro. *Eur J Oral Sci.* 2007;115(1):77-80.
9. Schmidlin PR, Zimmermann J, Bindl A. Effect of ozone on enamel and dentin bond strength. *J Adhes Dent.* 2005;7(1):29-32.
10. Waldman G, Vaidyanathan T, Vaidyanathan J. Microleakage and resin-to-dentin interface morphology of pre-etching versus self-etching adhesive systems. *Open Dent.* 2008;2:120.
11. Krejci I, Lutz F. Marginal adaptation of Class V restorations using different restorative techniques. *J Dent.* 1991;19(1):24-32.
12. Türkün M, Türkün L. Effect of nonvital bleaching with 10% carbamide peroxide on sealing ability of resin composite restorations. *Int Endod J.* 2004;37(1):52-60.
13. Roubickova A, Dudek M, Comba L, Housova D, Bradna P. Effect of postoperative peroxide bleaching on the marginal seal of composite restorations bonded with self-etch adhesives. *Oper Dent.* 2013;38(6):644-54.
14. White DJ, Duschner H, Pioch T. Effect of bleaching treatments on microleakage of Class I restorations. *J Clin Dent* 2008;19(1):33-6.
15. Davidson C, Abdalla A. Effect of occlusal load cycling on the marginal integrity of adhesive Class V restorations. *Am J Dent.* 1994;7(2):111-4.
16. Haywood VB, Berry TG *Fundamentals of Operative Dentistry 3ed.* Schwarts RS, Summitt JB, Robbins JW editor. Chicago Quintessence; 2006. p. 437.
17. Khoroushi M, Fardashtaki S. Effect of light-activated bleaching on the microleakage of Class V tooth-colored restorations. *Oper dent.* 2009;34(5):565-70.
18. Malkondu O, Yurdagüven H, Say EC, Kazazoglu E, Soyman M. Effect of bleaching on microhardness of esthetic restorative materials. *Oper dent.* 2011;36(2):177-86.
19. McEvoy S. Chemical agents for removing intrinsic stains from vital teeth. II. Current techniques and their clinical application. *Quintessence Int.* 1989;20:379-84.
20. Torneck C, Titley K, Smith D, Adibfar A. Adhesion of light-cured composite resin to bleached and unbleached bovine dentin. *Dent Traumatol.* 1990;6(3):97-103.
21. Turkün M, Kaya AD. Effect of 10% sodium ascorbate on the shear bond strength of composite resin to bleached bovine enamel. *J Oral Rehabil.* 2004;31(12):1184-91.
22. Dostalova T, Jelinkova H, Housova D, Sulc J, Nemeč M, Miyagi M, et al. Diode laser-activated bleaching. *Braz Dent J.* 2004;15 Spec No:SI3-8.
23. Son JH, An JH, Kim BK, Hwang IN, Park YJ, Song HJ. Effect of laser irradiation on

crystalline structure of enamel surface during whitening treatment with hydrogen peroxide. *J dent.* 2012;40(11):941-8.

24.Baysan A, Lynch E. The use of ozone in dentistry and medicine. Part 2. Ozone and root caries. *Prim Dent Care.* 2006;13(1):37-41.

25.Celiberti P, Pazera P, Lussi A. The impact of ozone treatment on enamel physical properties. *Am J Dent.* 2006;19(1):67-72.

26.Cehreli SB, Guzey A, Arhun N, Cetinsahin A, Unver B. The effects of prophylactic ozone pretreatment of enamel on shear bond strength of orthodontic brackets bonded with total or self-etch adhesive systems. *Eur J Dent.* 2010;4(4):367-73.

27.Baysan A, Whiley RA, Lynch E. Antimicrobial effect of a novel ozone-generating device on micro-organisms associated with primary root carious lesions in vitro. *Caries Res.* 2000;34(6):498-501.

28.Baysan A, Lynch E. Effect of ozone on the oral microbiota and clinical severity of primary root caries. *Am J Dent.* 2004;17(1):56-60.

29.Dukić W, Lulić Dukić O, Milardović S. The influence of Healozone on microleakage and fissure penetration of different sealing materials. *Coll Antropol.* 2009;33(1):157-62.

30.Cehreli SB, Yalcinkaya Z, Guven-Polat G, Çehreli ZC. Effect of ozone pretreatment on the microleakage of pit and fissure sealants. *J Clin Pediatr Dent.* 2010;35(2):187-90.

31.Dietrich T, Lösche A, Lösche G, Roulet JF. Marginal adaptation of direct composite and sandwich restorations in Class II cavities with cervical margins in dentin. *J Dent.* 1999;27(2):119-28.

32.Mahrous AI, Eltiti HA, Ahmed IM, Alagha EI. Effect of different gingival margin restorations of class II cavities on microleakage: an in-vitro study. *Electronic physician.* 2015;7(7):1435.

33.Manhart J, Chen HY, Mehl A, Weber K, Hickel R. Marginal quality and microleakage of adhesive class V restorations. *J dent.* 2001;29(2):123-30.

34.Bektas OO, Eren D, Akin GG, Sag BU, Ozcan M. Microleakage effect on class V composite restorations with two adhesive systems using different bleaching methods. *Acta Odontol Scand.* 2013;71(3-4):1000-7.

35.Moosavi H, Moghaddas MJ, Ghoddusi J, Rajabi O. Effects of two antioxidants on the microleakage of resin-based composite restorations after nonvital bleaching. *J Contemp Dent Pract.* 2010;11(6):E033-40.

36.Staninec M, Mochizuki A, Tanizaki K, Jukuda K, Tsuchitani Y. Interfacial space, marginal leakage, and enamel cracks around composite resins. *Oper dent.* 1986;11(1):14.

37.Taylor M, Lynch E. Microleakage. *J dent.* 1992;20(1):3-10.

38.Versluis A, Douglas WH, Sakaguchi RL. Thermal expansion coefficient of dental composites measured with strain gauges. *Dent Mater.* 1996;12(5):290-4.

Corresponding Author

Derya SÜRMEİİOĞLU

Gaziantep University

Dentistry Faculty

27060 Şehitkamil/GAZIANTEP

Tel : +90 342 3609600/4304

Fax : +90 342 36103460

E-mail : h.d.gursel@gmail.com

This study was represented in ORAD congress on 20. 11. 2016



COMPARISON AND EVALUATION OF ALVEOLAR BONE AROUND LOWER CENTRAL INCISORS IN CLASS III AND CLASS I PATIENTS

İskeletsel Sınıf III ve Sınıf I Bireylerin Alt Santral Kesici Dişlerinin Etrafındaki Alveolar Kemik Karşılaştırılması ve Değerlendirilmesi

Ezgi ATİK, Hande GÖRÜCÜ COŞKUNER, Tülin TANER

Makale Kodu/Article Code : 406846

Makale Gönderilme Tarihi : 16.03.2018

Kabul Tarihi : 26.07.2018

ABSTRACT

Objectives: The aim was to evaluate and compare the alveolar bone support of mandibular central incisors in subjects with Class III and Class I skeletal patterns using cone-beam computed tomography (CBCT).

Materials and Methods: Group 1 included 20 patients (mean age=19.78±2.80) with Class III malocclusion (mean ANB°=-2.77±3.69), mesofacial growth pattern (FMA°=27.03 ±5.11) and lingual-inclined mandibular incisors (IMPA°<85). Group 2 included 20 patients (mean age=20.85±3.97) with Class I malocclusion (mean ANB°=2.94 ±1.46), mesofacial growth pattern (FMA°=25.67±6.83) and normal inclined mandibular incisors (85<IMPA°<95). Vertical alveolar bone level and alveolar bone thickness (ABT) of total 80 mandibular central incisors (40 from each group) were evaluated. Buccal, lingual and total ABT were measured at the crestal, midroot, and apical levels. Buccal (BACH) and lingual (LACH) alveolar crestal heights were also evaluated. Mann-Whitney U, independent samples-t-tests, and Pearson correlation analysis were applied for statistical analysis.

Results: The lingual ABT at the crestal and midroot level, buccal ABT at the apical level, and total ABT at all levels were significantly lower in Group 1 than Group 2 (p<0.05). There was a negative correlation between the buccal (r=-0.324; p=0.042) ABT at the apical level and mandibular plane angle. The change in mandibular incisor inclination was positively correlated with buccal ABT at the apical level (r=0.463; p=0.003) and lingual ABT at the crestal level (r=0.550; p<0.001). BACH was significantly higher in Group 1 (2.21±1.48 mm) compared to Group 2 (1.42±0.17 mm) (p < 0.05).

Conclusions: In subjects with Class III deformities, mandibular central incisors have less bone support especially at the buccal side of the alveolar bone at the apical level and lingual side of the alveolar bone at the crestal and midroot levels. Rate of change in mandibular incisor inclination and mandibular plane angle can be thought as significant factors that may influence alveolar bone thickness.

Key Words: Class III, alveolar bone, CBCT evaluation

ÖZ

Amaç: Bu çalışmanın amacı, konik ışınli bilgisayarlı tomografi (KIBT) kullanılarak iskeletsel Sınıf III ve Sınıf I malokluzyonlu bireylerde mandibuler santral keserlerin etrafındaki alveolar kemik desteğini değerlendirmek ve karşılaştırmaktır.

Materyal ve Metod: Grup 1, İskeletsel Sınıf III malokluzyona (ortalama ANB°= -2,77±3,69), mezofasiyal büyüme yönüne (FMA°=27,03 ±5,11) ve linguale eğimli mandibuler keserlere (IMPA°<85) sahip olan 20 hastadan (ortalama yaş=19,78±2,80 yılı) oluşmaktadır. Grup 2, İskeletsel Sınıf I malokluzyona (ortalama ANB°= 2,94 ±1,46), mezofasiyal büyüme yönüne (FMA°=25,67±6,83) ve normal eğimli mandibuler keserlere (85<IMPA°<95) sahip olan 20 hastadan (ortalama yaş=20,85±3,97) oluşmaktadır. Toplam 80 mandibuler santral keser dişin (her bir gruptan 40 diş) görüntüleri kullanılarak vertikal alveolar kemik yüksekliği ve alveolar kemik kalınlığı (AKK) ölçülmüştür. Bukkal, lingual ve total AKK; krestal, kök ortası ve apikal seviyelerde ölçülmüştür. Bukkal (BAKY) ve lingual (LAKY) alveolar krestal yükseklikler de değerlendirilmiştir. İstatistiksel analiz için Mann-Whitney U, bağımsız örneklem-t-testleri ve Pearson korelasyon analizi uygulanmıştır.

Bulgular: Krestal ve orta kök seviyesinde lingual AKK; apikal seviyede bukkal AKK; ve tüm seviyelerde total AKK Grup 1'de Grup 2'ye göre anlamlı şekilde daha az bulunmuştur (p<0,05). Apikal seviyede bukkal AKK (r=-0,324; p=0,042) ve mandibuler düzlem açısı arasında negatif korelasyon bulunmuştur. Mandibuler keser eğimindeki değişim apikal seviyedeki bukkal AKK (r=0,463; p=0,003) ve krestal seviyedeki lingual AKK (r=0,550; p<0,001) ile pozitif korelasyon göstermiştir. BAKY, Grup 1'de (2,21±1,48 mm) Grup 2'ye (1,42±0,17 mm) göre anlamlı şekilde yüksek bulunmuştur (p<0,05).

Sonuçlar: Sınıf III deformitesi olan bireylerde, mandibuler santral keser dişler özellikle apikal seviyede alveolar kemiğin bukkal tarafında ve krestal ve kök orta seviyelerinde ise alveolar kemiğin lingual tarafında daha az kemik desteğine sahiptir. Mandibuler keser eğiminde ve mandibular düzlem açısındaki değişim oranı, alveolar kemik kalınlığını etkileyebilecek önemli faktörler olarak düşünülebilir.

Anahtar Kelimeler: Sınıf III, alveolar kemik, KIBT incelemesi

INTRODUCTION

Adequate alveolar bone support is essential for both efficient tooth movement and stable tooth position. A detailed evaluation of maxillomandibular alveolar bone morphology is crucial in determining orthodontic tooth movement limits and exceeding this limit may cause undesirable iatrogenic side effects in periodontal tissues such as dehiscence and fenestration.¹ It has been emphasized by some authors that the morphology of alveolar bone structure may be related to the inclination of the teeth in the anteroposterior direction.^{2,3} Surgical orthodontic treatment of Class III patients requires orthodontic decompensation including proclining the mandibular incisors to normal axial inclinations. With previous studies,⁴⁻⁶ it was shown that the proclination of the incisors out of the alveolar envelope might be associated with gingival recessions. It has been indicated in a previous study⁷ that the mandibular incisors had greater bone loss than the maxillary incisors in skeletal Class III patients. In Class III patients with thin symphysis structure, severe labial inclination of the incisors may also increase the alveolar bone loss.^{8,9} More careful orthodontic planning is required to ensure that the above-mentioned dental decompensation movements do not cause iatrogenic side effects, since Class III individuals show a thinner alveolar bone structure, especially in the cervical area, compared to individuals with normal occlusion.¹⁰

Traditional radiographic images such as cephalograms, panoramic radiographs, or periapical radiographs are less accurate for the evaluation of bone structure.¹¹ The alveolar bone measurements may be overestimated with the traditional cephalometric radiographs.^{1,12} Considering the high accuracy of cone-beam computed tomography (CBCT) without distortion or superimposition¹³⁻¹⁵, it is the appropriate technique for precise evaluation of alveolar bone dimensions. The vertical height and buccolingual thickness of the alveolar bone

in the anterior region of the mandible can be measured with the aid of the sections obtained from the CBCT images, and topographic location assessment can be performed showing the inclination of lower incisors in different planes.^{16,17}

In the literature, there is a limited number of studies^{10,18,19} evaluating the correlation of buccolingual tooth inclination with alveolar bone thickness in skeletal Class III deformities. Therefore, this study was performed to determine the alveolar bone thickness and height of the mandibular central incisors in subjects with Class III malocclusion and to compare the results with Class I normal occlusion. The null hypothesis was that there was no difference between the two different malocclusion groups.

MATERIALS AND METHODS

This study was a retrospective evaluation of patient records. Pre-treatment CBCT images of 40 non-growing individuals were obtained from the data archive of Hacettepe University, Faculty of Dentistry, and Department of Orthodontics. Ethical approval was obtained from the Hacettepe University Ethical Committee (institutional review board number: GO 16/591-23). CBCT scans were selected according to the following inclusion criteria: (1) CBCT scans taken for diagnostic purposes of multiple impacted teeth or severe facial asymmetry for Class I malocclusion, and pre-surgical evaluation for Class III malocclusion, (2) scans of patients older than 16 years, (3) IMPA degree lower than 85° for skeletal Class III group, and IMPA degree between 85° and 95° for skeletal Class I group. Exclusion criteria were as the following: (1) missing or unerupted mandibular permanent incisors, (2) history of trauma to the lower anterior teeth, (3) crowding more than 3 mm or spacing more than 1 mm in the mandibular anterior alveolar segment, (4) prosthetic crowns on the mandibular incisors, (5) previous orthodontic or surgical treatment.

Three-dimensional CBCT scans were previously taken with i-CAT Cone Beam 3D Imaging System (Imaging Sciences International, Hatfield, Pa) at maximum intercuspation. The scanning settings for the CBCT machine were: 23x17 cm field of view (voxel size, 0.30 mm), 120-kVp tube voltage, tube current of 2 mA, and 17.8 seconds scan time. The CBCT scans were divided into two groups on the basis of both malocclusion classification (Skeletal Class III or I) and IMPA (<math><85^\circ</math> or between ^\circ: ^\circ: ^\circ: ^\circ: ^\circ: ^\circ:

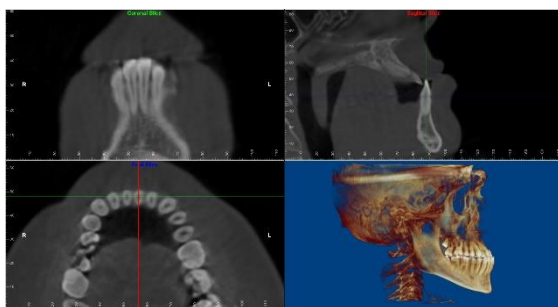


Figure 1. The orientation of all 3 planes of space of CBCT.

Measurements of alveolar bone were performed by importing the DICOM files into Dolphin software (Dolphin Imaging Systems, Chatsworth, Calif). Afterwards 3D

reconstructions were obtained selecting the axial, coronal, and sagittal displays (Figure 2).

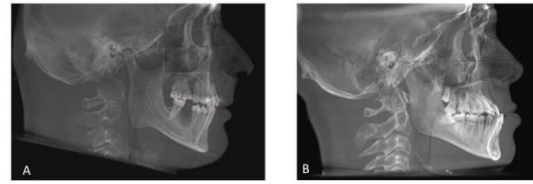


Figure 2. Representative images of two groups classified by different malocclusion and incisor inclination. A, Class I normal group; B, Class III lingual-inclined group.

The axial plane was selected to intersect with the crown of the interested tooth. The coronal and sagittal planes were adjusted to pass through the center of the crown and the root of the interested tooth with the sagittal plane perpendicular to the subject's arch in the axial view. On the sagittal cross section of the mandibular central incisors, buccal and lingual alveolar crestal heights (BACH and LACH) were measured from the most coronal level of the alveolar bone crest to the most apical portion of the cemento-enamel junction (CEJ). Along the axis of the root of each tooth, alveolar bone width measurements were made along the sagittal reference plane at 3, 6, and 8 mm apically to the CEJ. Buccal and lingual bone thicknesses were measured from the most buccal and lingual aspects of the root to the most buccal and lingual aspects of the alveolar bone along the orientation of the sagittal plane (Figure 3).

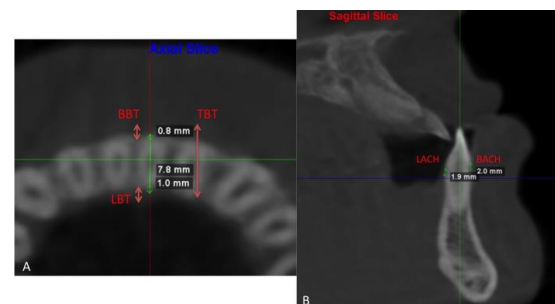


Figure 3. Measurements from CBCT; A, location of alveolar bone thickness measurements; B, vertical alveolar bone level measurement. BBT means buccal bone thickness, LBT means lingual bone thickness, BACH means buccal alveolar crestal height, LACH means lingual alveolar crestal height.

From the constructed lateral cephalograms, the incisor-mandibular plane angle (IMPA), formed by the intersection of the long axis of the mandibular incisor and the gonion-menton line, and mandibular plane angle (FMA) formed

by the intersection of the Frankfurt horizontal plane and mandibular plane were measured. All measurements were made by 2 orthodontists (E.A. and H.G.C.) previously calibrated.

Statistical Analysis

Statistical calculations were performed by using IBM-SPSS for Windows version 21 (SPSS Inc., IL, USA). Shapiro-Wilks test was used to demonstrate whether the parameters were distributed normally or not. Independent samples t-test was used to compare the normally distributed variables, and Mann-Whitney U test was used to compare the variables that were not distributed normally between the groups. The significance level was established at $p < .05$. Pearson correlation analysis was used to analyze the relationship of alveolar bone measurements with IMPA and FMA.

The CBCT measurement error was assessed by calculating the intraclass correlation coefficient (ICC) based on a two-way mixed analysis of variance (ANOVA). 20 CBCT scans (ten from each skeletal pattern group) were measured by two calibrated orthodontists 2 weeks apart to test the reproducibility of the measurements. The ICC values were between 0.847 and 0.990 (Table 1). These values can be considered to be good and excellent.

Table 1. Reliability results of clinical measurements.

	Left tooth			Right Tooth		
	ICC	95% Confidence Interval		ICC	95% Confidence Interval	
		Lower	Upper		Lower	Upper
B-crestal (mm)	0.932	0.838	0.972	0.873	0.711	0.947
B-midroot (mm)	0.864	0.694	0.944	0.942	0.862	0.976
B-apical (mm)	0.957	0.896	0.983	0.951	0.882	0.980
L-crestal (mm)	0.963	0.911	0.985	0.931	0.837	0.972
L-midroot (mm)	0.957	0.897	0.983	0.971	0.930	0.988
L-apical (mm)	0.974	0.936	0.989	0.985	0.062	0.994
T-crestal (mm)	0.948	0.875	0.979	0.973	0.935	0.989
T-midroot (mm)	0.981	0.953	0.992	0.976	0.942	0.990
T-apical (mm)	0.990	0.975	0.996	0.989	0.972	0.995
BACH (mm)	0.982	0.956	0.993	0.989	0.974	0.996
LACH (mm)	0.847	0.658	0.936	0.946	0.871	0.978

ICC: Intraclass correlation coefficient.

RESULTS

Table 2 shows the demographic and clinical variables of the compared groups. The average age of the patients and the FMA angle showed no significant difference between the groups, on the other hand lower incisor inclination degree was significantly lower in Group 1 (mean IMPA°: $78.78 \pm 6.32^\circ$) than Group 2 (mean IMPA°: $91.92 \pm 3.27^\circ$) ($p < 0.05$).

Table 2. Demographic and Clinical Characteristics of the Sample.

Variables	Group 1 (Class III)	Group 2 (Class I)	p-value
Number of subjects	20 (10 female, 10 male)	20 (10 female, 10 male)	
Age (year)	19.78 ±2.80	20.85±3.97	0.565 ^a
ANB (°)	-2.77±3.69	2.94±1.46	<0.001 ^{a*}
IMPA (°)	78.78±6.32	91.92±3.27	<0.001 ^{a*}
FMA (°)	27.03 ±5.11	25.67±6.83	0.480 ^b

a: Mann-Whitney U test, b: Independent samples-t-test.

The results of the alveolar bone measurements of the mandibular central incisors are listed in Table 3. Statistically significant differences of total ABT between the groups were found at crestal, midroot and apical levels ($p < 0.05$). At apical level, buccal ABT value (0.75 ± 0.44 mm) in Group 1 was significantly lower than value in Group 2 (1.28 ± 0.64 mm) ($p = 0.004$). The lingual ABT values around the mandibular central incisors in Group 1 were also lower than in the other group at the crestal and midroot levels, and these differences were significant ($p \leq 0.01$). There was no statistically significant difference in the ABT on the buccal side at the crestal and midroot levels between the groups. Considering the vertical alveolar bone level, BACH measurement was significantly higher in Group 1 (2.21 ± 1.48 mm) than found in Group 2 (1.42 ± 0.17 mm) ($p = 0.010$). Considering the lingual surface, no significant difference was found between the groups in according with LACH ($p = 0.091$).

Table 3. Comparison of alveolar bone measurements between the groups.

Variables	Group 1 (Class III)	Group 2 (Class I)	Mean difference	95% Confidence Interval of the Difference		1-2 (P)
				Lower	Upper	
B-crestal (mm)	0.55±0.29	0.63±0.26	-0.08	-0.26	0.96	0.354 ^b
B-midroot (mm)	0.46±0.26	0.76±0.42	-0.30	-0.52	-0.08	0.072 ^b
B-apical (mm)	0.75±0.44	1.28±0.64	-0.53	-0.88	-0.18	0.004 ^{ab}
L-crestal (mm)	0.70±0.41	1.10±0.30	-0.39	-0.62	-0.16	0.001 ^{ab}
L-midroot (mm)	0.94±0.83	1.27±0.47	-0.33	-0.76	0.10	0.010 ^{ab}
L-apical (mm)	1.26±0.84	1.63±0.61	-0.37	-0.84	0.10	0.122 ^b
T-crestal (mm)	6.50±0.93	7.04±0.47	-0.55	-1.02	-0.08	0.011 ^{ab}
T-midroot (mm)	6.12±0.99	6.91±0.73	-0.79	-1.35	-0.23	0.007 ^{ab}
T-apical (mm)	6.08±1.05	7.05±1.10	-0.97	-1.66	-0.28	0.007 ^{ab}
BACH (mm)	2.21±1.48	1.42±0.17	0.78	0.11	1.46	0.010 ^{ab}
LACH (mm)	2.57±2.64	1.51±0.26	1.05	-0.15	2.25	0.091 ^a

a: Mann-Whitney U test, b: Independent samples-t-test, comparison of alveolar bone measurements between the groups, the significance level was $p < 0.05$. *Statistically significant. 1-2, Group 1 and Group 2 comparison. B:Buccal, L:Lingual, T:Total.

Table 4 shows the Pearson correlation between each one of the variables of alveolar bone measurement and IMPA/FMA degrees for all teeth (n=80) studied.

Table 4. Correlation between cephalometric and alveolar bone measurements.

Variables	N	IMPA (°)	FMA (°)
		R (P)	R (P)
B-crestal (mm)	40	0.190 (0.239)	0.009 (0.955)
B-apical (mm)	40	0.463 (0.003)*	-0.324 (0.042)*
L-crestal (mm)	40	0.550 (0.000)*	-0.131 (0.419)
L-apical (mm)	40	0.395 (0.012)*	-0.170 (0.295)
BACH (mm)	40	-0.266 (0.098)	0.122 (0.454)
LACH (mm)	40	-0.155 (0.339)	0.017 (0.916)

Pearson correlation coefficient analysis. Values are presented as R (p) value.

There were no correlations between buccal crestal ABT and IMPA and/or FMA angles. BACH and LACH measurements were not statistically correlated with IMPA or FMA angles ($p > 0.05$). Changes in IMPA angle were positively and moderately correlated with changes in buccal ABT at apical ($r = 0.463$; $p = 0.003$) and lingual ABT at crestal levels ($r = 0.550$; $p < 0.001$) indicating that as the incisor tipped labially, the cortical bone on the lingual aspect at the crestal level and the cortical bone on the buccal aspect at the apical level became thicker. A negative correlation existed between changes in FMA angle and changes in buccal ($r = -0.324$; $p = 0.042$) ABT at the apical level. Lingual crestal and lingual apical ABT measurements were not correlated with changes in FMA angle.

DISCUSSION

The structure of the mandibular symphysis can limit the movement of the incisors since the alveolar bone thickness of the lower anterior teeth is thin and more susceptible to periodontal disease.^{2,20} The determination of the structure of the mandibular symphysis especially in skeletal Class III patients who need orthognathic surgery is important, as the lower incisors are mostly inclined lingually as a result of dental compensation and need to move forward during the presurgical orthodontic treatment. It is known that as the mandibular incisors are proclined, it is more likely to see alveolar bone fenestration or recession of the gingiva.²¹ With the advance of 3-dimensional CBCT images, it is possible to examine alveolar bone morphology with quality without distortion or overlap, and also to measure the alveolar bone thickness around the roots.²²⁻²⁵ Therefore, this study focused on the alveolar bone amount around the lower central incisors in Skeletal Class III patients who had lingually inclined lower incisors, and compare the values with normally inclined lower incisors in Class I patients. Many cephalometric goals for the position of mandibular incisors have been advocated. In this study, we divided the initial CBCT scans of the patients on the basis of IMPA according to Tweed classification besides malocclusion classification (Class III or Class I). Tweed stated that the mandibular incisors should create an angle between 85° and 95° with the mandibular plane if the mandible plane to the Frankfurt plane angle falls in the 22° to 29° range.²⁶ IMPA for the scans selected for Group 1 were lower than 85° indicating lingual-inclined group, and for Group 2 were between 85° and 95° indicating the normal-inclined group.

In the present study, buccal and lingual alveolar bone thicknesses were evaluated at 3 distances which were respectively 3, 6, and 8 mm from the CEJ to represent respectively the cervical, midroot, and apical levels of the tooth.

Buccal ABT showed significantly lower values at only apical level on the other hand lingual ABT showed lower values at both crestal and midroot levels in Class III group compared to Class I group. This difference between the groups can be related to the significant lower IMPA value in Class III group, indicating lingual-inclined incisors, which makes the apex closer to the labial cortex. Yamada *et al.*² also reported that the central incisor root apex was closer to the internal labial cortical bone than the lingual cortical bone in adults with mandibular prognathism. Similar to our results, Kook *et al.*¹⁸ found that alveolar bone thickness at the tooth apex was significantly lower in Class III patients than in normal occlusion sample. Sendyk *et al.*¹⁰ compared the alveolar bone thickness in patients with Class III malocclusion from those with normal occlusion with CBCT. The results of the study showed that the average buccal and lingual alveolar thickness at 3mm (cervical portion) and 8 mm (apical region) from the CEJ were significantly lower in Class III group.

In the study of Tian *et al.*²⁷, the relationship between labiolingual inclination and the thickness of the alveolar bone in mandibular central incisors was investigated using CBCT, and the total and lingual alveolar bones were thinner in lingual inclination group than in labial inclination group. Similar to the findings of Tian *et al.*²⁷, the total bone thicknesses at all levels were significantly thinner in Group 1 (Class III, lingual-inclined incisors) compared to group 2 (Class I, normal-inclined incisors). Thin symphysis in Class III malocclusion presents a challenge during pre-surgical orthodontic treatment when labial proclination of the mandibular incisors is planned; so special attention should be paid by the orthodontists not to cause a risk of periodontal problem. The results of the study of Sarikaya *et al.*²⁸ indicated a significant decrease in the thickness of lingual bone plate especially in the coronal and middle third of the root after the retraction of mandibular incisors. In the present study, the

lingual crestal and midroot alveolar bone thicknesses were significantly lower in Class III patients when compared to Class I patients. Because of the risk of adverse effects after incisor retraction especially in the lingual alveolar region, it would be better to maintain the initial, and therefore natural incisor position of the mandibular incisors in Class III camouflage treatments instead of retracting the teeth.

The distance between the alveolar crest and the cemento-enamel junction represents the extent of vertical alveolar bone loss. Besides, bone dehiscences can be described as an increase of the distance between the CEJ and the buccal or lingual alveolar bone crest.²⁹ CEJ-to-alveolar bone crest of 2 mm or less is considered normal with the studies.^{30,31} With the experimental studies,^{32,33} it was shown that mandibular incisor proclination could cause marginal bone loss. In the present study, considering the vertical alveolar bone level, BACH measurement was significantly higher in Group 1 (2.21 ± 1.48 mm) than found in Group 2 (1.42 ± 0.17 mm). Kook *et al.*¹⁸ also indicated that Class III patients exhibited more vertical bone loss especially at the lingual alveolar plate than Class I patients. However in the present study, we found a significant difference related to vertical bone level especially at the buccal side.

We also intended to confirm whether dental inclination change effects the buccal and lingual ABT. According to the results of the present study, there was a relationship between the buccal ABT at apical and lingual ABT at crestal levels and lower incisor inclination. This result indicated that as the incisor tipped labially, the cortical bone on the lingual aspect at the crestal level and the cortical bone on the buccal aspect at the apical level became thicker. Yamada *et al.*² and Yu *et al.*³ similarly suggested that the morphology of the alveolar bone was affected by tooth inclination. Yu *et al.*³ concluded that the lower central incisor root

apex was closer to the lingual alveolar crest when it was buccally inclined. Similarly, Yamada *et al.*² found significant positive correlations between the labio-lingual inclination of the mandibular central incisors and the associated cancellous bone thickness. In related to their results, when the mandibular central incisor was more lingually inclined, the associated alveolar bone was more thinner. However Sendyk *et al.*¹⁰ indicated in a recent study that in subjects with Class III deformities, there were weak and few significant correlations between inclination of mandibular central incisor and lingual alveolar thickness of central incisor at 6 mm, and emphasized the natural process of development to provide the stability to the thickness of the alveolar bone. Inconsistent with our finding, Lee *et al.*¹⁹ found no significant correlation of the degree of incisor inclination with the extent of alveolar bone change. Because of the controversial results of the aforementioned studies^{2,3,10,19}, it may not be correct to establish a direct mathematical relationship between the degree of tooth inclination and the change in alveolar bone thickness.

It has been indicated that the growth facial pattern has an effect on the morphology of buccal and lingual alveolar bone plates.^{34,35} Also it has been stated that hyperdivergent patients present a thinner mandibular symphysis and alveolar ridge in the anterior region of the mandibula, when compared to other facial patterns.^{1,36} In the present study two groups did not differ from each other with regards to growth pattern. However, the correlation of FMA with the alveolar bone measurements revealed a negative correlation between changes in FMA and changes in buccal ABT at the apical level. This result meant that when the FMA degree increased, bone thickness at apical level decreased. Under this perspective, it can be thought that, in patients who demonstrate hypodivergent pattern with Class III malocclusion, the orthodontic treatment planning may present less restriction for labio-

lingual incisor movement mainly at the level of root apex.

Comparing the results of the 2 groups, Class III and Class I malocclusion, it has been shown that subjects with Class III malocclusion have thinner alveolar bone at the cervical, midroot and apical levels in different regions (buccal or lingual) than do those with normal occlusion. Using the Class I malocclusion samples in Group 2 gave us some information about the tissue amount around the roots of lower incisors and also the opportunity to compare with the Class III samples' bone values. Considering the results, orthodontists should be careful when planning the labio-lingual movements of the lower incisors, both in camouflage and surgical Class III patients in order to prevent dehiscence and fenestration in the alveolar bone. From the clinical perspective, alveolar bone measurement before beginning treatment with the help of CBCT evaluation can help the orthodontist to move the lower incisors within the alveolar bone housing to minimize the risk of alveolar bone loss during presurgical or camouflage orthodontic treatment.

The CBCT images used in the present study had a voxel size of 0.3 mm. As very small dimensions are studied to detect bone thickness and height, it may be impossible to accurately detect the changes less than 0.3mm of thickness with a voxel size of 0.3 mm.³⁷ In a recent study³⁸ the influence of voxel dimension on measurement accuracy and reproducibility was evaluated, and CBCT images demonstrated good accuracy for measuring the mandibular anterior teeth with 0.2 mm and 0.3 mm voxel sizes. In the present study to reduce the measurement error, half of the variables were repeatedly measured and correlation coefficients were at good and excellent. It would be better to carry out further studies including larger sample to enhance the statistical power and to rule out the possible type II errors.

CONCLUSIONS

1. In subjects with Class III malocclusion, mandibular incisors were more lingually inclined compared to the Class I group.
2. Thinner alveolar bone was observed on the buccal aspect at apical level, and on the lingual aspect at the crestal and midroot level of the central incisors in Class III group.
3. Total average alveolar bone thickness at all levels were statistically less in Class III subjects compared with subjects with Class I malocclusion.
4. Buccal alveolar crestal height was significantly higher in Class III group compared to Class I.
5. Significant correlations were found between mandibular incisor inclination and labial ABT at the apical level and palatal ABT at the crestal level.
6. A weak negative correlation existed between changes in FMA angle and changes in buccal ABT at the apical level.

REFERENCES

1. Handelman CS. The anterior alveolus: its importance in limiting orthodontic treatment and its influence on the occurrence of iatrogenic sequelae. *Angle Orthod* 1996;66:95-109; discussion 109-110.
2. Yamada C, Kitai N, Kakimoto N, Murakami S, Furukawa S, Takada K. Spatial relationships between the mandibular central incisor and associated alveolar bone in adults with mandibular prognathism. *Angle Orthod* 2007;77:766-772.
3. Yu Q, Pan XG, Ji GP, Shen G. The association between lower incisal inclination and morphology of the supporting alveolar bone--a cone-beam CT study. *Int J Oral Sci* 2009;1:217-223.
4. Joss-Vassalli I, Grebenstein C, Topouzelis N, Sculean A, Katsaros C. Orthodontic therapy and gingival recession: a systematic review. *Orthod Craniofac Res* 2010;13:127-141.
5. Djeu G, Hayes C, Zawaideh S. Correlation between mandibular central incisor proclination and gingival recession during fixed appliance therapy. *Angle Orthod* 2002;72:238-245.
6. Yared KF, Zenobio EG, Pacheco W. Periodontal status of mandibular central incisors after orthodontic proclination in adults. *Am J Orthod Dentofacial Orthop* 2006;130:6 e1-8.
7. Kim Y, Park JU, Kook YA. Alveolar bone loss around incisors in surgical skeletal Class III patients. *Angle Orthod* 2009;79:676-682.
8. Melsen B, Allais D. Factors of importance for the development of dehiscences during labial movement of mandibular incisors: a retrospective study of adult orthodontic patients. *Am J Orthod Dentofacial Orthop* 2005;127:552-561; quiz 625.
9. Wainwright WM. Faciolingual tooth movement: its influence on the root and cortical plate. *Am J Orthod* 1973;64:278-302.
10. Sendyk M, de Paiva JB, Abrao J, Rino Neto J. Correlation between buccolingual tooth inclination and alveolar bone thickness in subjects with Class III dentofacial deformities. *Am J Orthod Dentofacial Orthop* 2017;152:66-79.
11. Lupi JE, Handelman CS, Sadowsky C. Prevalence and severity of apical root resorption and alveolar bone loss in orthodontically treated adults. *Am J Orthod Dentofacial Orthop* 1996;109:28-37.
12. Ten Hoeve A, Mulie RM. The effect of antero-postero incisor repositioning on the palatal cortex as studied with laminagraphy. *J Clin Orthod* 1976;10:804-822.
13. Leuzinger M, Dudic A, Giannopoulou C, Kiliaridis S. Root-contact evaluation by panoramic radiography and cone-beam computed tomography of super-high resolution. *Am J Orthod Dentofacial Orthop* 2010;137:389-392.

- 14.**Zamora N, Llamas JM, Cibrian R, Gandia JL, Paredes V. Cephalometric measurements from 3D reconstructed images compared with conventional 2D images. *Angle Orthod* 2011;81:856-864.
- 15.**Ganguly R, Ruprecht A, Vincent S, Hellstein J, Timmons S, Qian F. Accuracy of linear measurement in the Galileos cone beam computed tomography under simulated clinical conditions. *Dentomaxillofac Radiol* 2011;40:299-305.
- 16.**Gahleitner A, Watzek G, Imhof H. Dental CT: imaging technique, anatomy, and pathologic conditions of the jaws. *Eur Radiol* 2003;13:366-376.
- 17.**Gahleitner A, Podesser B, Schick S, Watzek G, Imhof H. Dental CT and orthodontic implants: imaging technique and assessment of available bone volume in the hard palate. *Eur J Radiol* 2004;51:257-262.
- 18.**Kook YA, Kim G, Kim Y. Comparison of alveolar bone loss around incisors in normal occlusion samples and surgical skeletal class III patients. *Angle Orthod* 2012;82:645-652.
- 19.**Lee KM, Kim YI, Park SB, Son WS. Alveolar bone loss around lower incisors during surgical orthodontic treatment in mandibular prognathism. *Angle Orthod* 2012;82:637-644.
- 20.**Holmes PB, Wolf BJ, Zhou J. A CBCT atlas of buccal cortical bone thickness in interradicular spaces. *Angle Orthod* 2015;85:911-919.
- 21.**Proffit W. Limitations, controversies and special problems. St Louis Mo: Mosby; 2007.
- 22.**Hu KS, Kang MK, Kim TW, Kim KH, Kim HJ. Relationships between dental roots and surrounding tissues for orthodontic miniscrew installation. *Angle Orthod* 2009;79:37-45.
- 23.**Lee KJ, Joo E, Kim KD, Lee JS, Park YC, Yu HS. Computed tomographic analysis of tooth-bearing alveolar bone for orthodontic miniscrew placement. *Am J Orthod Dentofacial Orthop* 2009;135:486-494.
- 24.**Park J, Cho HJ. Three-dimensional evaluation of interradicular spaces and cortical bone thickness for the placement and initial stability of microimplants in adults. *Am J Orthod Dentofacial Orthop* 2009;136:314 e311-312; discussion 314-315.
- 25.**Timock AM, Cook V, McDonald T, Leo MC, Crowe J, Benninger BL et al. Accuracy and reliability of buccal bone height and thickness measurements from cone-beam computed tomography imaging. *Am J Orthod Dentofacial Orthop* 2011;140:734-744.
- 26.**Tweed C. Frankfort-mandibular incisor angle in orthodontic diagnosis, treatment planning and prognosis. *Angle Orthod* 1954;24:121-169.
- 27.**Tian YL, Zhao ZJ, Han K, Lv P, Cao YM, Sun HJ et al. [The relationship between labial-lingual inclination and the thickness of the alveolar bone in the mandibular central incisors assessed with cone-beam computed tomography]. *Shanghai Kou Qiang Yi Xue* 2015;24:210-214.
- 28.**Sarikaya S, Haydar B, Ciger S, Ariyurek M. Changes in alveolar bone thickness due to retraction of anterior teeth. *Am J Orthod Dentofacial Orthop* 2002;122:15-26.
- 29.**Garib DG, Yatabe, M.S., Ozawa, T.O., da Silva Filho, O.M. Alveolar bone morphology under the perspective of the computed tomography: Defining the biological limits of tooth movement. *Dental Press J Orthod* 2010;15:192-205.
- 30.**Newman MG, Takei, H.H., Klokkevoid, P.R., Carranza, F.A. Carranza's Clinical Periodontology. St Louis: Mo:Elseiver; 2006.
- 31.**Kallestal C, Matsson L. Criteria for assessment of interproximal bone loss on bite-wing radiographs in adolescents. *J Clin Periodontol* 1989;16:300-304.
- 32.**Steiner GG, Pearson JK, Ainamo J. Changes of the marginal periodontium as a result of

labial tooth movement in monkeys. *J Periodontol* 1981;52:314-320.

33.Batenhorst KF, Bowers GM, Williams JE, Jr. Tissue changes resulting from facial tipping and extrusion of incisors in monkeys. *J Periodontol* 1974;45:660-668.

34.Gracco A, Lombardo L, Mancuso G, Gravina V, Siciliani G. Upper incisor position and bony support in untreated patients as seen on CBCT. *Angle Orthod* 2009;79:692-702.

35.Tsunori M, Mashita M, Kasai K. Relationship between facial types and tooth and bone characteristics of the mandible obtained by CT scanning. *Angle Orthod* 1998;68:557-562.

36.Beckmann SH, Kuitert RB, Prah-Andersen B, Segner D, The RP, Tuinzing DB. Alveolar and skeletal dimensions associated with overbite. *Am J Orthod Dentofacial Orthop* 1998;113:443-452.

37.Sun Z, Smith T, Kortam S, Kim DG, Tee BC, Fields H. Effect of bone thickness on

alveolar bone-height measurements from cone-beam computed tomography images. *Am J Orthod Dentofacial Orthop* 2011;139:e117-127.

38.Menezes CC, Janson G, da Silveira Massaro C, Cambiagli L, Garib DG. Precision, reproducibility, and accuracy of bone crest level measurements of CBCT cross sections using different resolutions. *Angle Orthod* 2016;86:535-542.

Corresponding Author

Ezgi Atik, Assistant Professor,

Department of Orthodontics,

Faculty of Dentistry,

Hacettepe University,

Sihhiye, 06100, Ankara, TURKEY

Tel : +90 312 3052290

Fax : +90 312 3091138,

E-mail : ezgibaytorun@hotmail.com



FORTIFICATION OF FRACTURED INSTRUMENT REMOVAL SIMULATED ROOTS USING SEVERAL CALCIUM SILICATE-BASED MATERIALS

Kırık Enstrüman Çıkarılma Simülasyonu Yapılmış Köklerin Farklı Kalsiyum Silikat İçerikli Materyaller Kullanılarak Güçlendirilmesi

Tuğrul ASLAN¹, Yakup ÜSTÜN¹, Firdevs ÇINAR²,

Salih DÜZGÜN³, İbrahim ŞENER¹

Makale Kodu/Article Code : 391219

Makale Gönderilme Tarihi : 06.02.2018

Kabul Tarihi : 25.04.2018

ABSTRACT

Objectives: The aim of this study was to evaluate the forces required to fracture roots obturated with different calcium silicate – based materials, after applying a fractured instrument removal simulation.

Material and Methods: Seventy-five mandibular premolars were selected and decoronated. Then, all root canals were instrumented using Reciproc system. To mimic the root canal anatomy after the removal of a fractured instrument, each canal was enlarged with a size-3 Peeso reamer. The specimens were distributed into experimental groups according to the materials used for the root fortification: **G1:** Negative control, **G2:** ProRoot MTA, **G3:** Ortho MTA, **G4:** Biodentine, **G5:** Endocem MTA. Then, the teeth were embedded into acrylic blocks. A vertical fracture test was applied, and the fracture loads were recorded. Statistical interpretations were made ($\alpha=0.05$).

Results: G2, G3, G4, and G5 showed greater fracture resistances than G1 ($p<0.05$). There was no significant difference among G2, G3, G4, and G5 ($p>0.05$).

Conclusions: Any of the tested materials could be chosen to reinforce the root after the removal of a fractured instrument.

Keywords: Biodentine, Endocem MTA, Ortho MTA, ProRoot MTA, Root reinforcing, Separated instrument removal.

ÖZ

Amaç: Bu çalışmanın amacı, kırık enstrüman çıkarılması simülasyonu uygulanmasından sonra farklı kalsiyum silikat içerikli materyallerle doldurulmuş kökleri kırmak için gereken kuvvetlerin değerlendirilmesi idi.

Gereç ve Yöntem: 75 adet mandibular premolar diş seçildi ve dekorone edildi. Daha sonra, tüm kök kanalları Reciproc sistemi kullanılarak enstrüman edildi. Kırık enstrüman çıkarılmasının ardından meydana gelen kök kanal anatomisini taklit etmek için her bir kanal 3-numara Peeso frezi ile genişletildi. Örnekler kök güçlendirme işlemi için kullanılan materyallere göre deneysel gruplara dağıtıldı: **G1:** Negatif kontrol, **G2:** ProRoot MTA, **G3:** Ortho MTA, **G4:** Biodentine, **G5:** Endocem MTA. Daha sonra, dişler akrilik bloklara gömüldü. Vertikal kırılma testi uygulandı ve kırılma yükleri kaydedildi. İstatistiksel değerlendirmeler yapıldı ($\alpha=0,05$).

Bulgular: G2, G3, G4 ve G5, G1'den daha yüksek kırılma dirençleri gösterdi ($p<0,05$). G2, G3, G4 ve G5 arasında istatistiksel olarak anlamlı farklılık yoktu ($p>0,05$).

Sonuç: Test edilen tüm materyaller, kırık enstrüman çıkarılmasının ardından kök güçlendirilmesi için seçenek olabilirler.

Anahtar Kelimeler: Biodentine, Endocem MTA, Ortho MTA, ProRoot MTA, Kök güçlendirilmesi, Kırılma enstrüman çıkarılması.

¹ Department of Endodontics, Faculty of Dentistry, Erciyes University, Kayseri, Turkey.

² Specialist Endodontist, UzmanDent Dental Hospital, Kayseri, Turkey.

³ Specialist Endodontist, Fatma Kemal Timuçin Oral and Dental Health Hospital, Adana, Turkey.

INTRODUCTION

The fracturing of endodontic instruments within the root canal system is an unfortunate incident that can jeopardize the outcome of the therapy.¹ One example is the separation of endodontic files during endodontic treatment, with the exact cause still being a topic of debate.² The prevalence of separated instruments has been reported to range from 0.5%–5% by several researchers.³⁻⁵ It can lead to treatment failure and may cause anxiety in the patient.⁶ Therefore, the removal of the separated instrument is the most appropriate treatment choice, and is usually recommended when tooth survival has a crucial impact on the postdental procedures.¹

In general, dentists must create a staging platform in the root canal for better visualization and straight line access to the separated instrument. This process can result in a reduction in the root strength because of the extra removal of the tooth structure and may lead to a vertical root fracture (VRF).⁷ Gerek *et al.*⁸ examined the force required to lead a VRF after the removal of separated endodontic instruments and reported that the primary factor for the diminish of root strengths could be related to the staging platform arranging. For this reason, root fortification has become a necessity in such cases.

To replace the missing dentin from a separated instrument removal, alternative filling materials can be used to fortify the root structure. Mineral trioxide aggregate (MTA) is a calcium silicate-based material (CSM) that is commonly used as a repair material in clinics due to its regenerative capabilities, superior seal, and biocompatibility.⁹ However, MTA does have some disadvantages, such as its high price, difficult manipulation attributes, prolonged hardening time, and discoloration potential.⁹

ProRoot MTA (Dentsply, Tulsa Dental, Tulsa, OK, USA) is one of the most widely preferred CSMs for vital endodontic therapies, root perforation repairs, root-end fillings, and apical barriers in immature apices. It consists

mainly of tricalcium aluminate, tricalcium oxide, tricalcium silicate, and other oxides that can set in the existence of water.¹⁰ Ortho MTA (BioMTA, Seoul, Republic of Korea) was developed mainly for orthograde root canal obturation, as well as retrograde fillings and perforation repairs.¹¹ It consists of tricalcium aluminate, dicalcium silicate, tricalcium silicate, gypsum, tetracalcium aluminoferrite, bismuth oxide, and free calcium oxide. It also has bioactive characteristics, causing the apical foramen to release calcium ions, which leads to the formation of an interfacial hydroxyapatite layer.¹¹ Endocem MTA (Maruchi Co. Ltd., Wonju, Korea) is an MTA-derived pozzolan cement with a chemical composition similar to that of MTA. It consists of aluminum oxide, calcium oxide, silicate oxide, magnesium oxide, and bismuth trioxide¹², has a clinically faster working time than the other CSMs and has shown good clinical results in vital pulp therapy.¹⁰ Biodentine (Septodont, Saint-Maur-des-Fosses, France) is another CSM that was introduced to the market to improve MTA's drawbacks. Biodentine powder consists of calcium carbonate, dicalcium silicate, and zirconium oxide as a radiopacifier, in addition to MTA powder.¹³

Within our knowledge, no previous studies have been done before about the effects of CSMs stored in simulated body fluid (SBF) on the fracture resistance of roots that were treated to simulate having apically fractured instruments removed. Hence, the purpose of this study was to detect which repair materials were effective in reinforcing the root after removing the broken instrument from the apical part of the root canal. The null hypothesis was established as there was no significant difference among the tested materials in the means of the fracture resistances.

MATERIALS AND METHODS

After approval of the local ethics committee (Decision number: 2017/450), seventy-five human maxillary incisor teeth with single and

straight roots were selected and stored in saline solution until use. To determine the single and straight canal morphologies, buccolingual and mesiodistal radiographs of the specimens were taken. The teeth were inspected under an operating microscope (OPMI pico; Zeiss, Germany) to verify that they had no cracks, resorption, or caries.

The specimens were decoronated with slow speed diamond discs (IsoMet; Buehler, Lake Bluff, IL, USA) under water cooling to obtain a standard root length of 13 mm. The pulp tissue remnants were cleaned ultrasonically, and the patencies of root canals were controlled with 10 K-file (Dentsply Maillefer, Ballaigues, Switzerland). The working length was determined 1 mm short of the apex and corresponded to 12 mm. The root canal preparations were performed with a Reciproc instrument (VDW, Munich, Germany) (up to size R40) in "Reciproc all mode" using a VDW Silver endodontic motor. After each instrument change, the root canals were irrigated with 2 mL of 2.5% NaOCl solution using 30-gauge needle. Each canal was enlarged with a size-3 Peeso reamer drill (RelyX, 3M ESPE) up to 3 mm of the apical root canal. In that way, radicular access to the separated fragment's coronal end was simulated. For the final irrigation, 10 mL of 5% NaOCl and 3 mL of distilled water were used for each canal. The root canals were dried with absorbent paper points and the apical parts of the root canals were filled with gutta-percha and AH Plus root canal sealer (Dentsply Maillefer, Ballaigues, Switzerland). The access cavities were sealed with temporary filling material (Cavit G, 3M ESPE, Seefeld, Germany). Then, the teeth were kept at 37°C in 100% humidity for 7 days for complete setting of the root canal sealer.

To simulate the periodontal ligaments, a polyether impression material (Impregum F; 3M ESPE, St. Paul, MN, USA) was used to coat the surface up to 7 mm from the apex of the root. The teeth were then embedded in plastic tubes filled

with self-curing acrylic resin (Imicryl, Konya, Turkey) up to 7 mm from the apex. Next, the temporary filling materials were removed, and the specimens were randomly divided into 5 groups (n=15). The created spaces were filled with one (or none) of four materials as follows:

Group 1: The coronal part of the root canal was left empty (negative control).

Group 2: ProRoot MTA was prepared according to the manufacturer's recommendations (in a 3:1 powder/liquid ratio). When placing the ProRoot MTA, an MTA carrier was used and the material was gently condensed with a hand plugger (No: 3/4 Machtou plugger; Dentsply Maillefer).

Group 3: Ortho MTA was prepared according to the manufacturer's recommendations and placed into the root canal with its special syringe.

Group 4: Biodentine capsules were mixed for 30 seconds in an amalgam mixer according to the manufacturer's recommendations and placed into the root canal. When placing the Biodentine, an MTA carrier was used and the material was gently condensed with a hand plugger (No: 3/4 Machtou plugger; Dentsply Maillefer).

Group 5: Endocem MTA was prepared according to the manufacturer's recommendations (in a 2:1 powder/liquid ratio) and placed into the root canal.

The acrylic resin blocks with the obturated roots were kept in 100% humidity in SBF solution for 5 weeks to completely set the filling materials. The root canal orifices were not sealed with the temporary filling material. The ion concentrations of the SBF used in this study are shown in Table 1. After setting, each acrylic mold was placed in a universal testing machine (Instron Corp., Canton, MA, USA) holding a 3-mm diameter round tip, which was placed in contact with the surface of the obturated root canal. The testing machine was moved vertically, with a crosshead speed of 1 mm/min,

until a fracture occurred. The loads that lead to fracture was then recorded.

Table 1. Ion concentrations of the simulated body fluid used in this study and human blood plasma.

	Ion concentrations (mM)							
	Na ⁺	K ⁺	Mg ²⁺	Ca ²⁺	Cl ⁻	HCO ₃ ⁻	HPO ₄ ²⁻	SO ₄ ²⁻
Human blood plasma	142.0	5.0	1.50	2.50	103.0	27.0	1.0	0.5
Simulated body fluid (SBF)	142.0	5.0	1.50	2.50	103.0	27.0	1.0	0.5

All of the statistical analyses were performed using SPSS 20.0 (IBM Corporation Software Group, Armonk, NY, USA). The Shapiro-Wilk's test showed that the data were distributed normally; thus, a one-way ANOVA test was applied to the data. Because the Levene's variance homogeneity test failed, Tamhane's T2 test was used for the post-hoc analyses ($\alpha=0.05$).

RESULTS

According to the statistical comparisons. Groups 2, 3, 4, and 5 showed significantly greater fracture resistances than Group 1 (negative control) ($p < 0.05$); however, there was no significant difference among these groups ($p > 0.05$). The descriptive statistics of each group are provided in Table 2 and an error bar graph is shown in Figure 1.

Table 2. Descriptive statistics of the tested groups.

	Mean (Newton)	Std. Deviation	Min.	Max.
Negative Control ^a	714.6	195.5	328.0	972.0
ProRoot MTA ^b	1085.1	279.8	761.1	1498.0
Ortho MTA ^b	1032.9	309.2	666.2	1727.2
Biodentine ^b	1049.7	306.3	583.7	1498.1
Endocem MTA ^b	982.3	194.4	533.0	1283.0

*Significantly different groups are shown with different superscript letters.

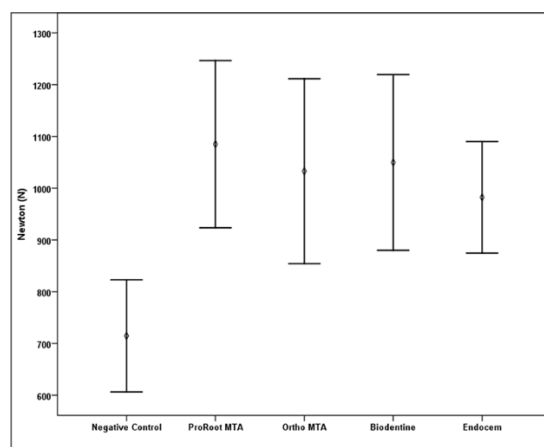


Figure 1. Error bar graph showing the mean values and confidence intervals for the means (95% level) of the tested groups.

DISCUSSION

When a root canal instrument fracture occurs in the apical third of the root canal, excessive removal of the tooth structure also occurs as a result of the fracture removal procedure.¹⁴ This operation can decrease root strength,^{7,14} which can lead to extraction, amputation, or hemisection procedures.¹⁵ Some previous studies have found that after the removal of fractured instruments using ultrasonic tips, the fracture resistance of the tooth was reduced because of the greater loss of root dentin in the middle and coronal thirds of the roots.^{14,16} Another system, the Masserann kit (Micro-Mega, Besancon, France), has rigid and large trepan burs, which remove a considerable amount of dentin tissue while reaching the fractured fragment of an endodontic instrument, further weakening the root.⁸ In this study, a size-3 Peeso reamer drill was used to simulate the trepan drills of fractured instrument removal systems like the Masserann kit, and to mimic the excessive root dentin lost in apically located fractured fragment removal cases.

There is some contradictory data in the literature regarding MTA's ability to reinforce weakened teeth. Bortoluzzi *et al.*¹⁷ found that MTA reinforces the tooth after 48 hours; however, Hatibovic-Kofman *et al.*¹⁸ showed that the strengthening effect could not be achieved until after 1 year of storage. Moreover, Schmoltdt *et al.*¹⁹ found that MTA did not improve the fracture resistance of weakened roots when compared with an unfilled control. In another study, Elnaghy *et al.*²⁰ indicated that Biodentine did not significantly reinforce the teeth when compared to MTA; however, both the MTA and Biodentine groups showed significantly greater fracture resistance values than those of the unfilled teeth. As in our study, those researchers used a phosphate-containing solution to simulate the clinical conditions.²⁰

In this study, the fortification of roots weakened with a simulated fractured instrument removal was investigated using several

different repair materials. According to the findings of this research, the null hypothesis must be accepted, because there was no statistically significant difference among the tested materials ($p > 0.05$). In addition, groups 2, 3, 4, and 5 showed greater fracture resistances than Group 1 ($p < 0.05$), which means that all of the tested repair materials increased the fracture resistance of the roots when compared to the control group. One factor that could have led to these results was the similar moduli of elasticity of the CSMs to that of dentin, which could cause a more homogeneous stress distribution in the root dentin and reduce the chance of fracture.²¹⁻²³

In several studies, it was shown that the use of SBF and phosphate buffered saline (PBS) created an interfacial layer between the dentin and tricalcium silicate cement.^{13,24} The interfacial layer formation mechanism is comprised of the release of Ca^{2+} ions from the CSMs in the phosphate-containing medium, during and after setting. Afterwards, the amorphous calcium phosphate precipitates and transforms into apatite crystals.²⁵ Previous studies have indicated that if the phosphate-containing solution has an ion concentration equal to or close to that of blood plasma, apatite with a composition and structure that is equal to or close to that of bone apatite will be produced.^{26,27} SBF usage has the advantage of providing conditions similar to those of the body's environment.

The bioactivity and interfacial layer formation between the Biodentine and dentin were shown by Kim *et al.*¹³, who found that the interfacial layer thickness of Biodentine was lower than that of the ProRoot MTA. The Ortho MTA manufacturer claims that an interfacial layer of hydroxyapatite is created between the Ortho MTA and the canal wall dentin, thus preventing microleakage.¹¹ Endocem MTA cement possesses the lower calcium releasing ability of pozzolan-based cements, which might result in decreased calcium/phosphorous proportion precipitates.²⁸ Lower fracture

resistance values of the Endocem MTA cement could be related to this situation in this study. However, there were no significant differences among the other test materials. The greater fracture resistances of the CSMs than the negative control group, could also be related to the formation of a hydroxyapatite-like layer between the dentin and CSM.²⁹ The formation of apatite crystals at the CSM and dentin interface has been associated with the ability to seal and the biocompatibility of the cement, indicating chemical bonding between the dentin and CSM.²⁴ The bioactivity of CSMs has been reported to improve the push-out bond strengths of MTA cements because of a strong system of micromechanical bonding to the dentin.²⁵ In one previous study, the authors reported that interfacial hydroxyapatite-like layer formation can increase resistance to vertical root fractures in MTA-filled roots.³⁰

CONCLUSION

Within the limitations of this *in vitro* study, all of the tested materials appear to be good choices for reinforcing the root after the fractured instrument removal from the apical part of the root canal. Further *in vivo* studies are needed to exactly define the effects of CSMs on root canal treated teeth in their natural conditions.

ACKNOWLEDGEMENTS

The authors deny any conflicts of interests related to this study.

REFERENCES

1. Madarati AA, Hunter MJ, Dummer PM. Management of intracanal separated instruments. J Endod 2013;39:569-81.
2. Madarati AA, Watts DC, Qualtrough AJ. Factors contributing to the separation of endodontic files. Br Dent J 2008;204:241-5.
3. Knowles KI, Hammond NB, Biggs SG, Ibarrola JL. Incidence of instrument separation using LightSpeed rotary instruments. J Endod 2006;32:14-6.

4. Wolcott S, Wolcott J, Ishley D, Kennedy W, Johnson S, Minnich S, et al. Separation incidence of protaper rotary instruments: a large cohort clinical evaluation. *J Endod* 2006;32:1139-41.
5. Iqbal MK, Kohli MR, Kim JS. A retrospective clinical study of incidence of root canal instrument separation in an endodontics graduate program: a PennEndo database study. *J Endod* 2006;32:1048-52.
6. Siqueira JF, Jr. Aetiology of root canal treatment failure: why well-treated teeth can fail. *Int Endod J* 2001;34:1-10.
7. Lertchirakarn V, Palamara JE, Messer HH. Patterns of vertical root fracture: factors affecting stress distribution in the root canal. *J Endod* 2003;29:523-8.
8. Gerek M, Baser ED, Kayahan MB, Sunay H, Kaptan RF, Bayirli G. Comparison of the force required to fracture roots vertically after ultrasonic and Masserann removal of broken instruments. *Int Endod J* 2012;45:429-34.
9. Parirokh M, Torabinejad M. Mineral trioxide aggregate: a comprehensive literature review--Part III: Clinical applications, drawbacks, and mechanism of action. *J Endod* 2010;36:400-13.
10. Kim M, Yang W, Kim H, Ko H. Comparison of the Biological Properties of ProRoot MTA, OrthoMTA, and Endocem MTA Cements. *J Endod* 2014;40:1649-53.
11. Lee BN, Son HJ, Noh HJ, Koh JT, Chang HS, Hwang IN, et al. Cytotoxicity of newly developed ortho MTA root-end filling materials. *J Endod* 2012;38:1627-30.
12. Choi Y, Park SJ, Lee SH, Hwang YC, Yu MK, Min KS. Biological effects and washout resistance of a newly developed fast-setting pozzolan cement. *J Endod* 2013;39:467-72.
13. Kim JR, Nosrat A, Fouad AF. Interfacial characteristics of Biodentine and MTA with dentine in simulated body fluid. *J Dent* 2015;43:241-7.
14. Souter NJ, Messer HH. Complications associated with fractured file removal using an ultrasonic technique. *J Endod* 2005;31:450-2.
15. Moule AJ, Kahler B. Diagnosis and management of teeth with vertical root fractures. *Aust Dent J* 1999;44:75-87.
16. Madarati AA, Qualtrough AJ, Watts DC. Effect of retained fractured instruments on tooth resistance to vertical fracture with or without attempt at removal. *Int Endod J* 2010;43:1047-53.
17. Bortoluzzi EA, Souza EM, Reis JM, Esberard RM, Tanomaru-Filho M. Fracture strength of bovine incisors after intra-radicular treatment with MTA in an experimental immature tooth model. *Int Endod J* 2007;40:684-91.
18. Hatibovic-Kofman S, Raimundo L, Zheng L, Chong L, Friedman M, Andreasen JO. Fracture resistance and histological findings of immature teeth treated with mineral trioxide aggregate. *Dent Traumatol* 2008;24:272-6.
19. Schmoldt SJ, Kirkpatrick TC, Rutledge RE, Yaccino JM. Reinforcement of simulated immature roots restored with composite resin, mineral trioxide aggregate, gutta-percha, or a fiber post after thermocycling. *J Endod* 2011;37:1390-3.
20. Elnaghy AM, Elsaka SE. Fracture resistance of simulated immature teeth filled with Biodentine and white mineral trioxide aggregate – an in vitro study. *Dent Traumatol* 2016;32:116-20.
21. Jefferies S. Bioactive and biomimetic restorative materials: a comprehensive review. Part II. *J Esthet Restor Dent* 2014;26:27-39.
22. Jefferies SR. Bioactive and biomimetic restorative materials: a comprehensive review. Part I. *J Esthet Restor Dent* 2014;26:14-26.
23. Schwartz RS, Robbins JW. Post placement and restoration of endodontically treated teeth: a literature review. *J Endod* 2004;30:289-301.

24.Sarkar NK, Caicedo R, Ritwik P, Moiseyeva R, Kawashima I. Physicochemical basis of the biologic properties of mineral trioxide aggregate. J Endod 2005;31:97-100.

25.Reyes-Carmona JF, Felipe MS, Felipe WT. Biomineralization ability and interaction of mineral trioxide aggregate and white portland cement with dentin in a phosphate-containing fluid. J Endod 2009;35:731-6.

26.Kim HM, Kishimoto K, Miyaji F Kokubo T, Yao T, Suetsugu Y, et al. Composition and structure of apatite formed on organic polymer in simulated body fluid with a high content of carbonate ion. J Mater Sci Mater Med. Materials in Medicine 2000;11:421-6.

27.Oyane A, Kim HM, Furuya T, Kokubo T, Miyazaki T, Nakamura T. Preparation and assessment of revised simulated body fluids. J Biomed Mater Res A 2003;65:188-95.

28.Han L, Kodama S, Okiji T. Evaluation of calcium-releasing and apatite-forming abilities

of fast-setting calcium silicate-based endodontic materials. Int Endod J 2015;48:124-30.

29.Han L, Okiji T. Bioactivity evaluation of three calcium silicate-based endodontic materials. Int Endod J 2013;46:808-14.

30.AM EL-Ma, Qualtrough AJ, Watts DC. Resistance to vertical fracture of MTA-filled roots. Dent Traumatol 2014;30:36-42.

Corresponding Author

Dr. Tuğrul ASLAN

Department of Endodontics,

Faculty of Dentistry,

Erciyes University, Kayseri, Turkey.

Tel : +90 352 2076666 - 29137

Fax : +90 352 438 06 57

E-mail : dr.tugrulaslan@hotmail.com



EFFECT OF CORONAL BARRIER THICKNESS ON FRACTURE STRENGTH OF IMMATURE TEETH

Koronal Bariyer Kalınlığının Gelişimi Tamamlanmamış Dişlerin Kırılma Dayanımına Etkisi

Selen KÜÇÜKKAYA EREN, Sevinç ASKERBEYLİ ÖRS, Hacer AKSEL

Makale Kodu/Article Code : 432743

Makale Gönderilme Tarihi : 11.06.2018

Kabul Tarihi : 16.10.2018

ABSTRACT

Objectives: Secondary trauma is one of the main causes of root fracture in regenerative endodontic cases. The aim of this study was to compare the influence of Biodentine that placed with different thicknesses as a coronal barrier material on the fracture strength of simulated immature teeth.

Materials and Methods: The root canals of 65 human maxillary central incisors were instrumented using Peeso reamers to simulate immature teeth. Ten teeth with no access cavity preparation were selected to the negative control group. The access cavities of the remaining 55 teeth were prepared. Among them, the root canals of 10 teeth were filled with calcium hydroxide as the positive control group. Forty-five teeth were randomly divided into 3 groups according to the application thicknesses of Biodentine (n=15); Group 1: 2-3 mm thick coronal plug, Group 2: 5-6 mm thick coronal plug, Group 3: complete canal obturation. After the storage period of 4 weeks, fracture testing was performed using a universal testing machine. One-way analysis of variance and Tukey tests were used to analyze the data.

Results: No significant difference was found among the positive control, group 1 and group 2 ($p > 0.05$). Although there was no significant difference between the negative control ($p > 0.05$) and group 3, these groups indicated the highest fracture strength values ($p < 0.05$). All fractures occurred through the cervical region of the root as horizontally or obliquely.

Conclusions: No significant reinforcement effect was obtained when Biodentine was used as a coronal plug. The complete root canal obturation of simulated immature teeth using Biodentine provided significantly the best reinforcement effect. The coronal plug thickness had no influence on the fracture strength of immature teeth.

Key Words: calcium silicate cement, endodontics, regeneration, tooth fractures

ÖZ

Amaç: Rejeneratif endodontik tedavi görmüş vakalarda kök kırıklarının en önemli nedenlerinden biri sekonder travmalardır. Bu çalışmanın amacı, koronal bariyer materyali olarak farklı kalınlıklarda yerleştirilen Biodentine'in gelişimi tamamlanmamış dişlerin kırılma dayanımına etkisini incelemektir.

Gereç ve Yöntem: Gelişimi tamamlanmamış diş simülasyonu için, 65 adet üst santral dişin kök kanalları Peeso reamerlar ile genişletildi. On dişte giriş kavitesi açılmadı ve bunlar negatif kontrol grubu olarak ayrıldı. Giriş kavitesi açılmış 55 dişin, 10 tanesi pozitif kontrol olarak ayrıldı ve bu dişlerin kök kanalına kalsiyum hidroksit yerleştirildi. Kök kanallarına yerleştirilen Biodentine'in kalınlığına göre 45 diş rastgele olacak şekilde 3 gruba ayrıldı (n=15); Grup 1: 2-3 mm kalınlıkta koronal bariyer, Grup 2: 5-6 mm kalınlıkta koronal bariyer, Grup 3: tüm kanalın dolumu. Dört haftalık bekleme süresi sonrası, kırılma dayanımı analizi universal test cihazı ile gerçekleştirildi. Tek yönlü varyans analizi ve Tukey testleri ile istatistiksel analiz yapıldı.

Bulgular: Pozitif kontrol, Grup 1 ve Grup 2 arasında anlamlı fark yoktu ($p > 0,05$). Negatif kontrol ve Grup 3 en yüksek kırılma dayanımı değerlerini gösterdi ($p < 0,05$) ve bu iki grup arasında anlamlı fark yoktu ($p > 0,05$). Tüm kırıklar dişlerin servikal kısmında yatay veya oblik olarak meydana geldi.

Sonuçlar: Biodentine koronal bariyer olarak kullanıldığında dişlerin kırılma dayanımı üzerinde anlamlı bir güçlendirici bir etkisi olmadı. Kök kanalı tamamen Biodentine ile doldurulduğunda en iyi güçlendirme etkisi oluştu. Koronal bariyer kalınlığının gelişimi tamamlanmamış dişlerin kırılma dayanımına herhangi bir etkisi olmadı.

Anahtar Kelimeler: diş kırıkları, endodonti, kalsiyum silikat siman, rejenerasyon

INTRODUCTION

Traumatic dental injuries frequently affect the maxillary anterior teeth of young patients and often result in arrested root development due to pulpal necrosis.¹ The root canal treatment of these teeth is challenging because of wide open apices and thin dentinal walls.²

Historically, calcium hydroxide (Ca(OH)₂) was used for apexification of infected immature teeth.² However, this treatment approach requires multiple visits and patient compliance. Besides, there is a risk of increased susceptibility to fracture because of long-term Ca(OH)₂ treatment.² To overcome these concerns, one-step apexification using mineral trioxide aggregate (MTA), a calcium silicate-based cement, was proposed.³ Despite the several desirable properties of this material including good sealing ability, biocompatibility and bioactivity³, no increase in the root length and thickness of dentinal walls can be obtained with this treatment.⁴ According to recent studies, fracture was the primary cause of failure in immature teeth treated with one-step apexification using a calcium silicate-based cement.^{4,5}

Currently, regenerative endodontic treatment is an alternative approach to provide root development in immature teeth.⁶ The treatment procedure involves the disinfection of the root canal system, the formation of a blood clot by inducing bleeding inside the root canal and the placement of a biocompatible coronal barrier to create a hermetic seal.⁷ In recent years, several case studies have reported successful outcomes in the treatment of infected immature teeth using regenerative endodontic procedures.⁷⁻¹³ In the majority of these cases, calcium silicate-based cements including MTA and Biodentine were used as coronal barrier materials.^{7,10-13} Despite its favorable biologic properties, MTA has some drawbacks such as poor handling characteristics, low wash-out resistance and long setting time.¹⁴ Biodentine was introduced

as a dentin substitute under resin composite restorations and reported to exhibit short setting time and high mechanical properties.¹⁵

It was reported that secondary trauma was the cause of root fracture in 85% of cases.¹⁶ Although there is no definite protocol to provide the best outcome in the treatment of necrotic immature teeth, a coronal plug of approximately 3 mm thickness has been suggested to be sufficient for regenerative endodontic procedures.¹⁷ However, the optimal thickness of a coronal barrier is not clear. Positive outcomes have been reported after regenerative endodontic treatment in previous case reports in which barrier materials at different thicknesses were applied.^{9-11,13} The thickness of coronal plug may affect the fracture strength of immature teeth treated with regenerative endodontic procedures. Therefore, the aim of this study was to compare the influence of placing Biodentine as a barrier material at different thicknesses on the fracture strength of simulated immature teeth.

MATERIALS AND METHODS

Specimen Selection

After approval by the ethics committee (Ethics Board No: 18/233), 65 freshly extracted human maxillary central incisors were selected and inspected under magnification to confirm the absence of caries, cracks, abrasions, resorptions or fractures. The buccolingual and mesiodistal dimensions of each tooth were measured using a digital caliper (Mitutoyo, Hampshire, UK). For standardization purposes, teeth with similar dimensions and a length of 20 ± 0.5 mm were used.

Treatment Procedures

The apical 3 mm of each root-end was removed to simulate immature root apices. Randomly selected 10 teeth were assigned to the negative control group with no access cavity preparation. Their root canals were instrumented from apical to coronal direction using Peeso reamers (Dentsply Maillefer,

Ballaigues, Switzerland) up to size 5 to simulate immature teeth.¹⁸ Irrigation was performed only with distilled water in this group.

Endodontic access cavities were prepared in the remaining 55 teeth using a diamond round bur attached to a high-speed handpiece. To simulate immature root apices, the root canals were prepared with Peeso reamers (Dentsply Maillefer) between #1 and #5 at 1 mm beyond the apex. The root canals were irrigated with 1 ml of 2.5% sodium hypochlorite (NaOCl) between the instruments. The final irrigation was performed with the sequential use of 5 ml of 2.5% NaOCl, 5 ml of 17% ethylenediaminetetraacetic acid (EDTA) and 5 ml of distilled water. Finally, the root canals were dried using paper points. Ca(OH)₂ was placed in the root canals of 10 teeth with a lentulo spiral (Dentsply Maillefer) and these teeth served as the positive control.

Forty-five teeth were randomly distributed into 3 groups (n=15) according to the thickness of barrier material (Fig. 1A-C).

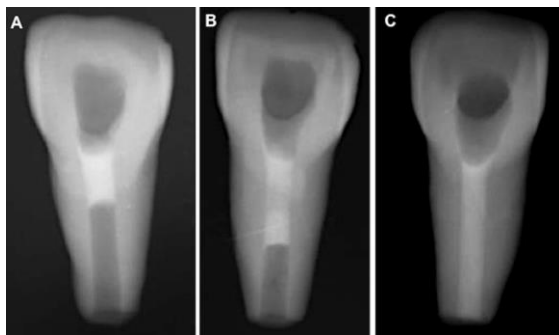


Figure 1. Representative images of groups obturated with Biodentine. (A) 2-3-mm coronal plug, (B) 5-6-mm coronal plug and (C) complete obturation.

In these groups, Biodentine (Septodont, Saint Maur des Fosses, France) was mixed according to the manufacturer's instructions and delivered to the root canals from the coronal access with a carrier (MTA Endo gun, Dentsply Maillefer). In group 1, Biodentine was condensed with a hand plugger (Buchanan Hand Plugger, SybronEndo, Orange, USA) to obtain a 2-3 mm thick coronal plug (Fig. 1A). In group 2, Biodentine was condensed with the hand plugger to obtain a 5-6 mm thick coronal

plug (Fig. 1B). In group 3, the root canals were completely obturated with Biodentine using the hand plugger (Fig. 1C). In groups 1 and 2, the thickness of barrier material was arranged using customized gutta-percha points. A gutta-percha point that fits tightly in the root canal was shortened to the appropriate length for each specimen and temporarily inserted into the root canal from apical to coronal direction.¹⁹ The depth of space left for the barrier material was confirmed with a periodontal probe. The gutta-percha placement facilitated the material condensation, prevented apical movement of the material and allowed standardization of coronal barrier thickness. Each gutta percha point was removed after the material setting completed. The thickness of barrier material and uniform obturation were confirmed with periapical radiographs. Each access cavity was restored with composite resin (Ice, SDI, Bayswater, Victoria, Australia). All specimens were stored at 37°C and 100% humidity for 4 weeks.

In this study, a single operator performed the preparation of access cavities and root canals; a second operator performed the obturation procedures.

Fracture test

The external root surfaces were covered with an impression material (Variotime, Heraeus Kulze, Hanau, Germany) to simulate a periodontal ligament as described in a previous study.²⁰ The teeth were vertically embedded in self-curing acrylic resin (Meliodent, Heraeus Kulzer) poured in cylindrical molds, leaving a 2 mm gap between the top of the resin and the cemento-enamel junction. The fracture test was performed using a universal testing machine (Lloyd LR 30K, Fareham, UK). The load was applied on the facial surface at 135° to the specimen's long axis at a point 3 mm above the cemento-enamel junction. The specimens were loaded at a cross-head speed of 1 mm/min. The maximum load that fracture occurred was recorded in Newtons (N).

Statistical Analysis

Data were evaluated for normal distribution using the Kolmogorov-Smirnov test. Due to the normal distribution of data, the groups were compared using one-way analysis of variance and Tukey tests. The significance level was set at $p = 0.05$.

RESULTS

The fracture strength values of the groups are presented in Table 1.

Table 1. The Mean Peak Load (N) and Standard Deviation (SD) of the Groups

Groups	n	Mean \pm SD (N)	Minimum	Maximum
Negative control	10	992.47 \pm 70.41 ^a	863.09	1100.01
Positive control	10	688.50 \pm 91.30 ^b	518.28	813.84
Group 1 (2-3 mm coronal plug)	15	696.48 \pm 127.13 ^b	493.85	911.81
Group 2 (5-6 mm coronal plug)	15	797.36 \pm 188.49 ^b	488.58	1088.26
Group 3 (completely obturated)	15	978.13 \pm 134.35 ^a	682.84	1129.56

Different superscript letters indicate significant differences between the groups ($p < 0.05$).

No significant difference was found among the positive control, group 1 and group 2 ($p > 0.05$). Although there was no significant difference between the negative control and group 3 ($p > 0.05$), these groups indicated the highest fracture strength values ($p < 0.05$). All fractures occurred through the cervical region of the root horizontally or obliquely.

DISCUSSION

The major purpose of regenerative endodontic treatment is to eliminate infection from the root canal system and to obtain complete root formation.¹² In this way, long-term complications such as fracture that occurred due to incomplete root development and thin dentinal walls can be prevented.²¹ However, in several studies, the outcome of regenerative endodontic treatment was lower than ideal, because of incomplete formation of root apex, no increase in root length or thickness.^{11,22,23} Although the first indication of root development was usually detected after 6-month follow-up^{9,12,13}, in a recent study failure was detected after 4-year follow-up indicating the need for long-term follow-up of regenerative endodontic cases.²⁴ As the desired

outcomes are often obtained after a long period, these teeth are usually prone to fracture for a considerable time after regenerative endodontic treatment. The treatment protocol applied during regenerative endodontic procedures may affect the fracture strength of immature teeth. Therefore, the effect of barrier material thickness on the fracture strength of immature teeth was evaluated in the current study.

Recently, the use of Biodentine during regenerative endodontic treatment has been recommended to prevent teeth discoloration⁶ and to complete the final restoration in the same appointment owing to its short setting time.^{13,25} Moreover, a desirable tissue response is expected with the use of Biodentine due to its biocompatibility and osteogenic potential.²⁶ Based on these, Biodentine was used as a barrier material in the present study. The current study model included mature teeth prepared to simulate immature roots. To accomplish this, the root canals were prepared with Peeso reamers beyond the apex after root-end resection similar to previous studies.^{27,28} The load was applied at an angle of 135° during fracture to simulate a traumatic impact on the facial surface of the crowns.¹⁸ In the present study, all specimens fractured through the cervical area of the roots indicating that the experimental set-up provided a repeatable system for each trial.²⁹

Based on the present findings, the intact immature tooth group presented significantly higher fracture resistance than the coronal plug groups and Ca(OH)₂ treatment group. This finding could be related to the adverse effects of access cavity preparation on the fracture strength of teeth.^{18,19} In the current study, each access cavity was restored with composite resin and this probably did not provide adequate strengthening to the cervical root region. It has been suggested that root canal irrigants may negatively alter several properties of dentin such as microhardness,

elasticity, and flexural strength.^{30,31} Therefore, another explanation for the higher fracture resistance results of the intact group can be the irrigation protocol, which was performed only with distilled water.

According to several studies, the use of Ca(OH)_2 as a medicament increases the risk of root fracture.^{2,32} This effect has been associated with the denaturation and hydrolysis process in the organic part of dentin due to the high pH of Ca(OH)_2 .³² However, in the present study, no significant difference was found between the Ca(OH)_2 treatment group and the coronal plug groups. This result may be related to the duration of Ca(OH)_2 in the root canal. The duration of Ca(OH)_2 medication was 4 weeks in this study. Previously, a significant decrease in fracture strength was reported after 3 months of Ca(OH)_2 application, while 1-month medication did not negatively affect the fracture strength of roots.³³

In the current study, the immature teeth that completely obturated with Biodentine exhibited high fracture resistance similar to the intact immature tooth group. The current findings were in line with several studies that found obturating the root canal completely with a calcium silicate-based cement can enhance the fracture strength of immature teeth.^{34,35} The relatively high elastic modulus of Biodentine may have contributed to this result by providing reinforcement effect.³⁶ Also, an apatite-like layer formation between the material and dentin owing to the bioactivity of Biodentine could enhance the fracture resistance of simulated immature teeth.³⁷ Interestingly, no significant reinforcement effect was obtained when Biodentine was used as a coronal plug. The complete canal obturation with Biodentine may have created more mechanically homogenous units with dentin compared to partial obturation, thus contributing to the fracture strength of teeth.

In conclusion, the complete root canal obturation of simulated immature teeth using

Biodentine provided the best reinforcement effect. However, unlike regenerative endodontic treatment, no development in root length and thickness is expected with this treatment clinically.⁴ Therefore, when interpreting the present results, the possibility of root development with regenerative endodontic procedures should be taken into account. Although positive outcomes have been reported in various clinical reports that performed regenerative endodontic treatment using different thicknesses of coronal plugs^{9-11,13}, development of new tissue is not likely to occur in the area where a biomaterial is placed.¹⁷ As the thicker coronal plug did not provide an additional contribution to the fracture strength in the current study, a 2-3 mm thick coronal plug application can be recommended for regenerative endodontic procedures, both biologically and mechanically.

Conflicts of interest

The authors declare no potential conflicts of interest with respect to the authorship and/or publication of this article.

REFERENCES

1. Hargreaves KM, Diogenes A, Teixeira FB. Treatment options: biological basis of regenerative endodontic procedures. *J Endod* 2013;39:30-43.
2. Andreasen JO, Farik B, Munksgaard EC. Long-term calcium hydroxide as a root canal dressing may increase risk of root fracture. *Dent Traumatol* 2002;18:134-137.
3. Torabinejad M, Chivian N. Clinical applications of mineral trioxide aggregate. *J Endod* 1999;25:197-205.
4. Jeeruphan T, Jantarat J, Yanpiset K, Suwannapan L, Khewsawai P, Hargreaves KM. Mahidol study 1: comparison of radiographic and survival outcomes of immature teeth treated with either regenerative endodontic or apexification

methods: a retrospective study. *J Endod* 2012;38:1330-1336.

5. Silujjai J, Linsuwanont P. Treatment outcomes of apexification or revascularization in nonvital immature permanent teeth: a retrospective study. *J Endod* 2017;43:238-245.

6. Lin J, Zeng Q, Wei X, Zhao W, Cui M, Gu J, Lu J, Yang M, Ling J. Regenerative endodontics versus apexification in immature permanent teeth with apical periodontitis: a prospective randomized controlled study. *J Endod* 2017;43:1821-1827.

7. Banchs F, Trope M. Revascularization of immature permanent teeth with apical periodontitis: new treatment protocol? *J Endod* 2004;30:196-200.

8. Iwaya SI, Ikawa M, Kubota M. Revascularization of an immature permanent tooth with apical periodontitis and sinus tract. *Dent Traumatol* 2001;17:185-187.

9. Chueh LH, Huang GT. Immature teeth with periradicular periodontitis or abscess undergoing apexogenesis: a paradigm shift. *J Endod* 2006;32:1205-1213.

10. Jung IY, Lee SJ, Hargreaves KM. Biologically based treatment of immature permanent teeth with pulpal necrosis: a case series. *J Endod* 2008;34:876-887.

11. Petrino JA, Boda KK, Shambarger S, Bowles WR, McClanahan SB. Challenges in regenerative endodontics: a case series. *J Endod* 2010;36:536-541.

12. Bukhari S, Kohli MR, Setzer F, Karabucak B. Outcome of revascularization procedure: a retrospective case series. *J Endod* 2016;42:1752-1759.

13. Bakhtiar H, Esmaili S, Fakhr Tabatabayi S, Ellini MR, Nekoofar MH, Dummer PM. Second-generation platelet concentrate (platelet-rich fibrin) as a scaffold in regenerative endodontics: a case series. *J Endod* 2017;43:401-408.

14. Kogan P, He J, Glickman GN, Watanabe I. The effects of various additives on setting properties of MTA. *J Endod* 2006;32:569-572.

15. Grech L, Mallia B, Camilleri J. Investigation of the physical properties of tricalcium silicate cement-based root-end filling materials. *Dent Mater* 2013;29:e20-28.

16. Al-Jundi SH. Type of treatment, prognosis, and estimation of time spent to manage dental trauma in late presentation cases at a dental teaching hospital: a longitudinal and retrospective study. *Dent Traumatol* 2004;20:1-5.

17. Wigler R, Kaufman AY, Lin S, Steinbock N, Hazan-Molina H, Torneck CD. Revascularization: a treatment for permanent teeth with necrotic pulp and incomplete root development. *J Endod* 2013;39:319-326.

18. Cicek E, Yilmaz N, Kocak MM, Saglam BC, Kocak S, Bilgin B. Effect of mineral trioxide aggregate apical plug thickness on fracture resistance of immature teeth. *J Endod* 2017;43:1697-1700.

19. Uzunoglu E, Eymirli A, Uyanik MO, Nagas E, Cehreli ZC. Fracture resistance of simulated immature teeth after internal bleaching procedures. *Aust Endod J* 2017.

20. Chan T, Kucukkaya Eren S, Wong R, Parashos P. In vitro fracture strength and patterns in root-filled teeth restored with different base materials. *Aust Dent J* 2018;63:99-108.

21. Galler KM. Clinical procedures for revitalization: current knowledge and considerations. *Int Endod J* 2016;49:926-936.

22. Nosrat A, Seifi A, Asgary S. Regenerative endodontic treatment (revascularization) for necrotic immature permanent molars: a review and report of two cases with a new biomaterial. *J Endod* 2011;37:562-567.

23. Chen MY, Chen KL, Chen CA, Tayebaty F, Rosenberg PA, Lin LM. Responses of immature permanent teeth with infected

necrotic pulp tissue and apical periodontitis/abscess to revascularization procedures. *Int Endod J* 2012;45:294-305.

24.Chaniotis A. Treatment options for failing regenerative endodontic procedures: report of 3 cases. *J Endod* 2017;43:1472-1478.

25.Topcuoglu G, Topcuoglu HS. Regenerative endodontic therapy in a single visit using platelet-rich plasma and Biodentine in necrotic and asymptomatic immature molar teeth: a report of 3 cases. *J Endod* 2016;42:1344-1346.

26.Bortoluzzi EA, Niu LN, Palani CD, El-Awady AR, Hammond BD, Pei DD, Tian FC, Cutler CW, Pashley DH, Tay FR. Cytotoxicity and osteogenic potential of silicate calcium cements as potential protective materials for pulpal revascularization. *Dent Mater* 2015;31:1510-1522.

27.Ulusoy OI, Nayir Y, Darendeliler-Yaman S. Effect of different root canal sealers on fracture strength of simulated immature roots. *Oral Surg Oral Med Oral Pathol Oral Radiol Endod* 2011;112:544-547.

28.Tanalp J, Dikbas I, Malkondu O, Ersev H, Gungor T, Bayirli G. Comparison of the fracture resistance of simulated immature permanent teeth using various canal filling materials and fiber posts. *Dent Traumatol* 2012;28:457-464.

29.Hemalatha H, Sandeep M, Kulkarni S, Yakub SS. Evaluation of fracture resistance in simulated immature teeth using Resilon and Ribbond as root reinforcements--an in vitro study. *Dent Traumatol* 2009;25:433-438.

30.Ari H, Erdemir A, Belli S. Evaluation of the effect of endodontic irrigation solutions on the microhardness and the roughness of root canal dentin. *J Endod* 2004;30:792-795.

31.Zhang K, Kim YK, Cadenaro M, Bryan TE, Sidow SJ, Loushine RJ, Ling JQ, Pashley DH, Tay FR. Effects of different exposure times and concentrations of sodium hypochlorite/ethylenediaminetetraacetic acid

on the structural integrity of mineralized dentin. *J Endod* 2010;36:105-109.

32.White JD, Lacefield WR, Chavers LS, Eleazer PD. The effect of three commonly used endodontic materials on the strength and hardness of root dentin. *J Endod* 2002;28:828-830.

33.Andreasen JO, Munksgaard EC, Bakland LK. Comparison of fracture resistance in root canals of immature sheep teeth after filling with calcium hydroxide or MTA. *Dent Traumatol* 2006;22:154-156.

34.Karapinar-Kazandag M, Basrani B, Tom-Kun Yamagishi V, Azarpazhooh A, Friedman S. Fracture resistance of simulated immature tooth roots reinforced with MTA or restorative materials. *Dent Traumatol* 2016;32:146-152.

35.Linsuwanont P, Kulvitit S, Santiwong B. Reinforcement of simulated immature permanent teeth after mineral trioxide aggregate apexification. *J Endod* 2018;44:163-167.

36.Natale LC, Rodrigues MC, Xavier TA, Simoes A, de Souza DN, Braga RR. Ion release and mechanical properties of calcium silicate and calcium hydroxide materials used for pulp capping. *Int Endod J* 2015;48:89-94.

37.Elnaghy AM, Elsaka SE. Fracture resistance of simulated immature teeth filled with Biodentine and white mineral trioxide aggregate - an in vitro study. *Dent Traumatol* 2016;32:116-120.

Corresponding Author

Selen KÜÇÜKKAYA EREN, DDS, PhD

Department of Endodontics

Faculty of Dentistry,

Hacettepe University

Sihhiye, Ankara/Turkey, 06100

Tel : +903123052260

Fax : +903123104440

E-mail : selenkkaya@yahoo.com



HEMANGIOMA PRESENTING WITH MULTIPLE PHLEBOLITHS: CASE REPORT WITH CBCT FINDINGS

Multiple Flebolit Görülen Hemanjiyom: KIBT Bulguları ile Olgu Sunumu

Hazal KARSLIOGLU, A.Pınar SUMER

Makale Kodu/Article Code : 410482

Makale Gönderilme Tarihi : 28.03.2018

Kabul Tarihi : 31.07.2018

ABSTRACT

Hemangiomas are benign tumors of infancy that display a rapid growth phase with endothelial cell proliferation. Phleboliths are calcified thrombi found in veins, venulae and sinusoidal vessels of hemangiomas. In the head and neck, phleboliths nearly always signal the presence of a hemangioma. Hemangioma with multiple phleboliths is described including its features on panoramic radiography and cone beam computed tomography images.

Keywords: cone beam computed tomography, hemangioma, phlebolith

ÖZ

Hemanjiyomlar, endotel hücrelerinin proliferasyonu ile karakterize bebeklik çağının benign tümörleridir. Flebolitler, hemanjiyomların damar, venül ve sinüzoid damarlarında bulunan kalsifiye trombüslerdir. Baş ve boyunda görülen flebolitler, hemen hemen daima hemanjiyomun varlığını işaret eder. Multiple flebolit bulunan hemanjiyom olgusu, panoramik radyografi ve konik ışını bilgisayarlı tomografi görüntüleri ile sunulmuştur.

Anahtar kelimeler: Flebolit, hemanjiyom, konik ışını bilgisayarlı tomografi

INTRODUCTION

Hemangiomas are benign vascular anomalies characterized by an increase in turnover and proliferation of endothelial cells. According to histopathologic features of hemangiomas, capillary, cavernous, mixed types are available.¹ Hemangiomas can not be recognized at birth but arise subsequently during the first 8 weeks of life. They are the most common tumors of infancy, occurring in %5 to %10 of 1 year old children.² The average age at diagnosis is 10 years, with 65% occurring in the first 2 decades of life.³ Hemangiomas occur more frequently in females than in males.^{2,3} The most common location is head and neck.² The precise cause of hemangioma is not known, but, either hormonal changes and traumas have been postulated as being involved.^{4,5} The predominant complaint is presence of a slow-growing palpable mass that can fluctuate. The skin overlying the hemangioma will often show increased vascularity, giving the hemangioma a bluish tint. Clinical manifestations such as swelling, pain, discoloration, pulsation, compressibility, thrills, bruits can be seen.⁶⁻⁸ Phlebolith responds to auscultation in the hemangioma of the cavernous type if it originated from a vein or soft tissue hemangioma.⁹ Increasing venous pressure, changes the size of the hemangioma. Masses in the head and neck hemangiomas enlarge during conditions that increase venous pressure, such as crying, laughing or performing handstands.¹⁰ Changes in blood flow in hemangiomas may induce phlebolith formation. Phleboliths are calcified thrombi found in veins, venulae and sinusoidal vessels of the especially cavernous type hemangiomas. The phlebolith comprise a mixture of calcium carbonate and calcium phosphate salts.³ They are in the idiopathic calcification classification that occurs in normal tissues despite normal serum calcium and phosphate levels. They are usually multiple, varied in size, randomly distributed. Phleboliths do not show any symptoms and they may be found during routine imaging. Although standard radiographs are an important

diagnostic tool for the diagnosis of phleboliths in the mass, computerized tomography (CT), magnetic resonance imaging (MRI) and ultrasonography play an important role in the diagnosis of hemangioma.¹¹ MRI is very useful for the detection of vascular lesions^{10,12}, but the detectability of phleboliths in CT is greater than that of MRI.¹³ Phleboliths usually have a lamellar appearance such as bull's eye but they can also have a homogenous radiopaque image with an oval or round shape, approximately 6 mm in diameter.³

The presence of phleboliths demonstrated on panoramic radiography is rarely described in the literature. The following report presents the first reported case of multiple phleboliths with cone beam CT and panoramic radiography in a 37 years old female patient with head and neck hemangioma.

CASE REPORT

A 37 year old woman patient referred to dentomaxillofacial radiology clinic, with a complaint of severe pain in the right mandibular posterior area occurred after the first molar tooth extraction. The patient's medical and family history was unremarkable. Extraoral examination revealed hemangioma on the right side that had been presented since 2 years old and gradually increased in size. A diffuse right facial swelling caused facial asymmetry was visible, occupying the buccal soft tissue area. There was a bluish discoloration of the overlying face skin (Figure 1).

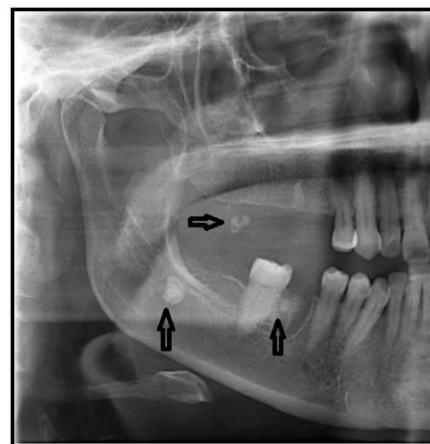


Figure 1: The appearance of Hemangioma as extraoral.

Intraoral examination showed discoloration of oral mucosa in the related region (Figure 2).

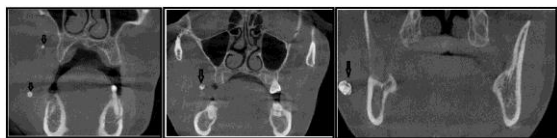

Figure 2: The appearance of Hemangioma in buccal and palatal mucosa.

Palpation indicated that the lesion was nonpulsatile. Bruit that is heard with stethoscope, did not reveal on auscultation of head and neck. Lymphadenopathy was not presented. Panoramic radiographic examination revealed radiopacities in variable sizes from 2-8 mm characteristic of phleboliths (Figure 3).

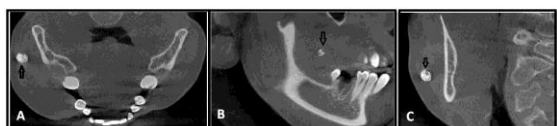


Figure 3: A panoramic radiograph showing multiple round target-like radiopacities varying in size from 2 to 8mm (arrows)

Cone beam CT images showed the existence of multiple phleboliths (Figure 4,5). The patient had no complaint such as pain or aesthetic discomfort about hemangioma. She was only enrolled for treatment of alveolitis.

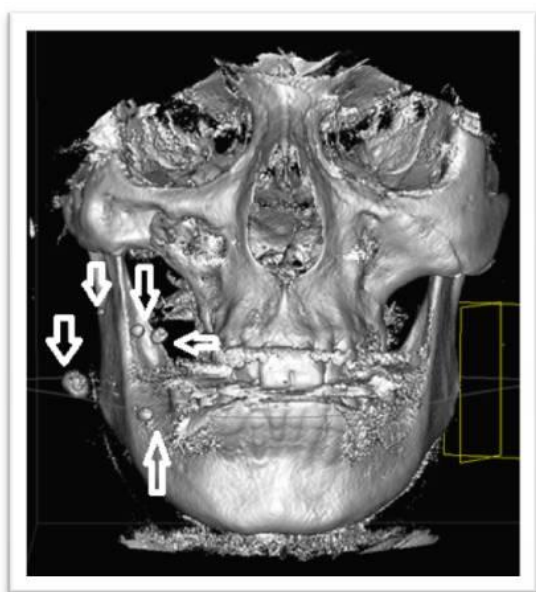


Figure 4: Cone beam CT images on the coronal plane show multiple calcifications consistent with phlebolith (arrows).

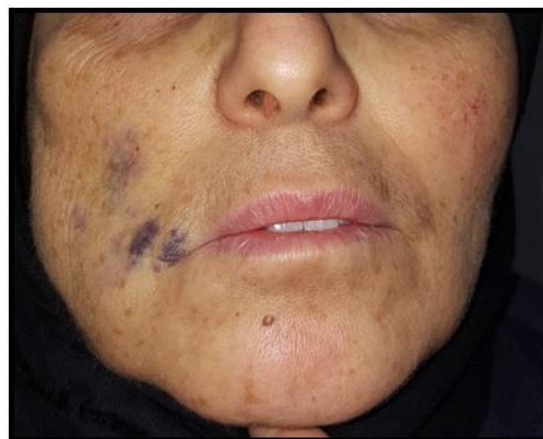

Figure 5A. The appearances of phleboliths on axial cone beam CT image

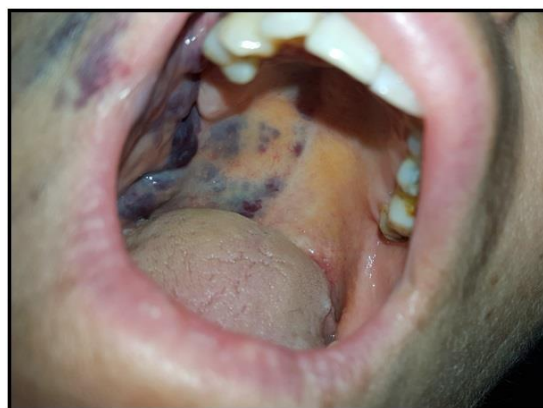

Figure 5B. Sagittal cone beam CT image

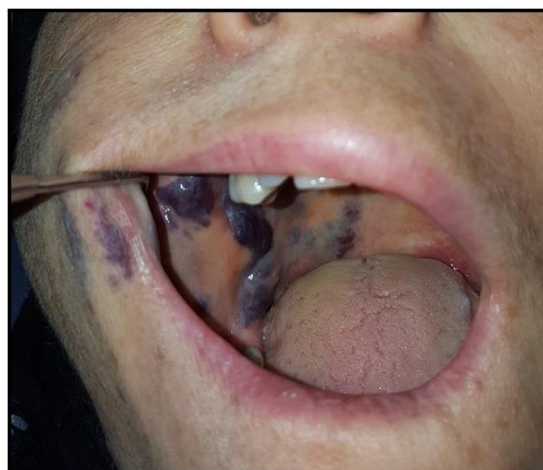

Figure 5C. Cross-sectional cone beam CT image (C) (arrows).

DISCUSSION

Hemangiomas are benign vascular lesions that cause symptoms such as mass, swelling, pain and discoloration.⁶ They occur on both skin and mucosal surfaces frequently in the head and neck region² but are rare in the oral cavity.¹⁴ Presented case was unilaterally seen

in the head and neck skin area and in the oral cavity mucosa.

Phleboliths are calcified thrombi found within vascular channels and occur frequently in the presence of hemangiomas or vascular malformations. They arise from injury to a vessel wall or result from stagnation of the flow of blood. Phleboliths generally cause no symptoms.

Radiologically, they are seen either radiolucent or radiopaque. A fibrinous component is attached to the developing phleboliths and becomes calcified. Repetition of the process causes a layering effect and so phlebolith usually has a concentric ring or onion like appearance.¹⁵

Characterization and spread of tumors can only be recognized by CT or MRI. CT with contrast is an excellent imaging technique for revealing phleboliths.⁵ Hemangiomas are usually seen as masses with well-defined phlebolith on the tomography. MRI can produce high signal intensity representing blood, in addition focal heterogenities representing areas of thrombosis, fibrosis or calcifications. Hemangiomas show hyperintensity on T2-weighted images and isointensity on T1-weighted images.^{10,16} Phleboliths were seen as a nonenhancement nodular structures in contrast-enhanced T1-weighted MR scans and hypointense structures in T2-weighted MR scans.¹⁰ Ultrasonography is a cheap and noninvasive method and phleboliths were seen on imaging as multiple hyperechoic areas within the mass.³ In this case report cone beam CT was used for detailed examination of phleboliths with lower radiation dose and cost, significantly higher spatial resolution compared with CT. According to our knowledge, the present case report is a unique one evaluating phleboliths using cone beam CT that can provide useful information about location and extent of the phleboliths.

Head or neck phleboliths must be differentiated from other calcifications, such as sialoliths, calcified lymph nodes, foreign bodies, tonsilloliths, atherosclerotic plaques in the carotid artery, healed acne lesions, cysticercosis, and miliary skin osteomas, that occur in the same area.¹⁵ Sialoliths appear on a single line when seen more than one, whereas phleboliths are randomly distributed. Phleboliths usually coexist with hemangiomas.³

The treatment of the hemangiomas is based on location, accessibility, depth of invasion, age, and cosmetic appearance. Treatment modalities include the use of corticosteroids, interferon alfa 2a or interferon alfa 2b, ligation of the feeding vessels, cryotherapy, embolization and sclerotherapy, fibrous agents and lasers.^{1,5} Periodic observation is also an alternative treatment.¹¹ In the present case, since the patient does not have any aesthetic or functional complaints, she is being followed.

In conclusion, panoramic radiography can show presence of phleboliths and cone beam CT can provide useful information about the location and extension of the lesion.

The study was presented as a poster presentation in the 2nd International Congress of Oral Diagnosis and Maxillofacial Radiology Society, at April 13-15, 2017 held in Eskişehir, Turkey.

REFERENCES

1. Allen PW, Enzinger FM. Hemangioma of skeletal muscle: An analysis of 89 cases. *Cancer*. 1972;29:8-22.
2. Neville BW, Damm DD, Allen CM, Bouquot JE. *Oral and Maxillofacial pathology*. 3rd ed. St. Louis: Elsevier; 2009.
3. White SC, Pharoach MJ. *Oral Radiology Principles and Interpretation*. 4th ed. Philadelphia: Mosby Inc; 2000.

4. Rossiter JL, Hendrix RA, Tom LW, Potsic WP. Intramuscular hemangioma of the head and neck. *Otolaryngology Head Neck Surg.* 1993;108:18-26.
5. Wolf GT, Daniel F, Krause CJ, Kaufman RS. Intramuscular hemangioma of the head and neck. *Laryngoscope.* 1985;95:210-3.
6. Aynalı G, Unal F, Yarıktaş M, Yasan H, Ciriş M, Yılmaz O. Submandibular hemangioma with multiple phleboliths mimicking sialolithiasis: the first pediatric case. *Kulak Burun Bogaz Ihtis Derg.* 2014;24:168-71.
7. Addante RR, Donovan MG. Right facial mass. *J Oral Maxillofac Surg.* 1994;52:1061-5.
8. Tsang WM, Tong AC, Wu PC. Cavernous hemangioma of the masseter muscle. *Oral Surg Oral Med Oral Pathol Oral Radiol Endod.* 1998;85:629-30.
9. Yıldırım D, Bilgir E. Baş Boyun Bölgesindeki Yumuşak Doku Kalsifikasyon Ve Ossifikasyonlari *J Dent Fac Atatürk Uni.* 2015;13: 82- 90.
10. Zengin AZ, Çelenk P, Sumer AP. Intramuscular hemangioma presenting with multiple phleboliths: a case report. *Oral Surg Oral Med Oral Pathol Oral Radiol.* 2013; 115:e32-6.
11. Altuğ HA, Büyüksoy V, Okçu KM, Doğan N. Hemangiomas of the head and neck with phleboliths: clinical features, diagnostic imaging, and treatment of 3 cases. *Oral Surg Oral Med Oral Pathol Oral Radiol Endod.* 2007;103:e60-4
12. Gold L, Nazarian LN, Johar AS, Rao VM. Characterization of maxillofacial soft tissue vascular anomalies by ultrasound and color Doppler imaging: an adjuvant to computed tomography and magnetic resonance imaging. *J Oral Maxillofac Surg.* 2003; 61:19-31.
13. Kakimoto N, Tanimoto K, Nishiyama H, Murakami S, Furukawa S, Kreiborg S. CT and MR imaging features of oral and maxillofacial hemangioma and vascular malformation. *European J Radiol.* 2005;55:108-12.
14. Kripal K, Rajan S, Ropak B, Jayanti I. Cavernous hemangioma of the tongue. *Case Rep Dent.* 2013; doi: 10.1155/2013/898692.
15. Mandel L, Perrino MA. Phleboliths and the vascular maxillofacial lesion. *J Oral Maxillofac Surg.* 2010;68:1973-6.
16. Yonetsu K, Nakayama E, Yuasa K, Kanda S, Ozeki S, Shinohara M. Imaging findings of some buccomasseteric masses. *Oral Surg Oral Med Oral Pathol Oral Radiol Endod.* 1998;86:755-9.

Corresponding Author

Hazal Karslioglu, DDS

Ondokuz Mayıs University

Faculty of Dentistry

Department of Dentomaxillofacial Surgery

55139 Kurupelit, Samsun TURKEY

Tel : +90 (362) 3121919-8150

Fax : +90 (362) 4576032

E-mail : hazal1111k@hotmail.com



KOMPLİKE KRON KIRIĞI OLGUSUNDA FİBER POST DESTEKLİ KOMPOZİT RESTORASYON: OLGU SUNUMU

*Composite Restoration Supported with Fiber Post in Case Complşcated Crown
Fracture: A Case Report*

Seda ÖZKANÖĞLU, Emine Gülşah GÖKTOLGA AKIN, İhsan HUBBEZOĞLU

Makale Kodu/Article Code : 412782

Makale Gönderilme Tarihi : 05.04.2018

Kabul Tarihi : 02.10.2018

ÖZ

Ön bölge kırıkları daimî dentisyonda en sık görülen travma şeklidir. Bu tür travmalar hastada fonksiyonel ve estetik problemlere sebep olmaktadır. Bu tür durumlarda eğer aşırı derecede kron harabiyeti meydana gelmişse tutuculuğu artırmak için kök kanal tedavisi ile birlikte post uygulanması gerekebilmektedir. Adeziv rezinler, simanlar, kompozit restoratif materyaller, fiber postlarda meydana gelen teknolojik gelişmeler endodontik olarak tedavi görmüş ve madde kaybına uğrayan dişlerin daha estetik ve kök kırıklarına neden olmayacak şekilde rehabilitasyonuna izin vermektedir. Bu çalışmada, kron harabiyeti olan üst kesici dişin cam fiber post ve direkt kompozit rezin uygulamaları ile restorasyonu anlatılmaktadır. Kron harabiyeti gösteren endodontik tedavi görmüş dişlerin fiber post ve direkt rezin kompozitlerle restore edilmesi diş dokularının korunmasını ve hastaların memnuniyetini sağlayan, kısa sürede tamamlanabilen ve protetik işlemlere göre daha ucuz bir tedavi seçeneğidir.

Anahtar kelimeler: Estetik, Fiber Post, Kompozit Resin

ABSTRACT

Dental fractures which seen in the anterior region are the most common form of trauma in the permanent dentition. Such trauma causes the functional and aesthetic problems in the patient. In such cases, if excessive crown fractures has occurred, the root canal treatment and the post application is needed to increase the retention. The evaluation of fiber posts, adhesive resins, cements and composite restoratives allows the rehabilitation of damaged endodontically treated teeth with greater esthetic and virtually no predisposition to root fracture. In this study describe to restoration of the crown damaged upper incisor tooth with glass fiber post and direct composite resin applications. Restoration of damaged endodontically treated teeth with fiber posts and direct resin composites conserves remaining tooth structures, results in good patient compliance, could be completed in the short term and cheaper treatment option than prosthetic restorations.

Keywords: Aesthetic, Composite Resin, Fiber Post

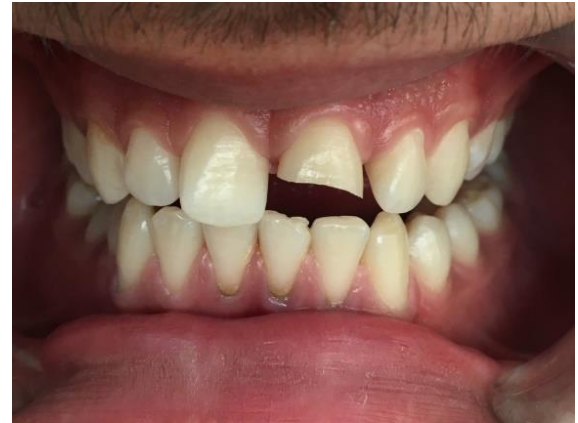GİRİŞ

Diş dokularının büyük bir kısmının kaybedilmesi en çok çürük ve travmadan dolayı olmaktadır. Travma nedenleri arasında sportif faaliyetler ve şiddet gelmektedir.¹ Çürük, travma ve çeşitli nedenlerden dolayı kron harabiyetine uğramış dişlerin, endodontik tedaviyi takiben fonksiyon, fonasyon ve estetiğinin geri kazandırılması için restoratif tedavileri gerekmektedir.² Endodontik tedavi görmüş dişleri dayanıklılığını destekleyecek şekilde restore etmek, hastalara periodontal ve ekonomik yararlar sağladığı gibi protetik yaklaşımlar yerine uygulanacak iyi bir alternatif tedavi seçeneği olarak gösterilebilir.³ Ön kesici dişlerde oluşan kron kırıkları kronun 2/3 ünü veya daha fazlasını kapsıyor ise, hastanın fazla overjeti ve parafonksiyonu varsa post sistemleri kullanılabilir.^{4,5} Post sistemleri, döküm ve prefabrike post kor olmak üzere iki temel şekilde sınıflandırılmakla birlikte, günümüzde metal olmayan, seramik ve fiber esaslı alternatif materyaller de yaygın olarak kullanılmaktadır.⁶ Bu post korlar, endodontik tedavi görmüş dişler için tercih edilebilir bir tedavi seçeneğidir, buna ek olarak non-metalik post sistemleri mükemmel estetik sonuçlar sağlamaktadır.⁷

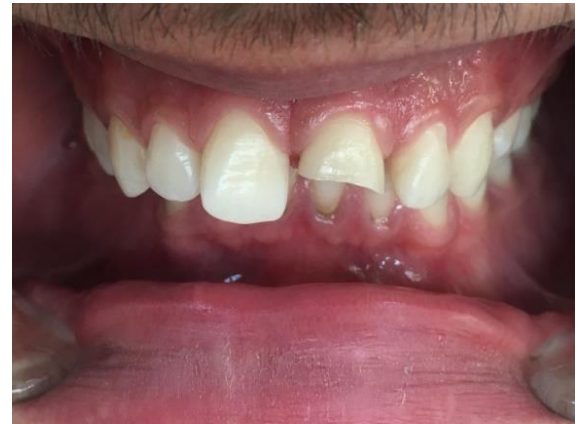Endodontik tedavi görmüş dişlerin mekanik dayanımlarıyla ilgili yapılan çalışmalarda fiber post sistemleri ile restore edilen dişlerin metal postlarla restore edilenlere oranla daha az kök kırığına neden olduğu bildirilmiştir.⁸⁻¹² Dentinin elastisite modülüne yakın elastisite modülüne sahip, daha az rijit materyallerin kullanımı, diş dokularının büyük kısmının kaybedildiği durumlarda yapılacak restorasyonların klinik başarısını artırmaktadır.¹³ Fiber postların fiziksel özellikleri dentine benzemektedir ve böylece dentine eşdeğer oranda esneyerek üzerindeki restorasyonun kırılma direncini artırmaktadır.¹⁴ Bu olgu sunumunun amacı, pulpayı içeren komplike kron kırığının, kanal tedavisi sonrası, fiber post ve direkt kompozit restorasyon ile rehabilitasyonunu anlatmaktır.

OLGU SUNUMU

14 yaşındaki erkek hasta, üst sol santral dişinde travmaya bağlı kırık şikayetiyle Cumhuriyet Üniversitesi Diş Hekimliği Fakültesi Restoratif Diş Tedavisi Anabilim Dalına başvurdu. Alınan anamnezde hastanın herhangi bir sistemik hastalığı ve alerjik probleminin olmadığı tespit edildi. Yapılan klinik ve radyolojik muayenede kırığın mine, dentin ve pulpayı içeren komplike bir kırık olduğu ve kanal tedavisinin tamamlanmış olduğu görüldü (Resim 1a, b).



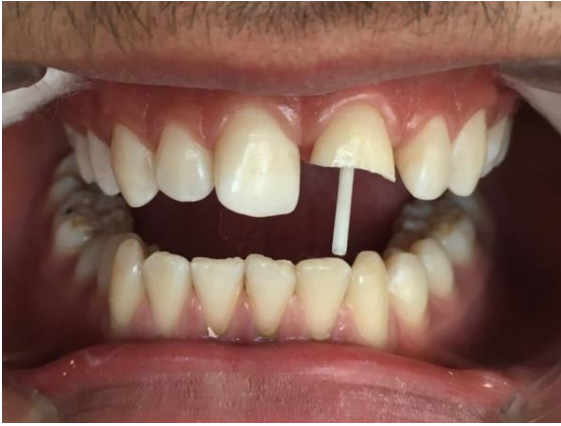Resim 1a. Tedavi öncesi ağız içi görünümü



Resim 1b. Tedavi öncesi ağız içi görünümü

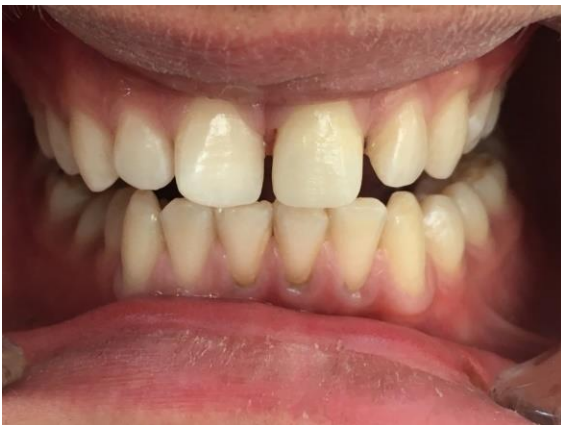Yapılacak restorasyon için diş renginin belirlenmesinin ardından, cam fiber postu (Glassix, Harald Nordin, Switzerland) yerleştirmek üzere, kök kanalındaki kanal dolgusunun yarısı post sisteminin frezleri yardımıyla boşaltıldı. Kanalın içi, dişin bizote edilmiş mine yüzeyi ve dentin kısımları %37'lik fosforik asit (3M ESPE Dental Products, St. Paul, ABD) ile asitlendi. Daha sonra kök kanalı dikkatlice yıkanıp kurutulduktan ve izolasyon sağlandıktan sonra gereken boyutta cam fiber

post bir bistüri ile kesilip kanal içerisinde denendi. Uygunluğuna karar verilen postun yüzeyine ve post boşluğuna aplikatör yardımıyla üniversal bağlayıcı ajan (3M Single Bond Universal, 3M ESPE St.Paul, MN, ABD) ayrı ayrı uygulandı ve 20'şer sn LED ışık cihazıyla (Woodpecker LED-B Işık cihazı, Guilin Woodpecker Medikal Endüstri, Ltd, Guangxi, Çin) polimerize edildi. Dual cure rezin siman (3M ESPE Relyx Ultimate, ABD) kanal içine üretici firmanın talimatlarına göre uygulandı. Fiber post kanala yerleştirildi ve 40 sn polimerize edildi (Resim 2).

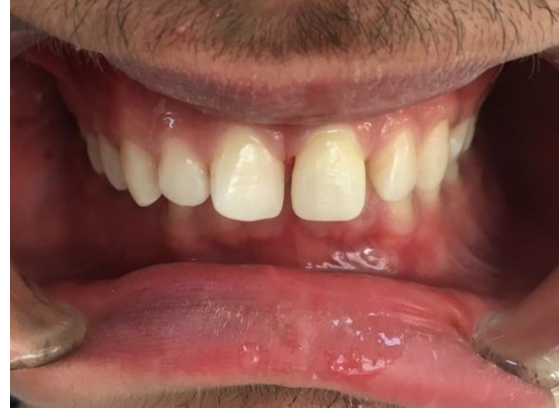

Resim 2. Cam fiber postun dişe uygulanması

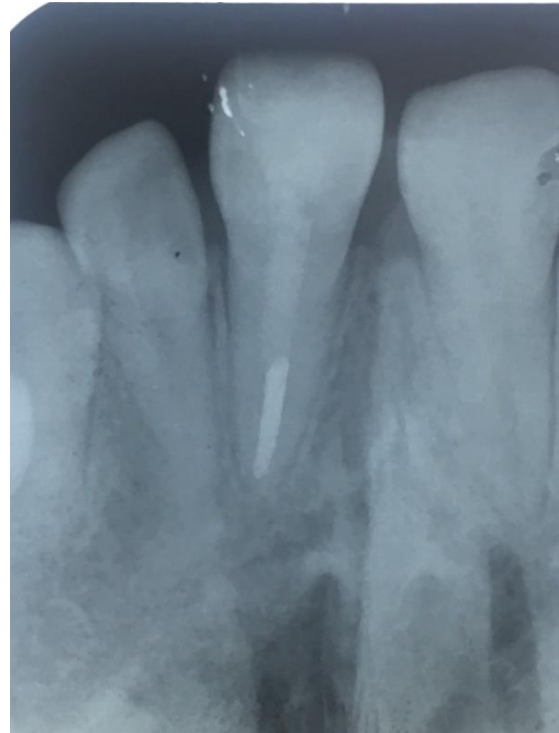Daha sonra kron kısmı direkt kompozit rezin uygulamasıyla (Shade A2D, A2E; 3M ESPE Filtek Ultimate, ABD) restore edildi. Kompozite uygun diş formu verilmesinin ardından restorasyon yüzeylerinin bitim ve cila işlemleri, alüminyum oksit disklerin (Soflex, 3M ESPE, MN, USA) kalın grenden ince grene doğru uygulanmasıyla tamamlandı (Resim 3a, b, Resim 4).



Resim 3a. Tedavi bitimi ağız içi görünümü



Resim 3b. Tedavi bitimi ağız içi görünümü



Resim 4. Tedavi bitimi dişin radyografik görünümü

TARTIŞMA

Dental travmatik yaralanmaların sıklıkla maksiller santral kesici dişlerde ortaya çıktığı bilinmektedir.¹⁵ Kron kırıkları, mine ve dentini içine alan kırıklar olarak tanımlanır ve pulpa dokusunun açılıp açılmamasına bağlı olarak komplike ve komplike olmayan kron kırıkları olarak sınıflandırılırlar. Bu tür kırıklarda tedavi yaklaşımını; kırığın tipi, yeri, düzeyi, durumun aciliyeti, tedavinin maliyeti ve kompleks oluşu belirlemektedir.¹⁶ Endodontik tedavi uygulanmış ve aşırı miktarda madde kaybına uğramış dişlerin protetik ve konservatif tedavilerinde yeterli koronal diş dokusunun bulunmaması, restorasyonları desteklemek için

kök desteğine ihtiyaç duyulmasına neden olmaktadır.¹⁷ Kron kırıklarında kronun 2/3 ya da daha fazlasını içine alıyorsa, bu tip dişlerin kökten destek alarak bir post sistemi ile restorasyonu önerilmektedir.^{18,19} Genç bireylerde travma sonucu madde kaybı fazla olan dişlerin restorasyonunda fiber postların kompozit rezinler ile kullanımı konservatif bir tedavi yaklaşımı olarak düşünülebilir. Fiber postların en önemli avantajlarından biri elastisite modülünün (16-40 GPa) dentinin elastisite modülüne (16,8 GPa) çok yakın olmasıdır.²⁰ Fiber postların elastisite modülünün dentinin elastisite modülüne çok yakın olduğu düşünülürse, dişte daha az stress yoğunluğu olacağı ve kök kırığı riskinin daha rijit olan metal postların kullanıldığı olgulara göre daha azalacağı açıktır.²¹⁻²³ Bu çalışmadakiolguda cam fiber post kullanılmıştır. Cam fiber postların en önemli avantajlarından birisi kökün ve diş etinin altından ışık geçirgenliğini artırarak üstün estetik özellik sağlamasıdır.²⁴ Bu gibi sebeplerden dolayı santral kesici diş restorasyonu için cam fiber post tercih edilmiştir. Retrospektif bir çalışmada post uzunluğunun en azından kron yüksekliğine eşit olan postlarla tedavi edilmiş dişlerde başarısızlık oranının %2,5 olduğu, kron uzunluğunun dörtte biri olan postların başarısızlık oranının ise %25 olduğu bildirilmiştir.²⁵ Bu düşüncelerden yola çıkarak, post yuvasının kökün yarısına kadar uzaklaştırılması tercih edilmiştir.

Kompozitlerin kabul edilebilir bir klinik özellikleri olmasına rağmen kırılma, yüzey pürüzlülüğü, mikrosızıntı, polimerizasyon büzülmesi ve aşınma direncinin düşük olması gibi dezavantajları vardır.²⁶ Polimerizasyon büzülmesi ve bunun sonucu olarak porözite kompozitin su emilim özelliğini etkileyebilmektedir.²⁷ Polimerizasyon büzülmesini en aza indirgeyebilmek için post üzerine kor ve diş şekillendirme aşamasında kompozit, tabakalama (inkremental teknik) yöntemiyle uygulanıp tavsiye edilen ışınlama sürelerine uyulup, yüzey bitirme işlemlerinin de

su emilimini önleme açısından önemli olabileceği²⁶ dikkate alınarak son aşamada oklüzyon kontrollerinden sonra polisaj işlemleri yapılarak restorasyon tamamlanmıştır. Cam fiber post sistemlerinin kompozit rezinler ile birlikte kullanılması, kalan kök yapısını sağlamlaştıran, krona aşırı madde kaybının yerine konulmasını ve hastanın bir an önce eski görünümüne kavuşturulmasını sağlayan konservatif bir tedavi seçeneğidir.²⁸

SONUÇ

Fiber post destekli direkt kompozit restorasyonlar, protetik tedavilere göre maliyeti daha düşük, fonksiyonel ve estetik olarak hasta memnuniyetinin sağlandığı bir tedavi türüdür. Bu olgu, cam fiber post ve kompozitin kombine tekniğinin, mükemmel estetik ve fonksiyonel sonuçlarla anterior travmatize dişlerin tedavisi için basit ve etkin bir prosedür olabileceğini göstermiştir.

KAYNAKLAR

1. Yanıkoğlu N, Bayındır F. Post-core yapımında kullanılan restoratif materyaller ve özellikleri. Atatürk Üniv Diş Hek Fak Derg 2003-2004;13-14:39-47.
2. Bilgin MS. Farklı post-core sistemlerinin iki farklı metod kullanılarak (Fraktür Analizi ve Sonlu Elemanlar Stres Analiz Yöntemi) değerlendirilmesi. Selçuk Ü Diş Hek Fak Doktora Tezi 2008.
3. Trope M, Langer I, Maltz D, Tornstad L. Resistance to fracture of restored endodontically treated premolars. Endod Dent Traumatol 1986;2:35-8.
4. Baretieri LN, Monteiro S Jr, Andrada MAC. Esthetics: Direct adhesive restorations on fractured anterior teeth. Chicago Quintessence Books 1998;135-205.
5. Baretieri LN, Monteiro S Jr, Andrada MAC. Tooth fracture reattachment. Case reports. Quintessence Int 1990;21:261-70.
6. Adanir N, Ok E, Erdek Y. Re-attachment of subgingivally oblique fractured central incisor using a fiber post. Eur J Dent 2008;2:138-41.

7. Fernandes AS, Shetty S, Coutinho I. Factors determining post selection: a literature review. *J Prosthet Dent* 2003;90:556–62.
8. Sirimai S, Riis DN, Morgano SM. An in vitro study of the fracture resistance and the incidence of vertical root fracture of pulpless teeth restored with six post-and-cores systems. *J Prosthet Dent* 1999;81:262-9.
9. Saupe WA, Gluskin AH, Radke RA Jr. A comparative study of fracture resistance between morphologic dowel and cores and a resin-reinforced dowel system in the intraradicular restoration of structurally compromised roots. *Quintessence Int* 1996;27:483-91.
10. Fokkinga WA, Kreulen CM, Le Bell-Rönnlöf AM, Lassila LV, Vallittu PK, Creugers NH. Fracture behavior of structurally compromised non-vital maxillary premolars restored using experimental fiber reinforced composite crowns. *Am J Dent* 2006;19:326-32.9.
11. Hayashi M, Takahashi Y, Imazato S, Ebisu S. Fracture resistance of pulpless teeth restored with post-cores and crowns. *Dent Mater* 2006;22:477-85.
12. Zappini G, Bianchetti M. Finite element analysis of a glass fibre reinforced composite endodontic post. *Biomaterials* 2002;23:2667-82.
13. Ferrari M, Vichi A, Garcia Godoy F. Clinical evaluation of fiber reinforced epoxy resin posts and cast posts and cores. *Am J Dent* 2000;13:15b-18b.
14. Freilich MA, Meiers JC, Duncan JP, Goldberg AJ. *Fiber-Reinforced Composites in clinical dentistry*. Quintessence Publishing Co 2000;9-22.
15. Alaçam, T. *Endodonti*. G.Ü. Basın-Yayın Yüksekokulu Basımevi, Ankara, 1990.
16. Andreasen JO, Andreasen FM. Crown-root fractures. In: Andreasen JO, Andreasen FM *Textbook and Color Atlas of Traumatic Injuries to The Teeth*. Copenhagen: Munksgaard Publishers 1994;257-77.
17. Morgano SM, Milot P. Clinical success of cast metal post and cores. *J Prosthet Dent* 1993;70:11-6.
18. Garoushi SK, Lassila LV, Vallittu PK. Direct composite resin restoration of an anterior tooth: effect of fiber-reinforced composite substructure. *Eur J Prosthodont Restor Dent* 2007;15:61-6.
19. Özdemir E, Ağuloğlu S. [A crown restoration of fiber reinforced composite which is supported from the root canal]. *Türkiye Klinikleri J Dental Sci* 2006;12:123-6
20. Boschian Pest L, Cavalli G, Bertani P, Gagliani M. Adhesive post-endodontic restorations with fiber posts: push-out tests and SEM observations. *Dent Mater* 2002;18:596-602.
21. Mannocci F, Innocenti M, Ferrari M, Watson TF. Confocal and scanning electron microscopic study of teeth restored with fiber posts, metal posts, and composite resins. *J Endod* 1999;25:789-94.
22. Möllersten L, Lockowandt P, Lindén LA. A comparison of strengths of five core and post-and-core systems. *Quintessence Int* 2002;33:140-9.
23. Raygot CG, Chai J, Jameson DL. Fracture resistance and primary failure mode of endodontically treated teeth restored with a carbon fiber-reinforced resin post system in vitro. *Int J Prosthodont* 2001;14:141-5.
24. Purton DG, Chandler NP, Qualtrough AJ. Effect of thermocycling on the retention of glassfiber root canal posts. *Quintessence Int* 2003;34:366-9.
25. Sorensen JA, Martinoff JT. Clinically significant factors in dowel design. *J Prosthet Dent* 1984;52:28-35.
26. Bulucu B, Sevilmiş HH, İnan U. Kompozit rezinlerde farklı yüzey bitirme işlemlerinin su emilimi üzerine etkileri. *OMÜ Dişhek Fak Derg* 2004;5:75-9.
27. Kalachandra S, Wilson TW. Water sorption and mechanical properties of light-cured proprietary composite tooth restorative materials. *Biomaterials* 1992; 13,105-9.

28.Sarı ME, Külünk T, Koyutürk AE. [The restoration of crown fractures in anterior teeth with fiber post and composite resin: 3 cases report]. J Dental Faculty of Atatürk University 2007:51-4.

Sorumlu Yazar

Arş. Gör. Dt. Seda ÖZKANOĞLU

Cumhuriyet Üniversitesi

Diş Hekimliği Fakültesi

Restoratif Diş Tedavisi ABD

58140 Merkez/Sivas Türkiye

Tel : +90 5315772197

Fax : +90 346 219 12 37

E-mail : sedaozkanoglu1@gmail.com