






## INDISCRIMINATE USE OF SMOKELESS TOBACCO LEADING TO ORAL CANCER AT A YOUNG AGE; A CASE REPORT WITH LITERATURE REVIEW ON TOBACCO CONSUMPTION

### ABSTRACT

Oral Squamous cell carcinoma (OSCC) constitutes the sixth most common cancer in world. Oral cancer is known as an elderly disease mostly occurring between the 5<sup>th</sup> and 8<sup>th</sup> decades of life. It is mainly attributed to the use of tobacco and alcohol. Only 1-6% of OSCC is reported to occur below 40 years of age. This report describes a rare occurrence of OSCC in a 35 year old male patient, with a disproportionate history of tobacco chewing since the age of 14years; and literature review about tobacco use among younger generation.

**Keywords:** Oral squamous cell carcinoma, smokeless tobacco, tobacco, young adolescents.

 \*Sajad Ahmad BUCH<sup>1</sup>  
 Subhas G BABU<sup>2</sup>  
 Shruthi RAO<sup>2</sup>

ORCID IDs of the authors:

S.A.B. 0000-0002-1241-4679

S.G.B. 0000-0001-9383-7886

S.R. 0000-0003-3138-6455

<sup>1</sup> Department of Oral Medicine & Radiology, Yenepoya Dental College, Yenepoya (Deemed to be) University, Mangalore, 575018 Karnataka-India.

<sup>2</sup> Department of Oral Medicine & Radiology, AB Shetty Memorial Institute of Dental, Sciences, NITTE (Deemed to be University), Mangalore, 575018 Karnataka-India.

**Received** : 16.07.2019

**Accepted** : 10.09.2019

**How to Cite:** Buch SA, Babu SG, Rao S. Indiscriminate Use of Smokeless Tobacco Leading to Oral Cancer at A Young Age; A Case Report with Literature Review on Tobacco Consumption. Cumhuriyet Dent J 2019;22:4

**\*Corresponding Author:**

Department of Oral Medicine & Radiology, Yenepoya Dental College, Yenepoya (Deemed to be University), Mangalore, 575018 Karnataka-India.

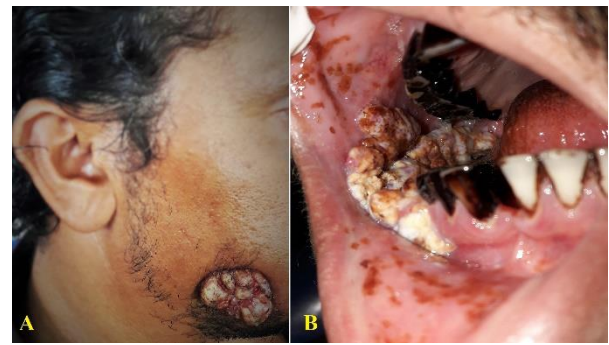**Phone:** +91 789 946 63 46 **Email:** [buchh.sajad@gmail.com](mailto:buchh.sajad@gmail.com)

## INTRODUCTION

Squamous cell carcinoma (SCC) comprises of more than 90% of all malignancies affecting the region of head and neck, and occurs during 5<sup>th</sup> to 8<sup>th</sup> decades of life.<sup>1</sup> OSCC rarely affects people below the age of 40 years; with a consistency of only 1-6% when affecting this age group.<sup>2</sup> OSCC has been predominantly seen in males. It commonly affects the tongue most with a site predilection for its posterior and lateral border.<sup>3</sup> This is followed by lips, floor of the mouth, soft palate, gingiva and buccal mucosa.<sup>2,4</sup> OSCC epidemiology depends greatly on the risk factors. The major risk attributes in the older age groups comprise of tobacco and betel quid use along with synergetic effect of alcohol consumption.<sup>5</sup> In India the cancer of gingivo-buccal complex (alveolar mucosa, buccal mucosa and gingival-buccal sulcus) forms the most common site for oral cancer while the tongue and the floor of the mouth constitute the most frequent sites for oral cancer in the western world.<sup>6</sup> This difference can be attributed to the tobacco habits; In India chewing tobacco habits being more common as compared to the smoking forms in the western world. This case report reinforces tobacco etiology underlying OSCC, with description of a 35 year old adult who had a history of indiscriminate tobacco chewing habits for around 20 years.

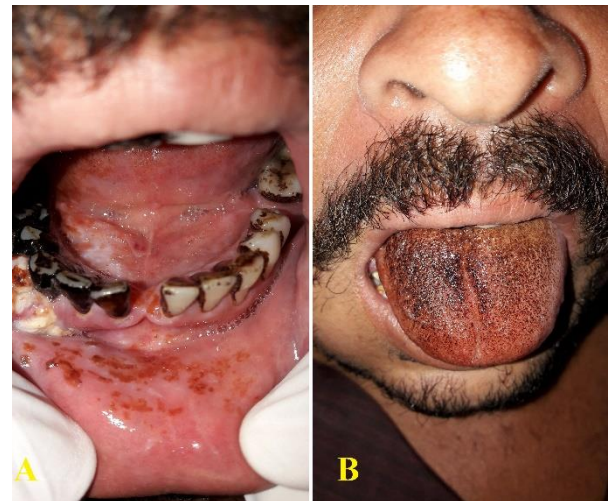## CASE REPORT

A 35-year-old male patient was referred from the department of Otolaryngology for prophylactic dental treatment before a definitive treatment plan for his buccal OSCC could be instituted. The patient was a known case of OSCC of right buccal mucosa. The patient had a history of tobacco and paan chewing since the age of 14 years. Extra oral examination of the patient revealed an ulceroproliferative growth of around 3cmx3cm on right side of the face (Figure 1A). The growth was non tender and presence of induration was confirmed. Upon intra oral examination a large ulceroproliferative growth around 7cm x 3cm was seen on right buccal mucosa extending from the commissure to the right retro molar region (Figure 1B).



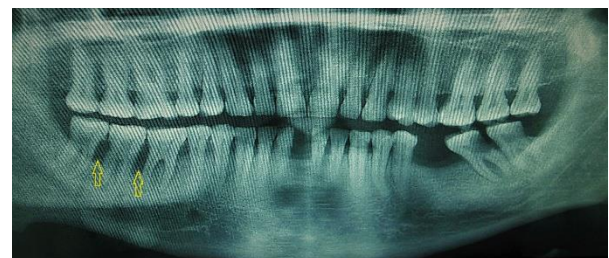**Figure 1A,** Extra-oral ulceroproliferative growth on right cheek.  
**Figure 1B.** Intra oral image showing extensive involvement of right buccal mucosa with a large proliferative growth.

It was slightly tender and indurated. Extensive generalised tobacco/ paan stains could be seen on all the teeth and mucosal surfaces in oral cavity more so on right side than the left (Figure 2A) and over the entire tongue (Figure 2B).



**Figure 2A.** Massive tobacco/paan stains particularly on right side of mouth  
**Figure 2B.** Tobacco/paan stains covering whole of the dorsal surface of tongue.

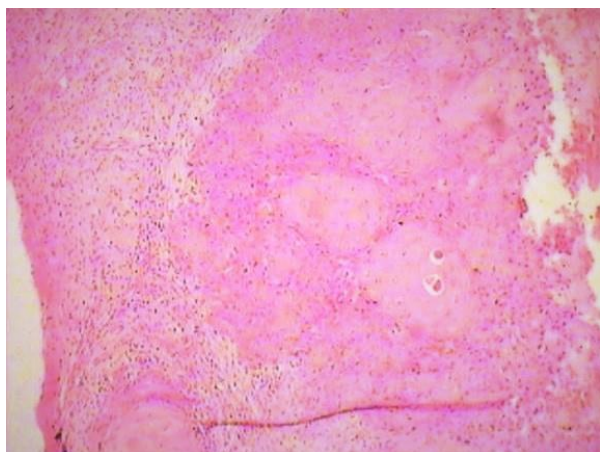Panoramic radiograph revealed generalised interdental bone loss with grossly decayed tooth number 37 (Figure 3).



**Figure 3.** Cropped panoramic radiograph showing extent of bone loss. –Yellow arrows.

There was extensive bone loss with respect to teeth number 46, 47 & 48. The sections used for histopathological assessment in Hematoxylin and Eosin showed dysplastic epithelium proliferating

into connective tissue in the form of sheets and islands (Figure 4).



**Figure 4.** Histopathological slide confirming the diagnosis of oral squamous cell carcinoma.

The features revealed nuclear hyperchromatism, altered nuclear cytoplasmic ratio, individual cell keratinization and keratin pearl formation. Connective tissue showed collagen fibre bundles, chronic inflammatory cells like lymphocytes and plasma cells, muscle fibres, adipose tissue, blood vessels and extravasated RBCs. Extraction of teeth numbers 37, 46, 47 and 48 was carried out followed by thorough periodontal evaluation. The patient was referred back to the department of Otolaryngology for definitive treatment of OSCC after ruling out any further source of infection.

## DISCUSSION

OSCC affects mostly elderly to an extent of 91% and much lower in younger individuals with a range of 0.4 to 3.6%.<sup>7</sup> As is evident from the figures the occurrence of OSCC is not a common finding in young people. OSCC patients are categorised as young if they fall below the age of 40 years, with some authors suggesting the age range as between 20 to 30 years. The age of the patient in present case report was only 35 years. The lateral border of tongue is the most common site for OSCC in patients younger than 40 years; which is similar to OSCC cases among elderly. Our case shows OSCC in buccal mucosa and the reason for the same was exclusive unilateral tobacco chewing habit, with placement of the tobacco in the right mucobuccal fold. The unilateral chewing habit was evident in this case with comparative absence of staining and encrustations on the left side of the oral cavity. In young OSSC patients the

chances of cause effect relationship of tobacco products is quite low due to relatively shorter exposure time. The current case though resembles those of elderly patients with habits, as the patient had a long history of tobacco chewing of around 20 years. This factor exposes the vulnerability of children to the harmful and dangerous culture of our society. The World Bank reports nearly around 99,000 new cases of children and adolescents start smoking habits/day around the world. Reports estimate 5500 adolescents acquire tobacco habits every day in India and add on to the 4 million young tobacco users under the age of 15 years. The children have been victims of easy availability of tobacco products in the Indian markets. India being the second most populous nation in the world, tobacco products have been shown to be prevalent among young boys in the society. India is considered as the second largest consumer and third largest producer of the tobacco products around the globe. In a survey reported among 13-15 year old children nearly 50% reported having first experience of tobacco chewing before the age of 10 years.<sup>8</sup> There are number of tobacco forms available notable among them being, cigarettes, bidi and smokeless tobacco (SLT). SLT does not need to be lit for consumption and is consumed either nasally or placed directly in the mouth. The use of various forms depends on the regional preferences. According to Global Adult Tobacco Survey 2 (GATS-2) 28.6% of the population consume different forms of tobacco, 21.4% use SLT and 10.7% smoke.<sup>9</sup> Tobacco quid chewing leads to six times more risk for oral cancer.<sup>10</sup> India has highest number of oral cancer cases in the world due to SLT use.<sup>11</sup> It is estimated that SLT causes around 50% of all the oral cancer cases. The present case similarly had only tobacco chewing habit with no history of cigarette or bidi smoking. India constitutes the largest global market of SLT (164 million), followed by smokers only (69 million) and having an additional population of 42 million who use both the SLT and the smoked forms.<sup>12</sup> SLT is available in numerous forms namely Naas, Mawa, Gadakhu, Zarda, Betel quid, Paan, Mishri.<sup>13</sup> People in rural areas of India particularly the womenfolk believe SLT as a source of energy and hunger suppressant, as majority of

them depend on hard labour for meagre earnings.<sup>14</sup> The present case belonged to a far flung rural area and was an unskilled worker, spending most of the time farming in other people's land. A disorder of addiction, tobacco use mostly begins during childhood and adolescence. The addictions begins due a myriad of psychosocial factors, like family history of tobacco use, experimentation, influence from peers, easy availability, personality factors, emotional, and psychological issues.<sup>15</sup>

### **CONCLUSIONS**

Application of present policies should be scrutinised particularly in respect to tobacco sales and children purchasing tobacco products. The retail transaction of tobacco products should be banned. Habit counselling should be made mandatory on primary health care level and regional disparities (habit related) should be kept in mind when developing any tobacco counselling programmes. Intense efforts are the need of the hour to target youth for tobacco cessation.

### **ACKNOWLEDGEMENTS**

The authors declared that this manuscript received no financial support.

### **CONFLICT OF INTEREST STATEMENT**

The authors have no conflict of interest to declare.

### **REFERENCES**

1. Kaur J, Singh A, Chopra R. Unusual presentation of squamous cell carcinoma in young female patient: A case report and review of literature. *J Oral Maxillofac Pathol* 2016; 20:163.
2. Hirota SK, Migliari DA, Sugaya NN. Oral squamous cell carcinoma in a young patient – Case report and literature review. *An Bras Dermatol* 2006; 81:251-254.
3. Alohalali AM. Can Squamous cell carcinoma affect young healthy adults? Case report of oral squamous cell carcinoma of the tongue in 19-year-old female. *Oral Health Care* 2017; 2:1-3.
4. Binahmed A, Charles M, Campisi P, Forte V, Carmichael RP, Sandor GK. Primary squamous cell carcinoma of the maxillary alveolus in a 10-year-old girl. *J Can Dent Assoc* 2007; 73: 715-718.

5. Sankaranarayanan R, Mohideen MN, Nair MK, Padmanabhan TK. Aetiology of oral cancer in patients less than or equal to 30 years of age. *Br J Cancer* 1989; 59: 439-440.
6. Tandon P, Dadhich A, Saluja H, Bawane S, Sachdeva S. The prevalence of squamous cell carcinoma in different sites of oral cavity at our Rural Health Care Centre in Loni, Maharashtra - a retrospective 10-year study. *Contemp Oncol (Pozn)* 2017;21:178-183.
7. Beena VT, Binisree SS, Ayswarya T, Paikkadan I, Padmakumar SK, Sivakumar R. Oral Squamous Cell Carcinoma in Patients Younger than 40 Years: A 10 Year Retrospective Study. *Int J Sci Stud* 2016; 4:150-153.
8. Sinha DN, Reddy KS, Rahman K, Warren CW, Jones NR, Asma S. Linking Global Youth Tobacco Survey (GYTS) data to the WHO framework convention on tobacco control: The case for India. *Indian J Public Health* 2006; 50:76-89.
9. Mohan P, Lando H A, Panneer S. Assessment of tobacco consumption and control in India. *Indian J Clin Med* 2018; 9:1-8.
10. Dixit PR, Kanhere S. Tobacco habits and risk of lung, oropharyngeal and oral cavity cancer: a population based case-control study in Bhopal, India. *Int J Epidemiol* 2000; 29: 609-614.
11. Mohan P, Lando H. Oral tobacco and mortality in India. *Indian J Clin Med* 2016; 7:5-12.
12. Koothati RK, Reddy GV, Ramlal G, Prasad LK, Kumar VJ, Pokala A. An epidemiological study of tobacco-related oral habits in Mahabubnagar district of Telangana, India. *J Indian Acad Oral Med Radiol* 2017; 29:205-208.
13. Niaz K, Maqbool F, Khan F, Bahadar H, Ismail Hassan F, Abdollahi M. Smokeless tobacco (paan and gutkha) consumption, prevalence, and contribution to oral cancer. *Epidemiol Health* 2017; 39: e2017009.
14. Nair S, Schensul JJ, Begum S, Pednekar MS, Oncken C, Bilgi SM, et al. Use of smokeless tobacco by Indian women aged 18-40 years during pregnancy and reproductive years. *PLoS One* 2015; 10: e0119814.
15. Kumar A, Tiwari A, Gadiyar A, Gaunkar RB, Kamat AK. Assessment of readiness to quit tobacco among patients with oral potentially malignant disorders using trans theoretical model. *J Educ Health Promot.* 2018; 7:9.