



PYOGENIC GRANULOMA OF THE INCISIVE PAPILLA: A RARE CASE REPORT

ABSTRACT

Pyogenic granuloma is a non-neoplastic reactive growth commonly found in the oral cavity and skin. It is benign in origin and may arise due to factors like trauma, local minor irritation and an imbalance in the levels of hormones. Oral pyogenic granuloma occurs commonly in young females in second decade of their life possibly due to hormonal influences leading to changes in the vascular system. Oral pyogenic granuloma presents itself as a smooth or lobulated growth, mostly pedunculated but occasionally with a sessile growth. The colour of pyogenic granuloma may vary from pink, red and purple and this variation in colour is related to the age of the lesion. Clinically the most common site for oral pyogenic granuloma is gingiva, lips, tongue and buccal mucosa. This report presents a unique location for oral pyogenic granuloma at incisive papilla. Palatal pyogenic granuloma is rarely reported.

Key words: Oral, gingiva, pyogenic granuloma, pregnancy, incisive papilla.

 Renita Lorina Castelino¹
 Kumuda Rao¹
 Sajad Ahmad Buch²
 Supriya Bhat¹
 Subhas G Babu¹
 Devika S Pillai¹

ORCID IDs of the authors:

R.L.C. 0000-0002-8696-549X
K.R 0000-0002-6214-1381
S.A.B. 0000-0002-1241-4679
S.B. 0000-0002-4380-0214
S.G.B. 0000-0001-9383-7886
D.S.P. 0000-0001-7549-6395

¹ Department of Oral Medicine & Radiology, AB Shetty Memorial Institute of Dental Sciences, NITTE (Deemed to be University), Mangalore, Karnataka, India

² Department of Oral Medicine & Radiology, Yenepoya Dental College, Yenepoya (Deemed to be University), Mangalore, Karnataka, India

Received : 08.02.2019
Accepted : 03.04.2019

INTRODUCTION

Several soft tissue enlargements can occur in the oral cavity and often present a diagnostic challenge. Such enlargements in the oral cavity may indicate a developmental anomaly, adaptation of a normal structure, cysts, inflammation and neoplasms. One of the most common among oral soft tissue enlargements is pyogenic granuloma, a reactive hyperplasia that appears secondary to either a hormonal change, trauma, a minor local irritation or sometimes due to certain drugs. The term pyogenic granuloma is a double misnomer for the lesion as it neither contains pus nor represents a granuloma in true sense. The first case of pyogenic granuloma was reported in 1884 by Hullihen and although several names have been proposed, its current term i.e., pyogenic granuloma was coined by Hartzell in 1904.¹

Oral Pyogenic granuloma can appear at any age and most commonly results due to irritation from calculus, overhanging restoration or a foreign object in gingival crevice.² It also occurs commonly in mucosa of females who have elevated steroid hormones, and these hormones are believed to play a vital role in pathogenesis of oral pyogenic granuloma.³ Gingiva accounts for nearly 75% of all oral pyogenic granulomas. The other common locations being lips, tongue and buccal mucosa and on rare occasions the palate.⁴ The treatment of choice for oral pyogenic granuloma is surgical excision. The recurrence rate of 16% is attributed to incomplete excision, persistent etiological factors or continued trauma⁵, therefore, to avoid recurrences any potential irritants should be completely removed at the time of surgical intervention.

CASE REPORT

A female patient aged 32 years reported to the department of oral medicine and radiology with a chief complaint of growth behind the upper front teeth for 2 years. The growth was initially small and gradually increased to the present size. The patient also gave history of difficulty during speech. The patient gave history of occasional bleeding from the area especially while brushing. No relevant dental and medical history was

reported by the patient. On general examination no abnormalities were detected. On intra oral examination, well-defined mass reddish pink in colour was noticed in the anterior palatal region posterior to 11 and 21, measuring approximately 3x2 cm in size (Fig 1).

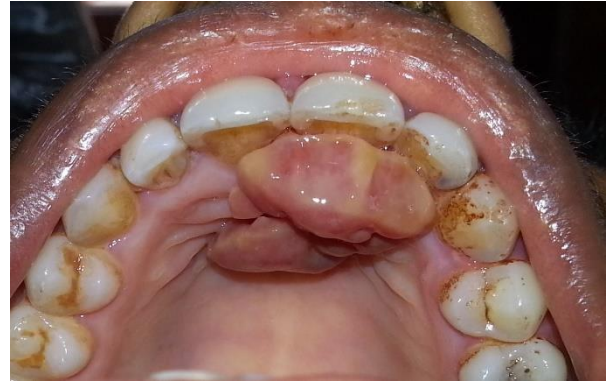

Figure 1: Clinical photograph of the patient showing a growth on the anterior palate

On reflection with a periodontal probe, the mass appeared to be pedunculated and attached to the incisive papilla (Fig 2).

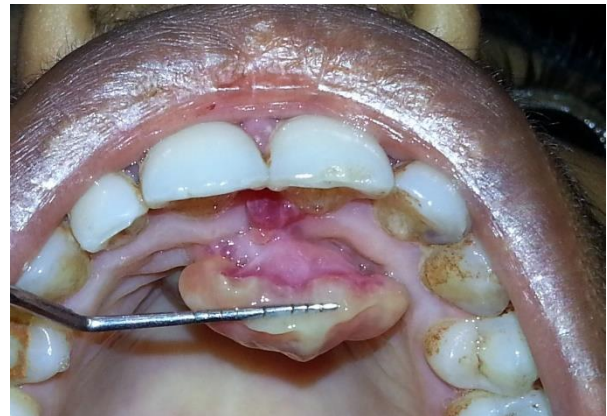

Figure 2: Clinical photograph of the patient showing growth arising from the incisive papilla

The mass was firm in consistency and non-tender. No other abnormalities were detected intra orally. Based on these findings a provisional diagnosis of pyogenic granuloma was made. The differential diagnosis of fibroma, peripheral ossifying fibroma and peripheral giant cell granuloma were considered.

An intra-oral periapical radiograph was made of 11, 21 region which showed generalised horizontal bone loss interdentially along with rarefaction in between 11 and 21 suggestive of localised periodontitis (Fig 3).

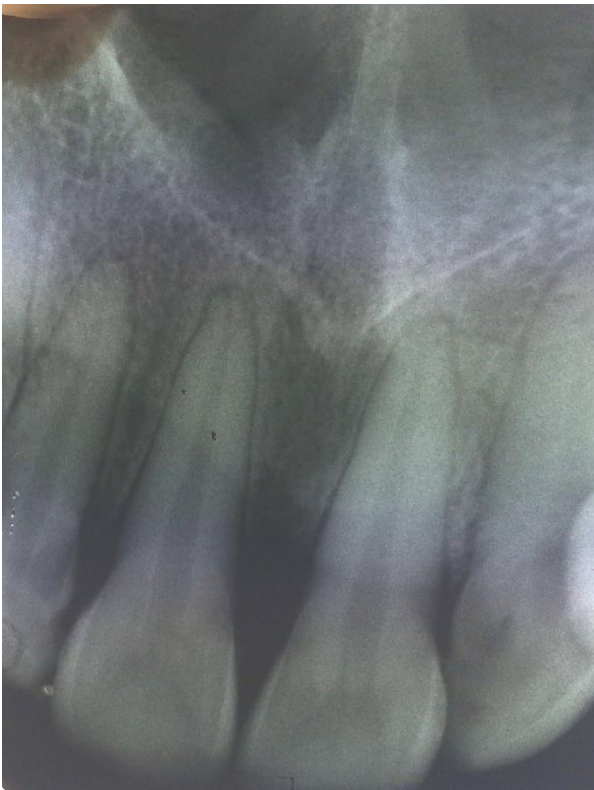

Figure 3: Intra oral periapical radiograph showing bone loss

The mass was surgically excised (Fig 4) with sutures in place under local anaesthesia followed by histopathology investigation.

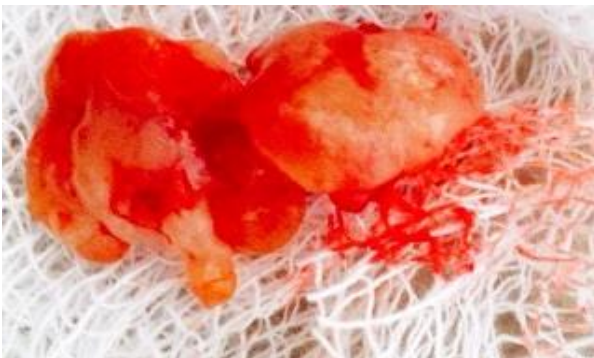

Figure 4: Clinical photograph of the excised lesion

The Haematoxylin & Eosin stained section showed epithelium and connective tissue. The epithelium was stratified squamous parakeratinized type showing surface ulceration at few areas and hyperkeratinisation. The connective tissue was composed of numerous blood vessels and proliferating blood capillaries lined by endothelium in a background of dense bundles of collagen fibres, fibroblasts and dense inflammatory infiltrate consisting mainly of lymphocytes, neutrophils, plasma cells and few mast cells. Few extravasated RBCs were also seen (Fig 5a and b).

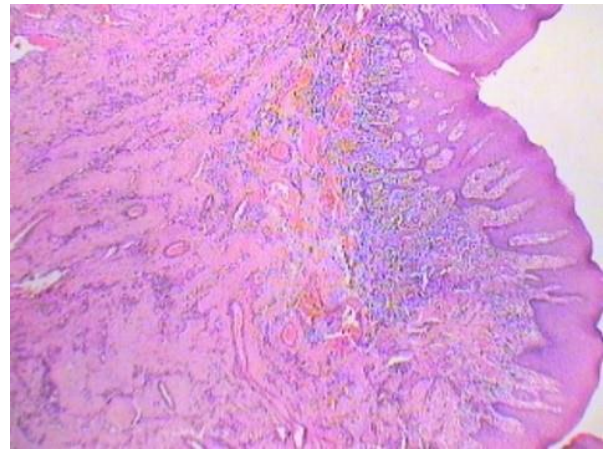


Figure 5a: H&E Staining (40x) Shows stratified squamous parakeratinized epithelium along numerous with proliferating blood capillaries in the underlying connective tissue.

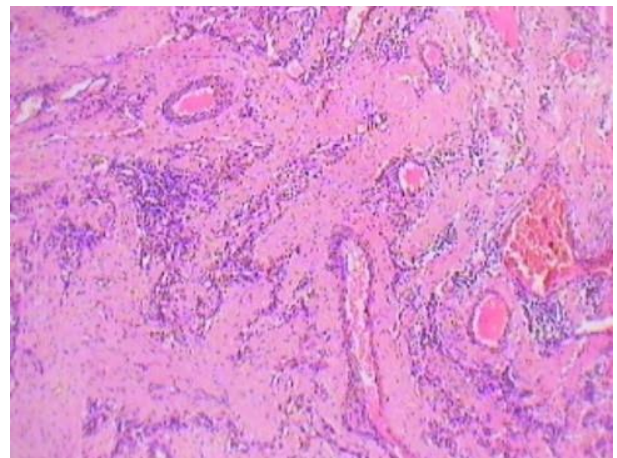


Figure 5b: H&E Staining (100x) shows proliferating and budding blood capillaries lined by endothelium.

A confirmed diagnosis compatible with the clinical diagnosis of pyogenic granuloma was made. The patient was followed up for 2 months and no recurrence was noted.

DISCUSSION

Pyogenic granuloma, a benign vascular lesion is also called as lobular capillary hemangioma and occurs due to inflammatory hyperplasia of skin or mucosa.⁶ Oral pyogenic granuloma is either pedunculated or sessile and can present with an appearance of smooth or lobulated surface. The lesion can occur at any age but is frequently seen in the third decade of life, with a predilection of 1.5:1 in favour of the females.⁷ The oral pyogenic granuloma occurs more in the maxilla than the mandible with most of the cases seen in the anterior region, involving buccal side more than the lingual.⁵ Oral pyogenic granuloma usually has a painless and slow growth but on occasions may grow fast till its full size and thereby remains stable. Initially the lesions are more vascular,

bleed easily and are often elevated and ulcerated and later become collagenized and turn pinkish.² The size of this benign vascular lesion, which presents either as a papule or nodule, is usually in millimetres but sizes more than 1 centimetre have also been witnessed in the reported literature.⁸ Oral pyogenic granuloma mostly occurs on gingiva, making around 75% of this variant. It usually manifests as a red and purple nodule originating from the interdental gingiva, occasionally with a fibrinopurulent layer covering an ulcer. Among the most common extra gingival locations, namely lips, tongue, palate, buccal mucosa and floor of the mouth, its palatal location is only rarely seen. The incisive papilla location for an oral pyogenic granuloma is even rarer among common extra gingival locations and hence makes the present case report a unique case. Although the precise etiology is still not clear, local trauma is an underlying factor in up to 50% of cases, the other frequently reported factors include infection, poor oral hygiene and hormonal imbalance.⁹ Estrogen receptors seen on epithelial mucosa of women may predispose them to the development of oral pyogenic granuloma.¹⁰ Few drugs (e.g., Isotretinoin, oral contraceptives), bacteria, viruses, primary dentition injury, aberrant tooth development and even eruption of teeth could lead to oral pyogenic granuloma.⁵

Oral pyogenic granuloma has two histopathological variations, Lobular Capillary Hemangioma (LCH) and non-LCH. The LCH type shows lobular collections of proliferating blood vessels, although superficially there is no specific change in the lesion including capillary dilation, edema or inflammatory granulation reaction in the tissues.¹¹ The non-LCH type has abundant vascular proliferation resembling granulation tissue.¹² Oral pyogenic granuloma should be differentially diagnosed with peripheral ossifying fibroma, peripheral giant-cell granuloma, conventional granulation tissue, hemangioma, and hyperplastic gingival inflammation.⁹ On occasions differential diagnosis may include malignant lesions, like melanotic melanoma, metastatic carcinoma, or non-Hodgkin's lymphoma.¹³ Oral pyogenic granuloma

being a benign lesion is successfully treated with surgical excision. The lesion can be treated non-surgically by suture ligation, cryotherapy, pulsed dye laser or CO₂ laser, sclerotherapy, cryotherapy or electrocauterization.¹⁴ Steroid injections have also been used (e.g., Triamcinolone acetonide), and is advocated particularly for recurrent cases after failed surgical methods.¹⁵ We managed our case with conventional surgical technique depending upon enough access and least number of recurrences reported with the surgical approach. The patient in this case report was followed for 2 months with no evidence of any relapse.

CONCLUSIONS

Oral pyogenic granuloma occurs on gingiva in about 75% of cases. Among extra-gingival sites, the palate is a unique location for this lesion. Any potential source of irritation should be dealt with while designing the treatment strategy for successful treatment of this lesion.

ACKNOWLEDGEMENTS

None

CONFLICTS OF INTEREST STATEMENT NIL

REFERENCES

1. Ganesan A, Kumar N G, Azariah E, Asokan G S. Oral pyogenic granuloma: A case report and a comprehensive review. *SRM J Res Dent Sci* 2015; 6:250-256.
2. Khaitan T, Sinha R, Sarkar S, Kabiraj A, Ramani D, Sharma M. Conservative approach in the management of oral pyogenic granuloma by sclerotherapy. *J Indian Acad Oral Med Radiol* 2018; 30:46-51.
3. Verma PK, Srivastava R, Baranwal HC, Chaturvedi TP, Gautam A, Singh A. "Pyogenic granuloma - Hyperplastic lesion of the gingiva: case reports". *Open Dent J.* 2012; 6:153-156.
4. Greenberg MS, Glick M, Jonathan A. 11th ed. Hamilton: BC Decker; *Burket's Oral Medicine*; 2008;133-134.
5. Hasanoglu Erbasar GN, Senguven B, Gultekin SE, Cetiner S. Management of a Recurrent Pyogenic Granuloma of the Hard Palate with Diode Laser: A Case Report. *J Lasers Med Sci.* 2016; 7:56-61.

6. Parajuli R, Maharjan S. Unusual presentation of oral pyogenic granulomas: a review of two cases. *Clin Case Rep.* 2018;690-693.
7. Mahabob N, Kumar S, Raja S. Palatal pyogenic granuloma. *J Pharm Bioallied Sci.* 2013;5: S179-181.
8. Arunmozhi U, Priya RS, Kadhiresan R, Sujatha G, Shamsudeen SM. A Large Pregnancy Tumor of Tongue - A Case Report. *J Clin Diagn Res.* 2016;10: 10-12.
9. Tenore G, Mohsen A, Pompa G, Brauner E, Cassoni A, Valentini V, Plimeni A, Romeo A. Gingival Reactive Lesions in Orally Rehabilitated Patients by Free Revascularized Flap. *Case Rep Dent* 2018; 2018:2474706.
10. Whitaker SB, Bouquot JE, Alimario AE, Whitaker TJ Jr. Identification and semiquantification of estrogen and progesterone receptors in pyogenic granulomas of pregnancy. *Oral Surg Oral Med Oral Pathol* 1994; 78:755-760.
11. Miller SE, Cooper PH, Fechner RE. Lobular capillary hemangioma: the underlying lesion of pyogenic granuloma. A study of 73 cases from the oral and nasal mucous membranes. *Am J Surg Pathol* 1980; 4:470-479.
12. Jafarzadeh H, Sanatkhani M, Mohtasham N. Oral pyogenic granuloma: A review. *J Oral Sci* 2006; 48:167-175.
13. Fekrazad R, Nokhbatolfoghahaei H, Khoei F, Kalhori K A. Pyogenic granuloma: surgical treatment with Er:YAG laser. *J Lasers Med Sci.* 2014; 5:199-205.
14. Flowers RH, Maglione J, Wilson BB. Removing Pyogenic Granulomas: A Simple and Effective Surgical Technique. *Clin Pediatr.* 2015; 54:1003-1005.
15. Bugshan A, Patel H, Garber K, Meiller TF. Alternative Therapeutic Approach in the Treatment of Oral Pyogenic Granuloma. *Case Rep Oncol.* 2015; 8:493-497.