




## PERIPHERAL GIANT CELL GRANULOMA AT AN EARLY AGE: 2 YEAR CASE FOLLOW-UP


### ABSTRACT

Peripheral giant cell granuloma (PGCG) is a lesion which can be seen in all age groups and observed in the gingival and alveolar crest regions of the oral cavity. Although it is rare in children, it may show an aggressive character and cause pain, bleeding, localized swelling and displacement of teeth. The treatment and 2-year follow-up of a 6-year-old girl with PGCG is presented in this case report.

**Keywords:** Granuloma, giant cell, surgery, excision, child

 \*Alem Coşgun<sup>1</sup>,

 Halenur Altan<sup>2</sup>,

 Ahmet Altan<sup>3</sup>

ORCID IDs of the authors:

<https://orcid.org/0000-0001-6586-6700>

<https://orcid.org/0000-0003-3648-5989>

<https://orcid.org/0000-0003-2041-6364>

<sup>1</sup> Kayseri Nimet Bayraktar Oral and Dental Health Hospital, Clinic of Pediatric Dentistry, Kayseri, Turkey.

<sup>2</sup> Department of Pediatric Dentistry, Faculty of Dentistry, Gaziosmanpaşa University, Tokat, Turkey.

<sup>3</sup> Department of Oral and Maxillofacial Surgery, Faculty of Dentistry, Gaziosmanpaşa University, Tokat, Turkey.

**Received** : 04.12.2018

**Accepted** : 02.01.2019

**How to Cite:** Coşgun A, Altan H, Altan A. Peripheral Giant Cell Granuloma at an Early Age: 2 Year Case Follow-Up. Cumhuriyet Dent J 2019;22:1:140-145.

**\*Corresponding Author**

Kayseri Nimet Bayraktar Oral and Dental Health Hospital, Clinic of Pediatric Dentistry, Kayseri, Turkey.

**Phone:** +90 352 355 15 15 **E-mail:** alemcosgun@hotmail.com

## INTRODUCTION

Giant cell granulomas were first described by Jaffe<sup>1</sup> in 1953, and they are generally non-neoplastic lesions observed in the mandible and maxilla.<sup>2,3</sup> These lesions are of periosteal, connective tissue or periodontal ligament origin and are considered as the hyperplastic, reparative connective tissue response of gingival tissue against injury and inflammation.<sup>4,5</sup> Giant cell granuloma is divided into two groups as peripheral and central according to the characteristic of the tissue from which it originates.<sup>6</sup>

Although its etiology is not fully understood, calculus, dental plaque, food accumulation, periodontal pockets, periodontal surgery, traumatic tooth extraction, malposed teeth, improper prosthesis and restorations, especially estrogen hormone activity and hyperparathyroidism of sex hormones are among the factors that cause the formation of peripheral giant cell granuloma (PGCG).<sup>7-12</sup>

The clinical appearance of PGCG is usually a painless and bleeding lesion with small, limited, dark red colored liver-tissue like focus, located on the gingival and alveolar crest, which may or may not be pedunculated or sessile.<sup>13,14</sup> PGCG is a soft tissue lesion, but it may cause resorption in the underlying bone tissue.<sup>15</sup> Superficial ulcerations can be observed in the lesions that are open to traumatic forces. The intraoral image may resemble pyogenic granuloma.<sup>13</sup>

Clinical, radiographic, biochemical, hormonal and histopathological evaluations should be taken into account while making diagnosis.<sup>16</sup> The definitive diagnosis is made by histopathological examination.<sup>17</sup> The mesenchymal cells and giant cells showing proliferation with a significant vascular increase are seen in histological examination. Mineralized tissue formation in the form of lamellar or woven bone has been reported in one third of the lesions.<sup>13</sup>

The elimination of local factors that cause PGCG, and then the surgical removal of the lesion from the mouth constitute the basis of the

treatment.<sup>18</sup> The extraction of the teeth in the lesion content, the correction of root surfaces of teeth adjacent to lesion and the removal of dental plaque decrease the likelihood of recurrence of the lesion. Consequently, the reformation of the lesion can be prevented with a good periodontal treatment and surgical approach.<sup>8</sup> The treatment of PGCG in children is performed the surgical removal of the lesion and follow-up of the patient as in other gingival reactional lesions.<sup>19</sup>

## CASE REPORT

A 6-year-old girl was admitted to our clinic due to swelling in her right lower jaw molar region. In the medical history taken with the help of her family, it was learned that no systemic disorder was present in the child and that she had swelling in the relevant region for 2 months. The patient had no pain, infection, and lymphadenopathy. It was learned that the patient had difficulty during chewing because of swelling. In the intraoral examination, a surface swollen lesion was observed in the vestibule of the milk molar region of the lower right jaw. It was observed that there was excessive crown damage and poor oral hygiene in teeth 84 and 85 in the relevant region. The lesion had a sessile, non-ulcerated and hyperemic appearance. (Figures 1, 2)

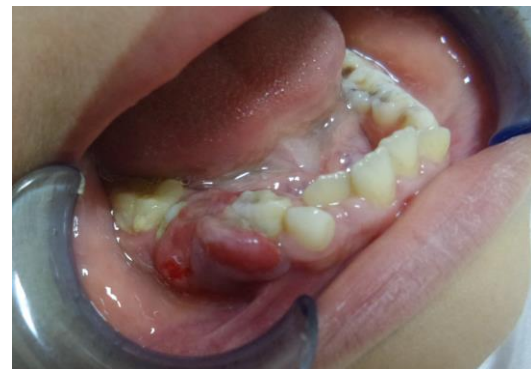

Figure 1. Intraoral appearance

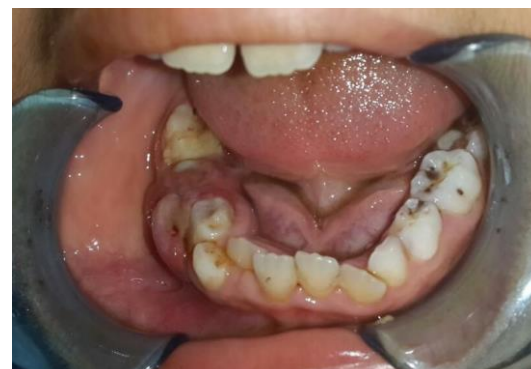
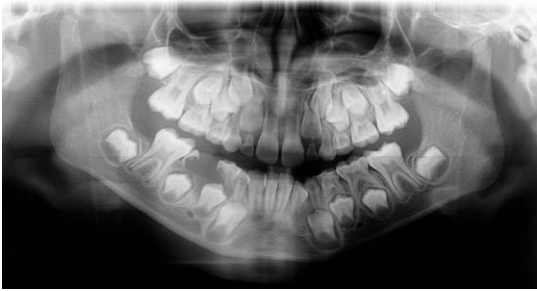
Figure 2. Occlusal appearance

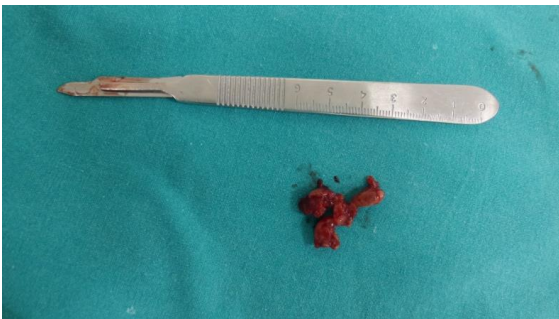
The resorbed roots in the region were observed in the radiographic examination. (Figure 3) As a result of clinical and radiographic evaluation, the lesion was pre-diagnosed as pyogenic granuloma and PGCG.



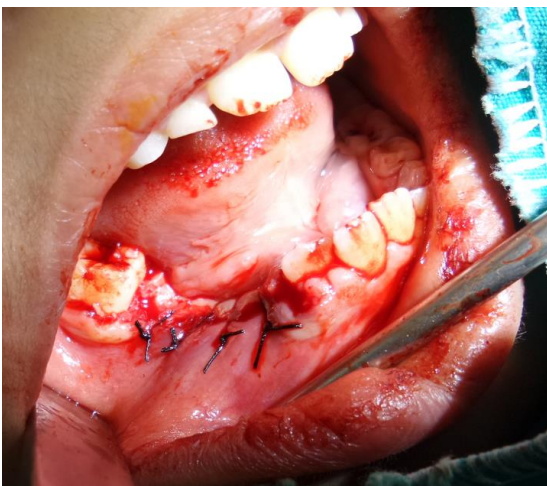**Figure 3.** OPG before operation

***Periodontal treatment and surgical approach***

As a first line treatment, the existing calculus and plaques in the patient were removed and the patient's oral hygiene habit was motivated. Then in the second session, it was ensured that oral hygiene was provided, teeth 84 and 85 were extracted under local anesthesia, and the lesion was removed with excisional incision. The region was primarily closed with silk suture. (Figures 4, 5) As a result of pathological evaluation, the lesion was diagnosed as PGCG.

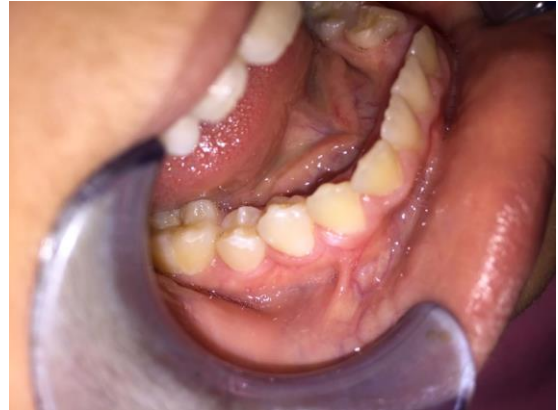

**Figure 4.** Excised lesion

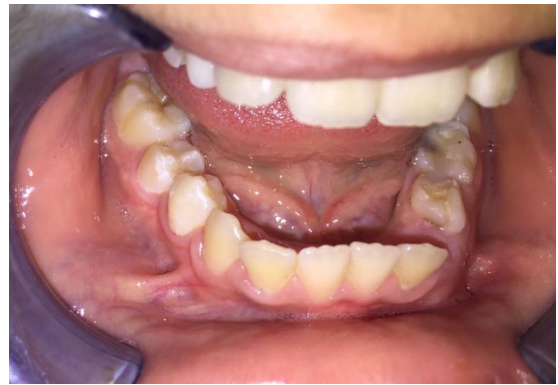

**Figure 5.** Oral appearance immediately after surgery

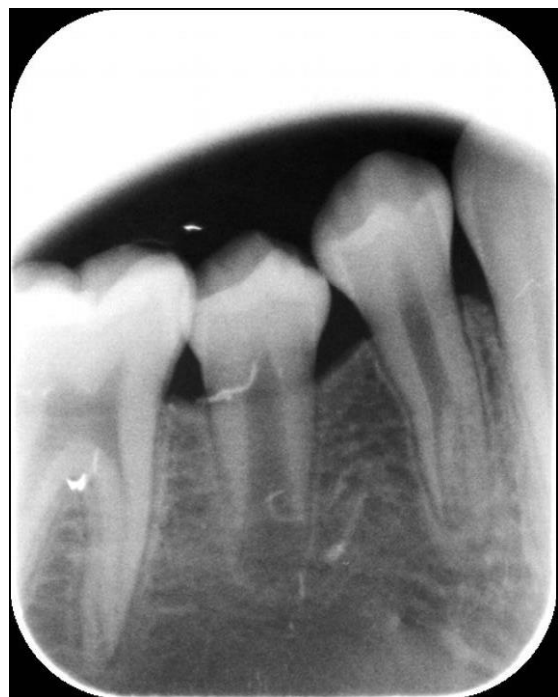The patient was called for control at 1 week, 1 and 6 months after the operation. As a result of clinical and radiographic evaluations in the patient's 2-year follow-up, it was observed that the operation area was recovered and that permanent premolar teeth were erupted. (Figures 6, 7, 8, 9)



**Figure 6.** Intraoral appearance 2 years after surgery



**Figure 7.** Occlusal appearance 2 years after surgery



**Figure 8.** Periapical film 2 years after surgery

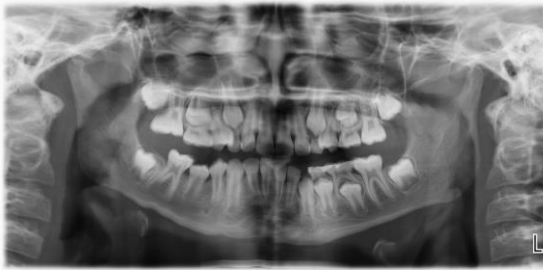


Figure 9. OPG 2 years after surgery

## DISCUSSION

PGCG is a lesion which can be seen in all age groups and observed in the gingival and alveolar crest regions of the oral cavity.<sup>19</sup> The incidence of the disease is higher in the elderly population in the 4th and 6th decade. However, only 20-30% of cases are seen in the 1st and 2nd decades.<sup>16</sup> In the literature, it has been reported that the incidence of the lesion is higher in women compared to men.<sup>18,20</sup> Although PGCG is relatively less seen in the child population, it can show an aggressive character.<sup>19</sup> In the presented case, the patient was 6 years old and in the first decade.

In a study carried out by Altan *et al.*<sup>21</sup>, it was reported that PGCG was most common reactive lesion seen in the oral cavity. When the literature is reviewed, there are studies reporting similar results.<sup>14</sup> However, in a study carried out by Kashyap *et al.*<sup>22</sup>, pyogenic granuloma was reported to be a more common reactive lesion.

When the localization of oral reactive lesions is examined, there are studies reporting that gingiva is the most commonly affected area.<sup>14</sup> PGCG is more common in the premolar and molar regions of the mandible, which is more suitable for food accumulation for the oral cavity.<sup>12, 23</sup> The localization of the lesion in our patient is the right molar and premolar region. In many case reports, the lesion was reported to have a diameter of 0.1-3 cm.<sup>24</sup> However, there are also cases where the lesion's diameter is 5 cm.<sup>23</sup> It was determined that the size of the lesion was 3 cm in our case.

The pain may cause localized swelling and displacement of the teeth although it depends on the localization of the lesion. Although it has a benign character, it may cause local destruction and can be seen in different forms from slow progression to aggressive growth.<sup>25, 26</sup> In this case

report, an aggressive lesion resorbing the roots of milk teeth can be mentioned.

Along with lesion, sometimes bleeding and discomfort can be seen, which may cause anxiety in the patient and psychological trauma in parents. In a study carried out by Pandofi *et al.*<sup>27</sup>, 16 cases with displacement of teeth and active bleeding during chewing were reported. The physician should manage such a discomfort in young patients and prepare an appropriate management plan for the success of the treatment.<sup>28</sup> Our patient, whose oral hygiene was corrected, was consulted to the oral and maxillofacial surgery department, and a multidisciplinary approach was adopted in the treatment.

The factors associated with the patient should be taken into account while planning the treatment of the lesions in the mouth. The success of the treatment is possible by gaining oral hygiene habits of the patient, as well as the fact that he/she follows maintenance appointments.<sup>29</sup> In our case, the motivation of oral hygiene was fully achieved, and no recurrence was observed in the 2-year follow-up. In such cases, the incidence in the maintenance phase should be determined by taking into account the individual factors.<sup>29</sup>

Peripheral giant cell granulomas can be seen as an oral symptom of hyperparathyroidism, although they are rare. In a study carried out by Smith & Fowler<sup>30</sup>, hyperparathyroidism was detected in 10% of PGCG patients. In a study carried out by Giananti *et al.*<sup>31</sup>, no relationship was found between hyperparathyroidism and PGCG. No hyperparathyroidism was found in our case. In a study carried out with 26 cases by Günhan *et al.*<sup>8</sup>, it was reported that these lesions could be affected by sex hormones.

No malignant transformation has been reported in the literature. PGCG can be confused especially with the advanced form of pyogenic granuloma. Furthermore, peripheral ossifying fibroma and hemangioma observed in children are also other benign submucosal lesions that should be taken into account in terms of differential diagnosis.<sup>32</sup>

## CONCLUSIONS

In conclusion, gaining oral hygiene habit to prevent recurrence, and the follow-up of the patient, as well as early diagnosis and treatment, are important to prevent bone destruction, advanced mobility in teeth or tooth loss due to this intraoral function, and the malfunction of phonation which may be caused by this disease, which is likely to show an aggressive character.

## ACKNOWLEDGEMENTS

None

## CONFLICTS OF INTEREST

None

### *Erken Yaşta Görülen Periferik Dev Hücreli Granüloma: 2 Yıllık Vaka Takibi*

## ÖZ

*Periferik dev hücreli granüloma (PDHG) her yaş grubunda izlenebilen ve oral kavitenin dişeti ve alveolar kret bölgelerinde gözlenen bir lezyondur. Çocuklarda nadir görülse de agresif karakter gösterebilir, ağrı, kanama, lokalize şişlik ve dişlerde yer değiştirmeye neden olabilir. Bu olgu raporunda PDHG'ye sahip 6 yaşındaki kız çocuğunun tedavisi ve 2 yıllık takibi sunulmaktadır. Anahtar Kelimeler: Granüloma, dev hücre, cerrahi, eksizyon, çocuk.*

## REFERENCES

1. Jaffe HL. Giant-cell reparative granuloma, traumatic bone cyst, and fibrous (fibro-oseous) dysplasia of the jawbones. *Oral Surg Oral Med Oral Pathol* 1953;6:159-175.
2. Aslan M, Kaya GŞ, Dayı E, Akkaş İ, Demirci E. A peripheral giant cell granuloma in early age. *J Dent Fac Atatürk Uni* 2006;16:61-64
3. Ünal M, Karabacak T, Vayısöğlü Y, Bağış HE, Pata YS, Akbaş Y. Central giant cell reparative granuloma of the mandible caused by a molar tooth extraction: Special reference to the maneuver of drilling the surgical field. *Int J Pediatr Otorhinolaryngol* 2006;70:745-748.
4. Tandon PN, Gupta SK, Gupta DS, Jurel SK, Saraswat A. Peripheral giant cell granuloma. *Contemp Clin Dent* 2012;3:118-121.
5. Effiom O, Adeyemo W, Soyele O. Focal reactive lesions of the gingiva: an analysis of 314 cases at a tertiary health institution in Nigeria. *Niger Med J* 2011;52:35-40.

6. Neville B, Damm D, Allen C, Bouquot J. *Oral Maxillofacial Pathology*. WB Saunders 1995:373-374
7. Mannem S, Chava VK. Management of an unusual peripheral giant cell granuloma: A diagnostic dilemma. *Contemp Clin Dent* 2012;3:93-96.
8. Günhan M, Günhan Ö, Celasun B, Mutlu M, Bostancı H. Estrogen and progesterone receptors in the peripheral giant cell granulomas of the oral cavity. *J Oral Sci* 1998;40:57-60.
9. Whitaker SB, Bouquot JE. Identification and semi-quantification of estrogen and progesterone receptors in peripheral giant cell lesions of the jaws. *J Periodontol* 1994;65:280-283.
10. Burkes EJ, Jr., White RP, Jr. A peripheral giant-cell granuloma manifestation of primary hyperparathyroidism: report of case. *J Am Dent Assoc* 1989;118:62-64.
11. Develioğlu AH, Bostancı V, Nalbantoğlu AM. Evaluation of peripheral giant cell granuloma: a case report. *Cumhuriyet Dent J* 2006;9:46-49
12. Yalçın E, Ertaş Ü, Altaş S. Peripheral giant cell granuloma: a retrospective study. *J Dent Fac Atatürk Uni* 2010;20:34-37.
13. Dayan D, Buchner A, Spierer S. Bone formation in peripheral giant cell granuloma. *J Periodontol* 1990;61:444-446.
14. Naderi NJ, Eshghyar N, Esfahanian H. Reactive lesions of the oral cavity: A retrospective study on 2068 cases. *Dent Res J* 2012;9:251-255.
15. Kibar S, Yılmaz H, Erdoğan BA, Şanlı A, Kayahan S. Peripheral giant cell granuloma of the hard palate. *İstanbul Med J* 2013;14:136-139.
16. Sharma RR, Verma A, Pawar SJ, Dev E, Devadas R, Shiv VK, Musa MM. Pediatric giant cell granuloma of the temporal bone: a case report and brief review of the literature. *J Clin Neurosci* 2002;9:459-462.
17. Cayci E, Kan B, Guzeldemir-Akcakanat E, Muezzinoglu B. Peripheral giant cell reparative granuloma of maxilla in a patient with aggressive periodontitis. *Oral Health Dent Manag* 2014;13:638-641.
18. Katsikeris N, Kakarantza-Angelopoulou E, Angelopoulos AP. Peripheral giant cell granuloma. Clinicopathologic study of 224 new cases and review of 956 reported cases. *Int J Oral Maxillofac Surg* 1988;17:94-99.
19. Ömür D, Paşaoğlu Ö, Sinan A. Surgical Treatment of Pediatric Peripheral Giant Cell Granuloma: A Case Report. *J Dent Fac Atatürk Uni* 2015;25:31-34
20. Lester SR, Cordell KG, Rosebush MS, Palaiologou AA, Maney P. Peripheral giant cell granulomas: a

series of 279 cases. *Oral Surg Oral Med Oral Pathol Oral Radiol* 2014;118:475-482.

**21.** Altan A, Damlar İ, Yanık S, Arpağ OF, Demirkol M. Reactive lesions of the oral cavity: a retrospective study on 147 cases. *J Dent Fac Atatürk Uni* 2014;24:373-377

**22.** Kashyap B, Reddy PS, Nalini P. Reactive lesions of oral cavity: A survey of 100 cases in Eluru, West Godavari district. *Contemp Clin Dent* 2012;3:294-297

**23.** Bodner L, Peist M, Gatot A, Fliss DM. Growth potential of peripheral giant cell granuloma. *Oral Surg Oral Med Oral Pathol Oral Radiol Endod* 1997;83:548-551.

**24.** Kfir Y, Buchner A, Hansen LS. Reactive lesions of the gingiva: a clinicopathological study of 741 cases. *J Periodontol* 1980;51:655-661.

**25.** Ciorba A, Altissimi G, Giansanti M. Giant cell granuloma of the maxilla: case report. *Acta Otorhinolaryngol Ital* 2004;24:26-29.

**26.** Ficarra G, Kaban LB, Hansen LS. Central giant cell lesions of the mandible and maxilla: a clinicopathologic and cytometric study. *Oral Surg Oral Med Oral Pathol* 1987;64:44-49.

**27.** Pandolfi P, Feleflı S, Flaitz C, Johnson J. An aggressive peripheral giant cell granuloma in a child. *J Clin Pediatr Dent* 1998;23:353-355.

**28.** Patel JC, Sujan SG, Deshpande AN, Dave BH. Peripheral Giant Cell Granuloma in 9-Year-Old Female Patient. *J Orofac Res* 2013;3:148-151.

**29.** Ertugrul A, Hakkı S, Ataoglu T, Demiralp B, Avunduk M. Treatment of Peripheral Giant Cell Granuloma: A Case Report. *Journal Of Hacettepe Faculty Of Dentistry* 2005;29:49-53.

**30.** Smith BR, Fowler CB, Svane TJ. Primary hyperparathyroidism presenting as a “peripheral” giant cell granuloma. *J Oral Maxillofac Surg* 1988;46:65-69.

**31.** Giansanti JS, Waldron CA. Peripheral giant cell granuloma: review of 720 cases. *J Oral Surg* 1969;27:787-791.

**32.** DaSilva FC, Piazzetta CM, Torres-Pereira CC, Schussel JL, Amenabar JM. Gingival proliferative lesions in children and adolescents in Brazil: A 15-year-period cross-sectional study. *J Indian Soc Periodontol* 2016;20:63-66.