



## CASE REPORT

# Non-syndromic familial unerupted teeth: A rare contidion

*IsmailSener, DDS, PhD, AkifTurer, DDS, PhD, CihanBereket, DDS, PhD, Muhsin Ozdemir, DDS  
Department of Oral and Maxillofacial Surgery, Faculty of Dentistry, Ondokuz Mayıs University, Samsun, Turkey*

### ARTICLE INFO

*Article history:*

Received 26-March-2013

Accepted 24-July-2013

*Keywords:*

Hereditary,  
Primary tooth,  
Unerupted

### ABSTRACT

A tooth that remains unerupted beyond the normal time of eruption and fails to erupt is called an impacted tooth. Maxillofacial surgeons encounter the problem of impacted teeth very often. Usually, impacted teeth involve the permanent dentition and they are rare in the primary dentition. Impaction of a primary tooth is a very rare entity. These rare cases are seen more frequently in primary second molars, followed by the order of the lower and upper central incisor, lateral incisor and the canine teeth. Evolutionary and hereditary factors may cause uneruption.

In this report, three cases of impacted primary teeth that belong to same familial members are presented. Father and sons. We extracted boy's teeth but father refused treatment.

## INTRODUCTION

“Tooth impaction” refers to situations where failure to erupt appears to be due to a mechanical blocking and the tooth remains unerupted beyond the normal time of eruption. The condition is caused by systemic or local etiologic factors. Usually impacted teeth involve the permanent dentition; they are rare in the primary dentition.<sup>1</sup> Second primary molars have been the teeth most frequently involved followed by primary central incisors.<sup>2-5</sup>

Local contributing factors of impacted primary teeth include: odontomas, ankylosis, congenitally missing permanent teeth, defects in the periodontal membrane, trauma, injuries of the periodontal ligament, precocious eruption of the first permanent molar, defective eruptive force or a combination of these factors.<sup>6,7</sup>

Treatment methods for impacted primary teeth are extraction and observation with or without surgical removal. Most impacted primary teeth were extracted and a few erupted later following a more conservative approach.<sup>7</sup>

In this report, three cases of impacted primary teeth that belong to same familial members are presented. Father and his sons. The father did not complaint but one of the sons had fistula at the upper left molar region. We extracted boys’ teeth but father refused treatment.

## CASES PRESENTATION

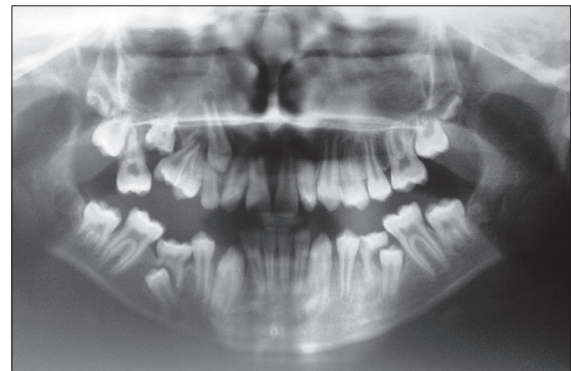
### Case-1

An 11 year old boy referred to our department with a complaint of chronic infection in the maxillary right premolar region in February 2011. There was no history of trauma to maxillofacial region, no relevant medical history and normal development for his age. Intra-oral examination revealed the cusp of maxillary right second premolar was

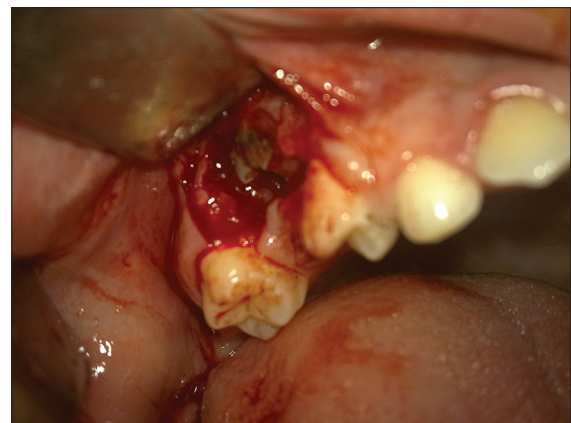
observed and a fistula in his right maxillary region. Mandibular second primary molars was found to be severely infra-occluded, mandibular first premolars and molars had tilted toward the infra-occluded teeth and patient was in mixed dentition and caries free. In radiographic examination also showed he had an unerupted maxillary right primary second molar (Figure 1). After clinical and radiological evaluations we decided to extract tooth for correct alignment of permanent second premolar (Figure 2). After surgery we learned that his brother and father have impacted primary molar too. They were invited for examination.

### Case-2

An 8 year old boy, with no relevant medical history and normal development for his age was referred to our department in February



**Figure 1.** Preoperative radiograph of first patient

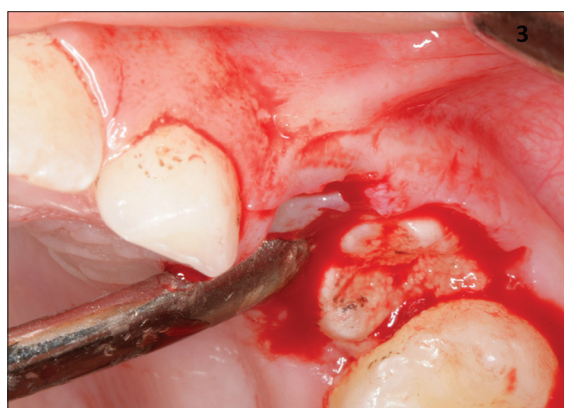


**Figure 2.** Surgical removal of primary molar

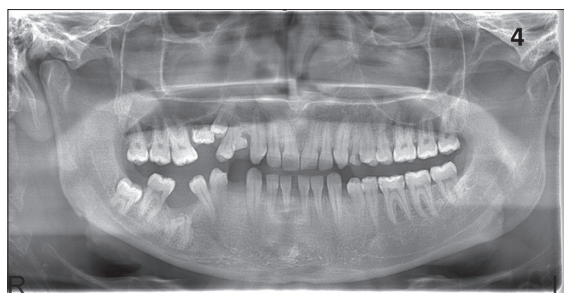2011 for routine dental control. Intra-oral and radiographic examination showed the patient was in mixed dentition and caries free, also showed he had an unerupted maxillary left primary second molar and mobility in primary first molar. Teeth were surgically removed (Figure 3).

### Case-3

A 27 year old man, with no relevant medical history and normal development for his age was referred to our department in February 2011 for routine dental control. There was no history of trauma to maxillofacial region, no relevant medical history. Intra-oral examination showed missing second premolar and submerged primary canine tooth. After radiographic analysis we determined that he had an unerupted maxillary right primary second molar. He also had mandibular right molar's roots (Figure 4). We offered him



**Figure 3.** Intraoperative view of second patient



**Figure 4.** Panoramic radiograph of third patient

surgical treatment for all teeth but he refused.

### DISCUSSION

The normal eruption of deciduous and permanent teeth into the oral cavity occurs over a broad chronologic age range. Racial, ethnic, sexual, and individual factors can influence eruption and are usually considered in determining the standards of normal eruption.<sup>8-10</sup> An impacted tooth is usually associated with permanent dentition and is a rare entity during the development of primary dentition, with a reported prevalence ratio of 1:10 000.<sup>11</sup>

The most frequently impacted permanent teeth are third molars and canines. However, in the primary dentition, it would appear that the teeth most frequently involved are primary molars, followed by primary incisors.<sup>1</sup> Most of the previously reported cases of impacted primary teeth were second primary molars, with no difference in occurrence between mandibular and maxillary primary second molars. In this study, all of our patients had impacted maxillary primary second molars.

According to literature local factors reported as contributing to impacted primary teeth include: odontomas, other types of odontogenic tumors, ankylosis, traumatic injury, defects in the periodontal membrane, injuries of the periodontal ligament, precocious eruption of the first permanent molar, dentigerous cysts and genetic factors.<sup>12-17</sup> Like in our study, the presence of familial recurrence of the defect and the expression of this anomaly in family members supported the hypothesis of genetic origin.

Otsuka *et al.* reviewed clinical features in 13 cases of impacted primary teeth and found the right:left ratio 1:2.5.<sup>7</sup> In our study two of three patients had right impacted primary molars. Bianchi and Rocuzzo

found the prevalence of primary teeth impaction to be 1:10,000 (by screening 30,000 panoramic radiographs).<sup>18</sup>

There are different thoughts about treatment of impacted primary teeth. When impacted primary teeth have enough space to erupt in the dental arch, surgical exposure with removal of the overlying gingiva or any overlying odontoma should be performed and the impacted teeth kept under observation for three months. Where the tooth fails to erupt, orthodontic traction should be applied. When there is insufficient space for the tooth to erupt, it may necessary to increase the space by up righting inclined neighboring teeth. If there is no expectation of eruption, the teeth should be extracted.<sup>7</sup>

In these cases, we preferred surgical treatment because of insufficient space and for correct alignment of second premolars.

## REFERENCES

1. Pindborg JJ. Impaction of teeth. In: Pindborg JJ. Pathology of the Dental Hard Tissues. Copenhagen: Munkgaard, 1970:241-247.
2. Motokowa W, Braham RL, Morris ME, Tanaka M. Surgical exposure and orthodontic alignment of an unerupted primary maxillary second molar impacted by an odontoma and a dentigerous cyst: a case report. *Quintessence International* 1990;21:159-162.
3. Boyczuk MP, Berger JR. Identifying a deciduous dentigerous cyst. *Journal of the American Dental Association* 1995;126:643-644.
4. Haishima K, Haishima H, Yamada Y, Tomizawa M, Noda T, Suzuki M. Compound odontomas associated with impacted maxillary primary central incisors: report of two cases. *International Journal of Paediatric Dentistry* 1994;4:251-256.
5. Jameson GD & Bruke PH. Inversion of second deciduous molar and second premolar. *British Dental Journal* 1997;162:265-266.
6. Oikarinen V, Guven O, Silaste H. Similarly impacted second and third maxillary and mandibular molars in a pair of monozygotic twins. *Dentomaxillofac Radiol* 1990;19:133-134.
7. Otsuka Y, Mitomi T, Tomizawa M, Noda T. A review of clinical features in 13 cases of impacted primary teeth. *Int J Paediatr Dent* 2001;11:57-63.
8. Schour I, Massler M. The development of the human dentition. *J Am Dent Assoc* 1941;28:1153-1160.
9. Nolla CM. The development of the human dentition. *ASDC J Dent Child* 1960;27:254-266.
10. Moorrees CFA, Fanning EA, Hunt EEJ. Age variation of formation stages for ten permanent teeth. *J Dent Res* 1963;42:1490-1502.
11. Krogh PH, Lindquist CC. Impactions-should you bother them if they don't bother you? *J Dist Columbia Dent Soc* 1977;52:55-58.
12. Rohlin M. An impacted deciduous first molar. *Oral surgery* 1974;37:820-823.
13. Adams TW. An impacted primary lateral incisor as a cause of delayed eruption of a permanent tooth: a case report. *Paediatric Dentistry* 1998;20:121-123.
14. Antoniadis K, Tsodoulos S, Karakasis D. Totally submerged deciduous maxillary molars. Case reports. *Australian Dental Journal* 1993;38:436-438.
15. Rothberg MS, Cangiano RJ, Dutante AJ, Maccaro H. Intranasal presentation of an intruded deciduous incisor. *Oral Surgery, Oral Medicine, Oral Pathology* 1991;72:263-266.
16. Mason C, Odell EW, Longhurst P. Dental complications associated with



reported orotracheal intubation in infancy: a case report. *International Journal of Paediatric Dentistry* 1994;4:257-264.

- 17.** Brandt SK, Manson MH, Barkley R. Ameloblastic fibrodentinoma: report

of case. *Journal of Dentistry for Children* 1988;55:372-375.

- 18.** Bianchi SD, Rocuzzo M. Primary impaction of primary teeth: A review and report of three cases. *J Clin Pediatr Dent* 1991;15:165-168.

**How to cite this article:** Ismail Sener, Akif Turer, Cihan Bereket, Muhsin Ozdemir. Non-syndromic familial unerupted teeth: A rare condition. *Cumhuriyet Dent J* 2015;18(4):359-363.