

## CASE REPORT

**Management of atypical mandibular coronoid process elongation with bilateral intraoral coronoidotomy**

Sıdıka Sinem Soydan, DDS, PhD, Tuba Develi, DDS, Sina Uçkan, DDS, PhD

Ba kent University, Faculty of Dentistry, Department of Oral and Maxillofacial Surgery, Ankara, Türkiye.

Received: 03 November 2012

Accepted: 19 December 2012

**ABSTRACT**

Bilateral coronoid hyperplasia is characterized by a progressive limitation in mandibular movement, secondary to mechanical impingement of the elongated coronoid processes on the posterior surface of the zygomas. The etiology of coronoid hyperplasia remains uncertain, with various proposed theories. As it is an unusual and infrequent clinical entity, hyperplasia of the coronoid process is often overlooked or diagnosed too late. A 27-year old, ASA I, male patient referred to our clinic because of his restricted mouth opening. Bilateral coronoid hyperplasia was detected after detailed temporomandibular joint examination. Restricted mouth opening was successfully treated by bilateral intraoral coronoidotomy with additional physiotherapy. The aim of this case report were emphasizing the mandibular coronoid process elongations as an unignorable differential diagnosis of the asymptomatic mandibular hypomobility cases additionally to the temporomandibular joint and masticatory muscles disfunctions and were describing that its treatment can be successfully performed by intraoral surgery and physiotherapy.

**Keywords:** Coronoid process hyperplasia; coronoid process elongation; temporomandibular joint disorders; restricted mouth opening.

**INTRODUCTION**

Coronoid process hyperplasia was first described in 1853 by Von Langenbeck.<sup>1</sup> It was first named in 1899 by Oscar Jacob as Jacob's disease.<sup>2</sup> Jacobs's disease is an uncommon entity with only a few documented cases in the literature.<sup>3-6</sup> Jacob's disease is characterized with the formation of a new joint between a pathologically elongated coronoid process and the body of the malar homolateral bone. Today Jacob's disease and isolated coronoid elongation are accepted as two different type coronoid hyperplasia.<sup>5,7</sup>

Isolated coronoid hyperplasia's etiology is unknown and it can occur in both unilateral and bilateral forms. Unilateral or bilateral coronoid hyperplasia cases have been reported since 1963 in the literature and when it is compared with the other disorders that related to reductive mouth opening, coronoid hyperplasia has a very rare incidence.

The unilateral coronoid hyperplasia first manifests with progressive limitation of mouth opening and facial asymmetry. Pain is uncommon and unilateral coronoid hyperplasia mainly affects young and female patients.<sup>8</sup>

Bilateral coronoid hyperplasia is characterized by a progressive limitation in mandibular movement, secondary to mechanical impingement of the elongated coronoid processes on the posterior surface of the zygomas. Usually bilateral coronoid

Sıdıka Sinem SOYDAN  
Ba kent Üniversitesi, Di Hekimliği Fakültesi,  
A ız Di Çene Hastalıkları ve Cerrahisi AD  
11. Sokak No:26 Bahçelievler, Ankara, Türkiye  
Tel. +903122151336  
Fax. +903122152962  
e-mail. sdksoydan@yahoo.com

hyperplasia does not disturb the patient because it is painless, there is no facial asymmetry and progressive limitation of the mouth opening can possibly evolve over years. Bilateral cases of coronoid hyperplasia show a marked male preponderance with a ratio 5:1.<sup>8</sup>

The hyperplasia can be definitely diagnosed by three dimensional (3D) computerized tomography (CT).<sup>7</sup> CT can give exact information of the length of the coronoid process and its relation to the zygomatic bone.<sup>3</sup>

An unusual and infrequent clinical entity, bilateral hyperplasia of the coronoid process and its treatment procedure is described in this case report.

### CASE REPORT

A 27-year old, ASA I, male patient referred to our clinic from conservative treatment clinic due to his restricted mouth opening. The dental practitioner was unable to do patient's fillings due to the limited mouth opening. The patient was unaware about the situation and did not have any complains including any pain or temporomandibular disorder (TMD) symptoms.

There was no pain on palpation and during jaw movements. Also all the muscles of mastication were free of pain on extraoral and intraoral examination. There was no trauma history or familial history of limited mouth opening. There was no malocclusion and the maximal interincisal distance was 19,9 mm (Figure 1).

The clinical situation was similar to bilateral non-reductive disc displacement without pain however there was not any radiographic finding related to non-reductive disc displacement on axial magnetic resonance (MRI) scans (Figures 2A-B). An unusual elongation of the coronoid process was noted on panoramic radiograph and maxillofacial CT was requested. Bilateral coronoid hyperplasia was detected on three dimensional CT

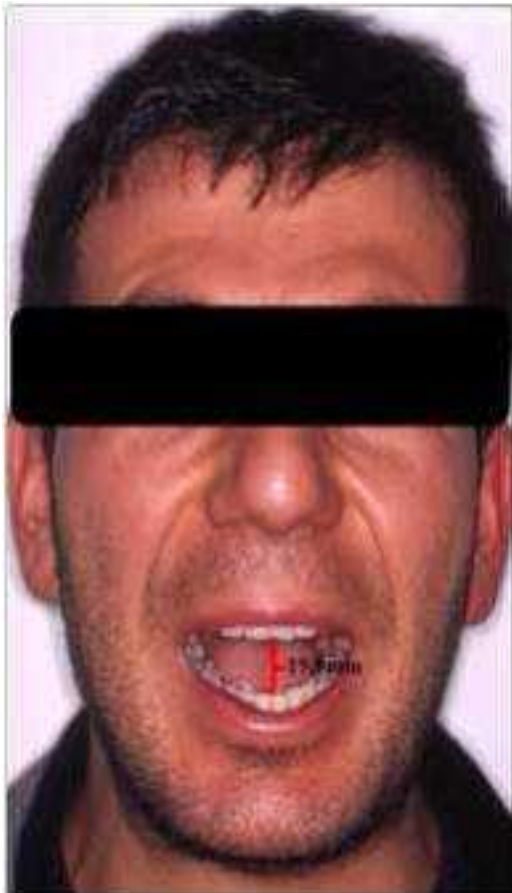scans (Figures 3A-B). The diagnose of Jacob's Disease was eliminated after CT scans evaluation because there was not any sign of joint formation between the mandibular coronoid process and malar bone.

Fibrous attachments and scar tissue were detected in the palm of the patient's both hands and, dermatology and rheumatology consultations were required. However there was not any connective tissue disorder or syndrome according to the results of medical evaluations.

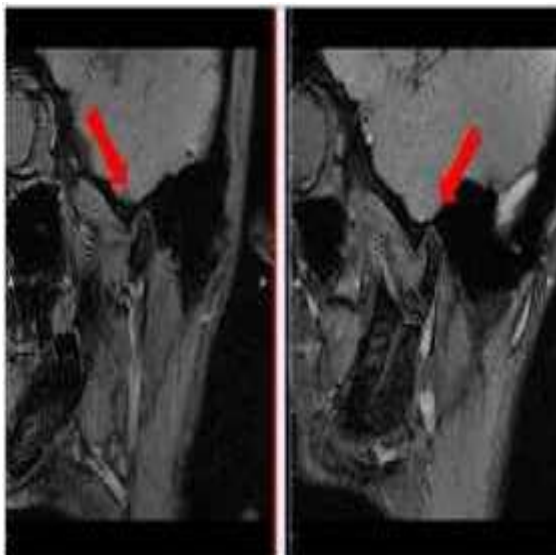
The bilateral intraoral coronoidotomies were performed under general anesthesia. An intraoral approach along the anterior border of ramus beginning from the angulus area was used and the incision line was a little bit higher but similar to Sagittal Split Ramus Osteotomy (SSRO) incision. The ascending ramus of the mandible was exposed as far as the sigmoid notch. Following the insertion of special retractors a horizontal osteotomy was made with a reciprocating saw from the sigmoid notch to the anterior border of the ascending ramus. Coronoidectomy was not performed. Bilateral elongated coronoid processes were moved superiorly in the infratemporal region immediately after the osteotomy due to the pulling of temporal muscle. Panoramic radiograph was taken for controlling the bone segment's final positions at immediately after the surgery and 2 years follow-up of the patient (Figures 4A-B).

Patient only compromised from the voice which occurred during the jaw movement at postoperative period however the voice decreased and disappeared two months after the surgery.

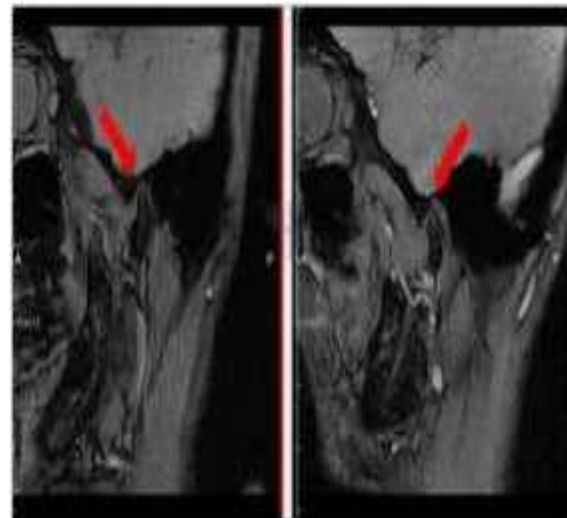
The maximal comfortable interincisal distance was 33mm immediately after the surgery. Aggressive physiotherapy by tongue blades was initiated on third postoperative day and continued for two months. The amount of tongue bundle was increased day by day and mouth opening was controlled once a week by the dental



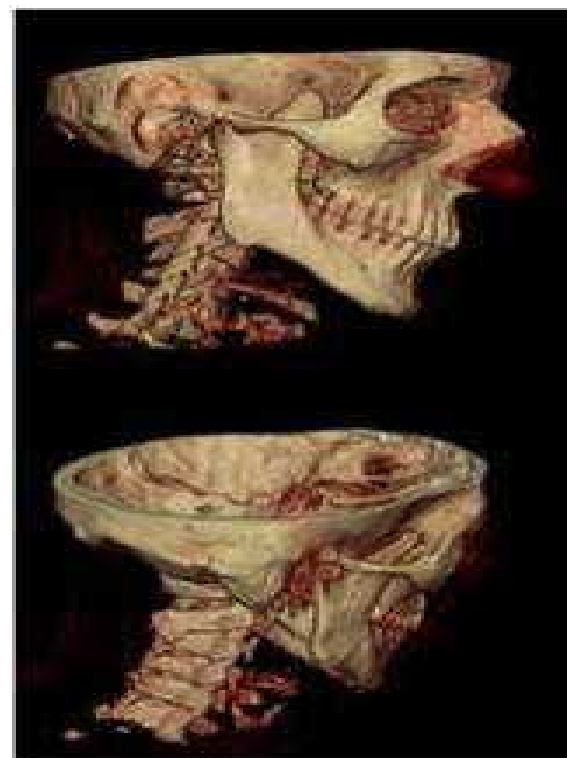
**Figure 1.** Preoperative restricted mouth opening (19.9 mm) of the patient.



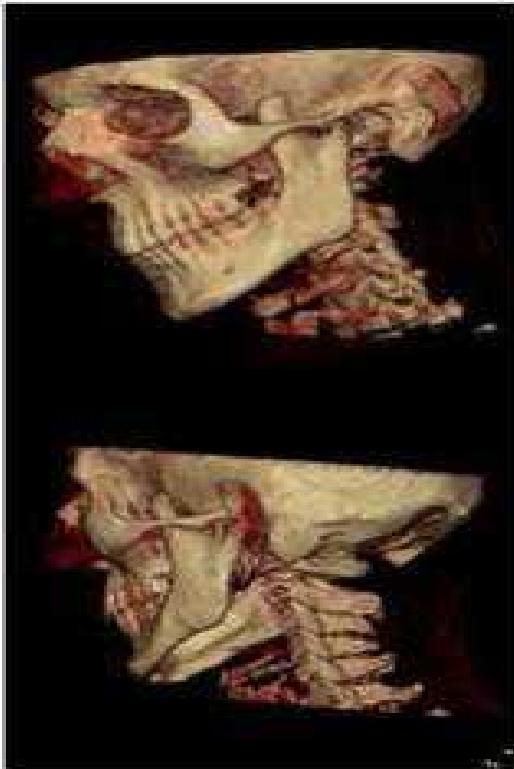
**Figure 2A.** Left figure showed the intracapsular position of the right condyle and right figure showed the intracapsular position of the left condyle during the close mouth position in axial plane.



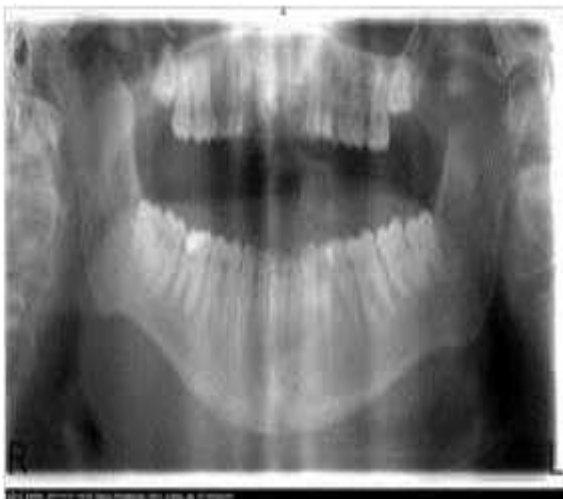**Figure 2B.** Right and left intracapsular position of the condyl during the maximal mouth opening position in axial plane. Condyle movement was restricted however disc, retrodiscal tissues and pyterygoid muscles were radiographically normal.



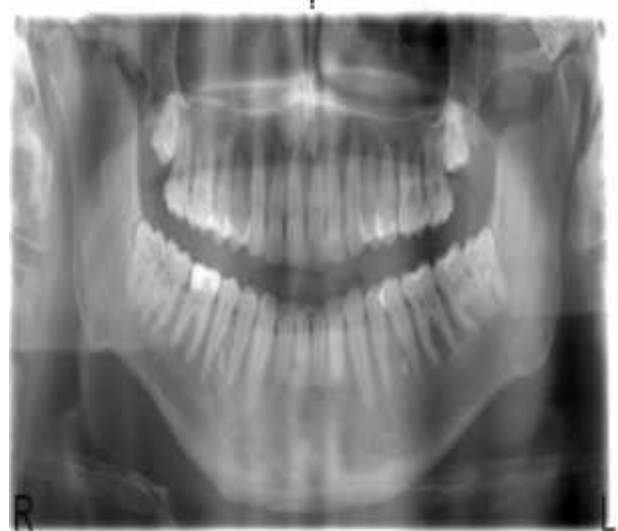**Figure 3A.** Three dimensional computerized tomographic view shows the elongated right coronoid process from different directions.



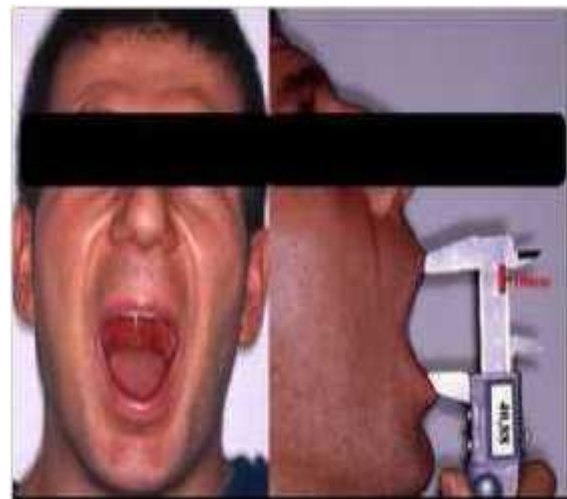**Figure 3B.** Three dimensional computerized tomographic view shows the elongated left coronoid process from different directions.



**Figure 4A:** Panoramic radiograph shows the bilateral osteotomy lines of the coronoid process immediately after the surgical procedure.



**Figure 4B.** Panoramic radiograph shows the final situation of the osteotomy lines of the coronoid process at the 1 year postoperative control appointment.



**Figure 5:** The final mouth opening of the patient was 40,88 mm following two months physiotherapy.

practitioner. The maximal enforced interincisal distance was reached 50.3 mm and patient's comfortable mouth opening increased gradually to 40.88 mm at the follow up period of 2 years (Figure 5).

#### DISCUSSION

The etiology of bilateral coronoid hyperplasia is uncertain and remains with various proposed theories such as endocrine stimulus, increased temporalis

activity, trauma, genetic inheritance and familial occurrence have all been suggested, none of which exactly explains the condition. Colquhoun et al.<sup>9</sup> reported coronoid hyperplasia cases in two brothers that their parents were not affected. None of these predisposing factors and/or familial history of coronoid hyperplasia were observed in this presented case.

There is confusion in the classification of coronoid enlargement types. This confusion has arisen partly from inadequate diagnosis of an abnormal histological condition of the coronoid process. Isolated Jacob's disease or secondary to the osteoma or osteochondroma, Bechterew disease with ankylosing spondylitis, neoplastic formation of coronoid hyperplasia and isolated coronoid hyperplasia are different subgroups of coronoid hyperplasia.<sup>3,8</sup>

Bilateral coronoid process hyperplasia is characterized by a gradual decrease of the mouth opening starting at puberty although not all patients report reduced mouth opening as their main complaint. Symptomatic patients, however, frequently visit many practitioners before the diagnosis is reached because of the failure of clinicians in diagnosing coronoid hyperplasia.

Coronoidectomy and coronoidotomy are the treatment of choice for coronoid hyperplasia. Coronoidectomy usually performed intraorally however in such cases extraoral incisions may be required. Coronoidotomy can be easily performed by intraoral approach and a significant improvement in mouth opening can be obtained with coronoidotomy. However coronoidotomy alone in such situations may risk regrowth and recurrence of trismus.<sup>10</sup> Chen et al.<sup>11</sup> described a new modified (gap) coronoidotomy technique to avoid the coronoid process interfering with the upper part of the ramus during closing of the mouth and disocclusion. The gap coronoidotomy is removal of a bone

segment from the coronoid process instead of only cutting the coronoid process through.<sup>11</sup>

In the presented case conventional coronoidotomy was preferred instead of coronoidectomy for avoiding the temporal muscle fiber damage. Bilateral displaced coronoid processes did not lead to any disturbance both during the rest position and mandibular movement. There was no hematoma or trismus following the surgery and there was no recurrence or interference between the ascending ramus and coronoid process at the post-operative twelfth months.

Many instruments, such as spatulas, wedges or tweezers, are regularly used in mouth opening exercises. Sometimes these instruments have the wrong type of surface, and exert greater pressure on the incisors, with the consequent danger of causing dislocation or fractures of the teeth. Gibbons et al.<sup>12</sup> recommends to use therabite appliance for protection of dental structures during the physiotherapy. In this presented case spatulas were used without any incisor teeth disturbance. Aggressive physiotherapy is required for adaptation of the muscles and really important for the effective improvement of the mouth opening and avoiding the recurrence following the coronoidotomy.<sup>13</sup> Patient must be tolerated and participated the prolonged physiotherapy period for reaching the successful results.

Yura et al.<sup>14</sup> reported a case of successfully treated unilateral coronoid hyperplasia by coronoidotomy and prolonged physiotherapy. They observed a reunion between the the coronoid process and mandibular ascending ramus, with moderate dislocation and inclination posteriorly at radiographic follow-up.<sup>14</sup> In our presented case superiorly located coronoid process has retained its initial position at 2 years postoperative radiographic control evaluation (Figure 4B). Patient's final

mouth opening was still 40,88mm and no reunion between the ascending ramus and coronoid process was thought according to the clinical evaluation.

Intraoral bilateral coronoidotomy with postoperative prolonged physiotherapy for treatment of coronoid process hyperplasia allowed satisfactory and stable results in the correction of coronoid-malar interference.

## REFERENCES

1. Von Langenbeck B. Angeborene Kleinheit der Unterkiefer. *Langenbeck's Archiv* 1861;1:451-455.
2. Jacob O. Une cause rare de constriction permanente des mâchoires. *Bull Mem Soc Anat Paris* 1899;1:917-919.
3. Akan H, Mehreliyeva N. The value of three-dimensional computed tomography in diagnosis and management of Jacob's disease. *Dentomaxillofac Radiol* 2006;35:55-59.
4. D'Ambrosio N, Kellman RM, Karimi S. Osteochondroma of the coronoid process (Jacob's disease): an unusual cause of restricted jaw motion. *Am J Otolaryngol* 2011;32:52-54.
5. Emekli U, Aslan A, Onel D, Cizmeci O, Demiryont M. Osteochondroma of the coronoid process (Jacob's disease). *J Oral Maxillofac Surg* 2002;60:1354-1356.
6. Zhong SC, Xu ZJ, Zhang ZG, Zheng YH, Li TX, Su K. Bilateral coronoid hyperplasia (Jacob disease on right and elongation on left): report of a case and literature review. *Oral Surg Oral Med Oral Pathol Oral Radiol Endod* 2009;107:64-67.
7. Izumi M, Isobe M, Toyama M, Arijji Y, Gotoh M, Naitoh M, Kurita K, Arijji E. Computed tomographic features of bilateral coronoid process hyperplasia with special emphasis on patients without interference between the process and the zygomatic bone. *Oral Surg Oral Med Oral Pathol Oral Radiol Endod* 2005;99:93-100.
8. Galiè M, Consorti G, Tieghi R, Denes SA, Fainardi E, Schmid JL, Neuschl M, Clauser L. Early surgical treatment in unilateral coronoid hyperplasia and facial asymmetry. *J Craniofac Surg* 2010;21:129-133.
9. Colquhoun A, Cathro I, Kumara R, Ferguson MM, Doyle TC. Bilateral coronoid hyperplasia in two brothers. *Dentomaxillofac Radiol* 2002;31:142-146.
10. Gerbino G, Bianchi SD, Bernardi M, Berrone S. Hyperplasia of the mandibular coronoid process: long-term follow-up after coronoidotomy. *J Craniomaxillofac Surg* 1997;25:169-173.
11. Chen CM, Chen CM, Ho CM, Huang IY. Gap coronoidotomy for management of coronoid process hyperplasia of the mandible. *Oral Surg Oral Med Oral Pathol Oral Radiol Endod*. 2011;112:e1-4.
12. Gibbons AJ, Abulhoul S. Use of a Therabite appliance in the management of bilateral mandibular coronoid hyperplasia. *Br J Oral Maxillofac Surg* 2007;45:505-506.
13. Ramalho-Ferreira G, Faverani LP, Fabris AL, Pastori CM, Magro-Filho O, Ponzoni D, Aranega AM, Garcia-Júnior IR. Mandibular movement restoration through bilateral coronoidectomy by intraoral approach. *J Craniofac Surg*. 2011;22:988-991.
14. Yura S, Ohga N, Ooi K, Izumiyama Y. Mandibular coronoid hyperplasia: a case report. *Cranio* 2009;27:275-279.