

**Multiple unerupted mandibular permanent molar teeth: a case report**

Bora Özden, DDS, PhD,<sup>a</sup> Burcu Baş, DDS, PhD,<sup>a</sup> Aydan Açıkgöz, DDS, PhD,<sup>b</sup> Kaan Gündüz, DDS, PhD,<sup>b</sup>

<sup>a</sup>Ondokuz Mayıs University, Dental Faculty, Department of Oral and Maxillofacial Surgery, Samsun, Turkey.

<sup>b</sup>Ondokuz Mayıs University, Dental Faculty, Department of Oral Diagnosis and Radiology, Samsun, Turkey.

Received: 15 April 2011 Accepted: 03 July 2011

**ABSTRACT**

The multiple impacted teeth at jaws are a rare condition that frequently associated with syndromes, metabolic disorders or trauma. A 48-year old male patient was referred to our clinic, with complaint of pain on right retromolar region while chewing. The patient had facial asymmetry and restricted mouth opening. Clinical and radiographic examination revealed the impaction of mandibular first, second and third molar and an abnormal condyle and coronoid process. All of the impacted teeth were extracted. Because the patient refused other treatment procedures no surgical intervention was performed for the asymmetry and restricted mouth opening. Six months clinic and radiographic follow up were satisfactory.

**Keywords:** Mandible, molar, tooth, impacted.

**INTRODUCTION**

Tooth impaction is a frequent phenomenon in the literature and defined as cessation of eruption of a tooth.<sup>1</sup> It can originate from local etiologic factors including; ectopic tooth development or eruption, thickened overlying osseous or mucosal tissues, premature apical closure, unfavorable tooth rotation, altered eruption sequence, premature loss of a deciduous tooth, retained or ankylosed deciduous teeth, presence of supernumerary teeth, presence of a cyst, insufficient space in the dental arch, secondarily from childhood maxillofacial or dentoalveolar trauma.<sup>2-5</sup>

In the permanent dentition, third molars are the most common teeth to become impacted accounting for over 80% of all impacted teeth.<sup>6-8</sup> Maxillary canines have the second frequency, followed by premolars and second molars. Impactions of first and second molars are relatively uncommon. Cho et al, reported the prevalence of impaction of permanent mandibular second molars to be %1.<sup>8</sup> Impaction of permanent first molars were found 0.0001%.<sup>9</sup>

While impaction of tooth is widespread, multiple impacted teeth by itself is a rare condition and often found in association with syndromes.<sup>10</sup> Impaction of multiple teeth at the same region is also relatively, rare.<sup>10</sup> Kamberos et al, examined 1740 patients and found the percentage of patients with three or more impacted teeth to be 11.37%. While, the 45.96% of these patients had 4 impacted teeth, the 33.84% had only 4 impacted wisdom teeth and 40 patients (20.20%) three.<sup>11</sup>

Traumatic injury to a primary tooth is an another factor that may lead to disturbance in eruption of permanent teeth.<sup>12</sup> It has been reported that any

-----  
Burcu BAŞ  
Ondokuz Mayıs University,  
Dental Faculty,  
Department of Oral and Maxillofacial Surgery,  
55139, Kurupelit, Samsun, Turkey.  
Tel: +90 3623121919/3480  
Fax: +90 3624576032  
e-mail: burcubas@omu.edu.tr

This paper was presented in ACBID. 4<sup>th</sup> International Congress. 26-30 May 2010, Antalya.

trauma during the stage of odontogenesis can seriously affect the morphogenetic stages of dental development, and several developmental alterations can arise in permanent teeth as a consequence of dental injuries and maxillofacial traumas.<sup>13</sup>

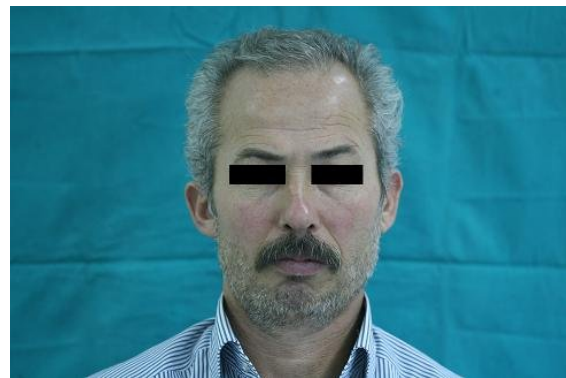In this case report, a rare case of a multiple impacted molar teeth with condylar hyperplasia probably as the results of trauma and its treatment is described. This is the first report in the literature that presents these two pathologies together in the same patient

### CASE REPORT

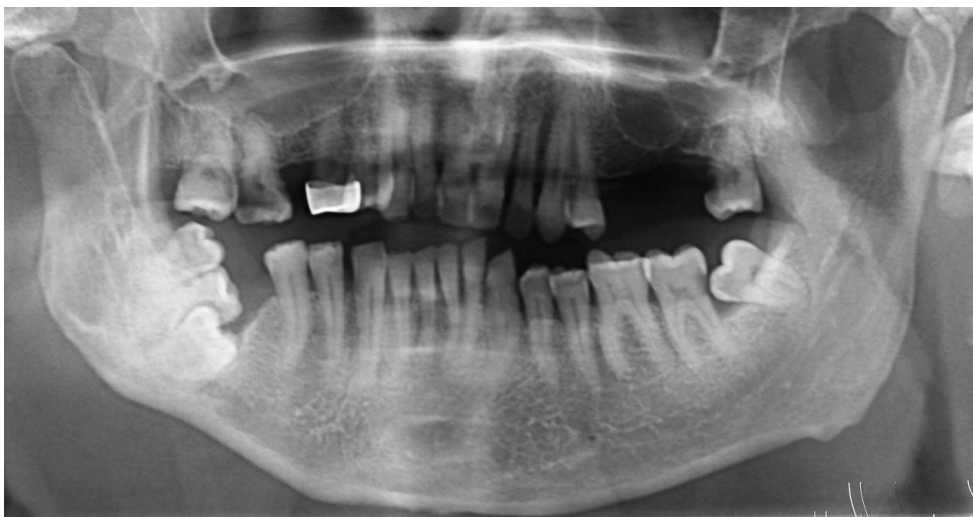A 48-year old male patient was referred to our clinic, with a complaint of pain on right retromolar region while chewing. Extra-oral examination revealed a slight asymmetry of the face. (Fig1) Mandibula was deviated to the right side and the chin was protruded to the right. Maximal mouth opening was 30mm with 4mm deviation to the right. However the patient had no complaint of facial asymmetry or restricted

mouth opening. The patient's medical history was uneventful.

Intraoral examination revealed the absence of right mandibular first and second molar while the third molar was partially erupted. There was a swelling and ulceration at the overlying mucosa of the molar region. The panoramic radiograph revealed the presence of impacted three mandibular molars and a morphological alteration of the condyle and coronoid process, at the right side (Figure 2).

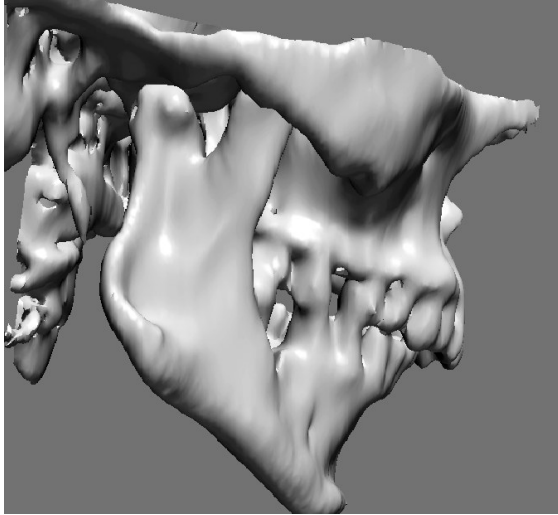


**Figure 1.** Extraoral view of the patient showing a slight asymmetry of the face.



**Figure 2.** Panoramic radiography of the patient. The presence of impacted three mandibular molars and a morphological alteration of the condyle and coronoid process, at the right side.

There was a substantial increase in length and thickness of the condyle. The first mandibular molar tooth was deeply embedded in bone, above the basis of the mandible in a mesioangular position and the second molar was located above the first molar tooth at the same position.



**Figure 3.** 3-D tomographic view of the hyperplastic condyle and coronoid process.

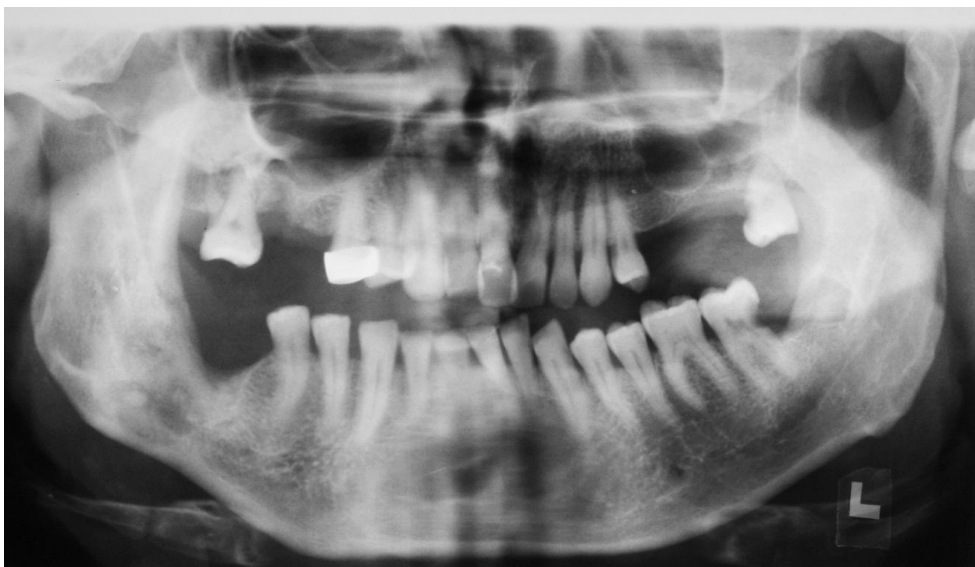The partially erupted third molar tooth was above the second molar and located at the ramus of the mandible in a mesioangular position. There was also a

bone defect between the impacted molars and adjacent second premolar teeth.

Tomograms of the TMJ demonstrated enlargement of the right condylar head and coronoid process to about twice its normal size in all dimensions with flattening of the superior articular tubercle (Figure 3).

The sigmoid notch was extremely narrow. Scintigraphy results showed no active center of ossification. The patient postponed surgical intervention for condylar hyperplasia and facial recontouring. Only the removal of impacted teeth was planned.

Informed consent form was obtained from the patient. Surgical removal of the three impacted teeth were performed under general anesthesia. Reconstruction plate (RP) with 8 holes and 4 monocortical screws was applied after the extraction. Although alveolar neurovascular bundle was visualized and protected in the operation a temporary paresthesia was seen after the operation. However, the patient had return of neurological function 3 months after the surgery. Reconstruction plate was removed 6 months after the surgery and six months radiographic and clinic follow up were satisfactory (Figure 4).



**Figure 4.** Six months postoperative panoramic radiography of the patient.

## DISCUSSION

Multiple impacted teeth are a rare condition and often found in association with syndromes such as cleidocranial dysplasia, Gardner's syndrome, Down syndrome, Aarskog syndrome, Zimmerman-Laband syndrome and Noonan's syndrome. Impaction of multiple teeth without an associated syndrome or systemic condition, are rare in the literature.<sup>14-18</sup> After a detailed family and medical history no association with any of these syndromes was found in our case.

Traumatic injury to a primary tooth may lead to developmental disturbance of permanent dentition. The highest prevalence of developmental disturbances of permanent teeth were found after intrusive injuries of primary teeth.<sup>19</sup> Primary tooth intrusion may result in a variety of pathologic alterations to permanent teeth, including hypoplasia, crown dilacerations, root angulations or dilacerations, partial or complete arrest of root formation, sequestration of the permanent tooth germ, and disturbances in eruption.<sup>12</sup> In our case there was adequate place for eruption and no abnormalities of the crown and root morphology of the impacted teeth. Therefore it was thought that the possible etiology of impaction may be the transposition of the first and second molar germs.

Unilateral condylar hyperplasia is a condition, which includes progressive enlargement of the condyle and displacement of the mandibular midline to the contra lateral side. Obwegeser and Makek have reviewed the possible etiologic factors for hemimandibular hyperplasia and unilateral condylar hyperplasia.<sup>20</sup> These factors include: cartilaginous exostosis, articular arthrosis, vascular disturbance in the condylar region, trauma and hormonal disturbance. There are reports of cases in which condylar trauma occurred in childhood and

later in adulthood manifested itself as hyperplastic growth.<sup>21,22</sup>

In a prospective study of 38 growing patients with fractures of the condylar neck, Lund found that compensatory growth occurred on the affected side, and no significant facial asymmetry developed greater than normal in a majority of the subject.<sup>23</sup> In the same study, a remarkable potential for post-traumatic condylar remodeling was noticed, which in some instances resulted in close to complete regeneration of a new mandibular head. In some instances Wiltfang et al. examined 29 patients who have had childhood condylar fractures and 13 patients with childhood mandibular body fractures combined with condylar fractures, and reported 2/3 of these patients to show growth retardation on the condylar fracture side whereas 1/3 demonstrated more pronounced growth on the fracture side compared to the non-fracture side.<sup>24</sup> In our case, along with the condylar hyperplasia there was an extremely narrow sigmoid notch. In our opinion this was a result of an improper joining of fragments after a condylar neck fracture which was not noticed by the patient, probably in his childhood.

In this particular case, multiple impactions of three mandibular permanent molars and an abnormal condylar growth was detected on the right jaw. Medical and family history and extraoral examination were not suggestive of any syndrome or metabolic disorder. The patient stated no history of serious trauma. In our knowledge, this is the only report in the literature presenting of these two conditions together. We could not define whether these two abnormalities are associated to one another. The common etiological factors of these two conditions are syndromes and trauma sequel. Because no syndromes were found associated with the current case, early childhood or birth trauma that was not noticed by the patient

and his parents were thought to be the etiologic factor.

Treatment options for impacted teeth include observation, intervention, relocation, and extraction.<sup>25</sup> If they left untreated, impacted mandibular molars can create clinical problems such as root resorption, caries and periodontal breakdown of the adjacent molars.<sup>26</sup> An impacted tooth is located in a shallow position in the alveolar bone, may become exposed with advancing age and hence become infected.<sup>27</sup> Because the impacted teeth were exposed to the oral cavity and infected, In our case we extracted three of them. As teeth were impacted deeply, an extremely large cavity was occurred in the surgical site. Therefore we used a reconstruction plate to avoid the risk of a mandible fracture.

During the surgical removal of the impacted mandibular molars, nervus alveolaris inferior can be damaged. Careful peoperative assessment must be carried out radiologically in an attempt to identify the proximity of the impacted tooth to the inferior alveolar canal. In our case, although, alveolar nerve was visualized and seemed intact at the bottom of the cavity, the patient experienced paresthesia after the operation. However, he had full return of neurologic function 3 months after the surgery.

In conclusion; multiple impacted teeth is a rare condition. Condylar hyperplasia with presence of multiple impacted teeth in the same patient has not been reported in the literature before. This is the first report in the literature presenting of these two pathologies together. It can be associated with syndromes or trauma. Careful clinic and radiological examination should be performed in order to identify other possible associated abnormalities.

## REFERENCES

1. Raghoobar GM, Boering G, Vissink A, Stegenga B. Eruption disturbances of permanent molars: a review. *J*

*Oral Pathol Med* 1991;20(4):159-166. [\[CrossRef\]](#)

2. Alling CC, Catone GA. Management of impacted teeth. *J Oral Maxillofac Surg* 1993;51 (1 suppl):3-6. [\[CrossRef\]](#)
3. Türkkahraman H, Sayın ÖM. Five mandibular incisors: A case report]. *Turkiye Klinikleri JDental Sci* 2005;11(3):88-91.
4. Da Costa CT, Torriani DD, Torriani MA, da Silva RB. Central Incisor Impacted by an Odontoma. *J Contemp Dent Prac* 2008;9(6):1-7.
5. Celikoglu M, Kazancı F, Ceylan I. Unusual Supernumary Teeth and Impacted Permanent Teeth: Case report. *Turkiye Klinikleri J Dental Sci* 2009;15(3):244-248
6. Shah RM, Boyd MA, Wakil TF. Studies of permanent tooth anomalies in 7,886 Canadian individuals. I: Impacted teeth. *Dent J* 1978;44(6):262-264.
7. Grover PS, Lorton L. The incidence of unerupted permanent teeth and related clinical cases. *Oral Surg Oral Med Oral Pathol* 1985;59(4):420-425. [\[CrossRef\]](#)
8. Cho SY, Ki Y, Chu V, Chan J. Impaction of permanent mandibular second molars in ethnic Chinese schoolchildren. *J Can Dent Assoc* 2008;74(6):521.
9. Liu JK, Hsiao CK, Chen HA, Tsai MY. Orthodontic correction of a mandibular first molar deeply impacted by an odontoma: a case report. *Quintessence Int* 1997;28(6):381-385.
10. Bayar GR, Ortakoğlu K, Sencimen M. Multiple Impacted Teeth: Report of 3 Cases. *Eur J Dent* 2008;2(1):73-78.
11. Kamberos S, Kolokoudias M, Fanourakis I, Merentitis N. Multiple impaction teeth. Clinical and radiological study in patients with three or more impacted teeth.

- Odontostomatol Proodos 1990; 44(4):275-281.
12. Diab M, elBadrawy HE. Intrusion injuries of primary incisors: Part III: Effects on the permanent successors. Quintessence Int 2000;31(5):377-384.
  13. Gungormus M, Yolcu U, Aras MH, Halicioglu K. Simultaneous occurrence of compound odontoma and arrested root formation as developmental disturbances after maxillofacial trauma: a case report. Med Oral Patol Oral Cir Bucal 2010;15(2):398-400. [\[CrossRef\]](#)
  14. Black SL, Zallen RD. An unusual case of multiple impacted teeth. Oral Surg Oral Med Oral Pathol 1974;37(6):975-976. [\[CrossRef\]](#)
  15. Finkel A, Solondz G, Friedman J. Multiple supernumerary and impacted teeth. Oral Surg Oral Med Oral Pathol 1974;37(6):976-977. [\[CrossRef\]](#)
  16. Yucel E. Multiple supplemental premolars. Oral Surg Oral Med Oral Pathol 1992;74(3):384.
  17. Yalcin S, Gurbuzer B. Multiple impacted teeth in the maxilla. Oral Surg Oral Med Oral Pathol 1993;76(1):130. [\[CrossRef\]](#)
  18. Yıldırım D, Yılmaz HH, Aydın U. Multiple impacted permanent and deciduous teeth. Dentomaxillofac Radiol 2004;33(2):133-135.
  19. Von Arx T. Developmental disturbances of permanent teeth following trauma to the primary dentition. Aust Dent J 1993; 38(1):1-10.
  20. Obwegeser HL, Makek MS. Hemimandibular hyperplasia--hemimandibular elongation. J Maxillofac Surg 1986;14(4):183-208. [\[CrossRef\]](#)
  21. Jakobsen LP, Ullmann R, Christensen SB, Jensen KE, Mølsted K, Henriksen KF, et al. Pierre Robin sequence may be caused by dysregulation of SOX9 and KCNJ2. J Med Genet 2007;44(6):381-386.
  22. Rubenstein LK, Campbell RL. Acquired unilateral condylar hyperplasia and facial asymmetry: report of case. ASDC J Dent Child 1985;52(2):114-120.
  23. Lund K. Mandibular growth and remodelling processes after condylar fracture. A longitudinal roentgencephalometric study. Acta Odontol Scand Suppl 1974;32(64):3-117.
  24. Wiltfang J, Halling F, Merten HA, Luhr HG. Mandibular condyle fractures in childhood: effects on growth and function. Dtsch Zahnarztl Z 1991;46(1):54-56.
  25. Kalia V, Aneja M. Mandibular Premolar Impaction: case report. Scholarly Research Exchange 2009; 2; 1-3.
  26. Frank C. Treatment options for impacted teeth 2000 JADA 131(5):623-632.
  27. Yamaoka M, Furusawa K, Ikeda M, Hasegawa T. Root resorption of mandibular second molar teeth associated with the presence of the third molars. Aust Dent J 1999;44(2):112-116. [\[CrossRef\]](#)