



Gingival Augmentation of the Edentulous Site Before Implant Placement Using a Transposed Pedicled Gingivectomy Tissue: A Novel Surgical Case Report

Manikandan Narasimman^{1-a}, Shashikiran Shanmugasundaram^{1-b}, Aditi Chopra^{1-c*}

¹ Department of Periodontology, Manipal College of Dental Sciences, Manipal, Manipal Academy of Higher Education, Manipal, Karnataka, India 576104.

*Corresponding author

Case Report

History

Received: 07/10/2023
Accepted: 28/09/2024

License



This work is licensed under
Creative Commons Attribution
4.0 International License

ABSTRACT

The amount of keratinized gingiva around teeth/prostheses is a crucial factor to consider before placing the crowns and bridges around implants or edentulous teeth. Keratinized gingiva around teeth, edentulous sites or implants is an important as it improves aesthetics, helps to maintain good oral hygiene around prosthesis, and prevents post-operative exposure of implant threads. The presence of adequate keratinized tissue around implants/prostheses is vital for good peri-implant health and should be augmented before implant treatment to improve the overall prognosis of the implants. The attached gingiva can be augmented using a free gingival graft (FGG) or AlloDerm®. However, procurement of FGG is surgically demanding as it requires procurement of the tissue graft from the palate. Moreover, it creates a second surgical site with an increased risk of post-operative discomfort and bleeding. To overcome these limitations, this case report presents a novel non-invasive simple, surgical technique to augment keratinized tissue using partially excised pedicled gingivectomy tissue for augmenting attached gingiva before prosthetic rehabilitation.

Keywords : Mucogingival surgery, Minimally invasive surgery, Implant, Attached gingiva, Gingivectomy, Gingiva, Edentulous.

a n.manee11@gmail.com
c aditi.chopra@manipal.edu

<https://orcid.org/0000-0002-4897-8468> b shashi.ks@manipal.edu
 <https://orcid.org/0000-0003-4805-5943>

<https://orcid.org/0000-0002-0744-5593>

How to Cite: Narasimman M, Shanmugasundaram S, Chopra A. (2024) Gingival Augmentation of the Edentulous Site Before Implant Placement Using a Transposed Pedicled Gingivectomy Tissue: A Novel Surgical Case Report, Cumhuriyet Dental Journal, 27(3): 209-213.

Introduction

The periodontium is the attachment apparatus that anchors the teeth in the jaws and facilitates effective masticatory function.¹ The periodontium has two main components: the gingiva and the supporting apparatus. Gingiva has three main components: papillary, marginal, and attached gingiva.¹ The attached gingiva is the most critical portion, as it protects the underlying structures from external forces, enhances aesthetics, and supports good oral hygiene. The amount of attached gingiva varies among individuals and different teeth. For example, the attached gingiva is maximum in anterior teeth (3-4 mm) and least in the premolar region (1-

1.8 mm).² The amount of keratinized gingiva is influenced by the patient's periodontal biotype¹, the gingiva's thickness, and the alveolar bone's morphology.³ Thin periodontal biotypes that exhibit narrow zones of keratinized gingiva are more prone to gingival recession.^{3,4,5} The amount of keratinized gingiva also diminishes following the extraction of teeth due to the remodeling of the underlying alveolar bone.⁶

The presence of a minimum width of keratinized gingiva is required for good periodontal and peri-implant health.⁷ The presence of adequate attached gingiva helps to brace the marginal gingiva, protects the underlying bone, and improves gingival aesthetics. Augmenting

attached gingiva around deficient areas around implants is important since an adequate amount of peri-implant keratinized tissue is needed to prevent soft tissue recession and exposure of the implant surface.⁸ Previous studies have shown that individuals with 2 mm of keratinized tissue and 1 mm of attached gingival width of about 1mm are important to maintain periodontal health.^{3,4} However, some authors have stated that in the presence of optimal oral hygiene measures, a minimum amount of keratinized tissue is not a requisite for periodontal and peri-implant health.^{3,4} Some reports have shown that individuals with inadequate peri-implant keratinized tissue tend to high risk of developing peri-implant diseases.⁹ The chances of a peri-implant recession and exposure to implant threads are increased in patients with inadequate keratinized tissues.¹⁰ A 10-year prospective study showed that implant sites lacking keratinized tissue exhibit increased plaque accumulation and greater gingival recession.⁸ A recent systematic review and meta-analysis also emphasized the importance of augmenting keratinized tissue around implants; procedures aimed at augmenting the zone of keratinized tissue around implants and prostheses should be planned before implant placement and prosthetic rehabilitation to achieve better peri-implant soft tissue health, better plaque control, and good marginal bone

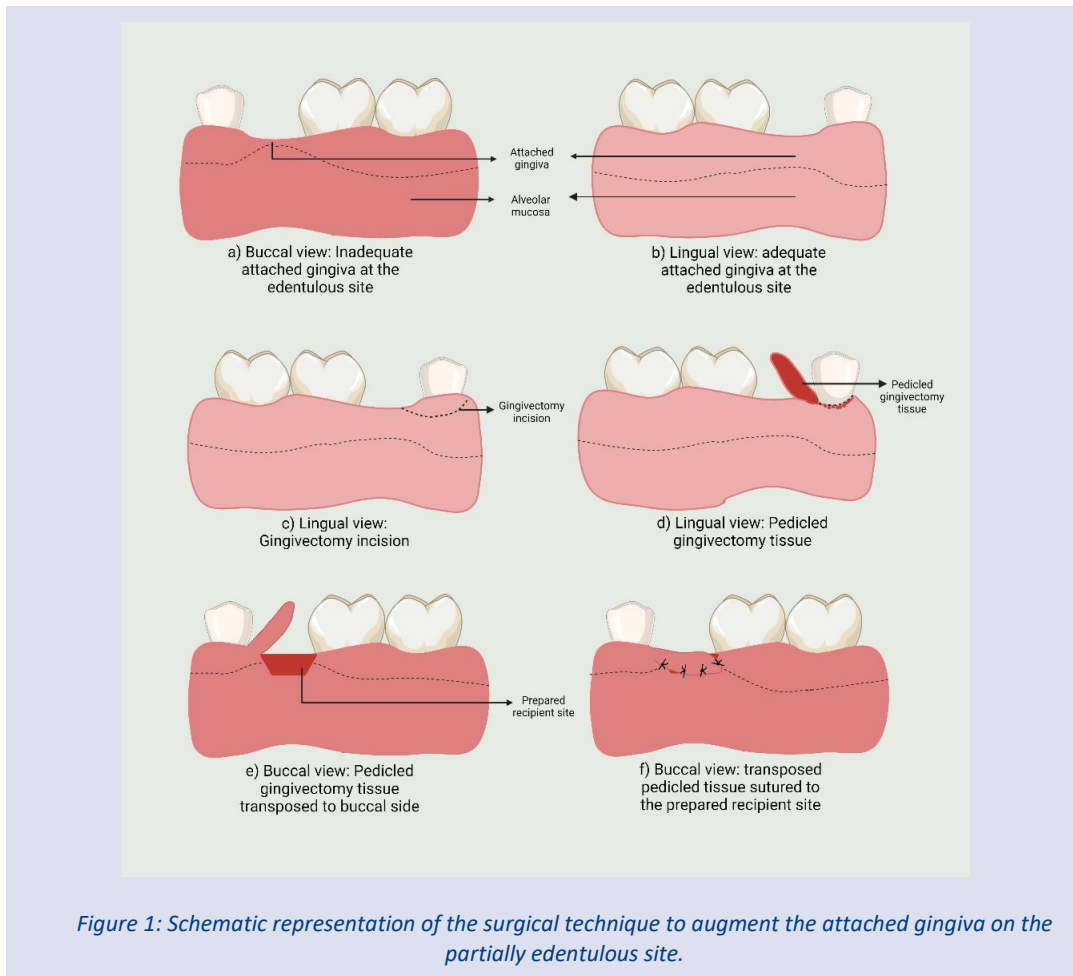
support.¹¹ Based on this evidence, the evaluation, and augmentation of keratinized gingiva around the edentulous the area before implant placement or around the existing implant becomes important to predict the dimensions of future peri-implant mucosa.^{12,13} Although many studies discuss the importance of a prosthesis with optimal contact, contour, and margins; the presence of adequate attached gingiva around the prosthesis is often overlooked or unconsidered in the treatment plan.

Gingival augmentation is usually done by using an autogenous free gingival graft (FGG) or commercially available AlloDerm®.¹⁴ The FGG is most often harvested from the hard palate, retromolar pad, or an edentulous site.¹⁵ However, the major drawbacks involved with the procurement of FGG are the need for an additional surgical site, prolonged surgical time increased patient discomfort, risk of post-operative bleeding, and limited availability of donor tissue.¹⁶ Additionally, in many patients, a whitish color scar or patch appears at the site of the graft due to inadequate color matching.¹⁶ The procurement of soft tissue graft is also a technique-sensitive procedure as it requires good clinical surgical skills. To overcome these problems, the present case

report presents a novel, simple, and minimally invasive surgical procedure to augment the attached gingiva on an edentulous site planned for implant by using the partial gingivectomy tissue graft.

Methods

A 49-year-old female was referred to the Department of Periodontology with a chief complaint of a dislodged crown for the mandibular left first premolar. The patient was systemically healthy without any oral abusive habits. The patient was currently not on any medication or therapy. Her dental history included a scaling procedure performed six months ago. The root canal treatment was done, and the crown was placed for the left mandibular first premolar (34). The crown was dislodged a month back (Figure 1). On the first visit, clinical examination revealed supragingival and subgingival calculus along with an amalgam restoration in the root canal-treated first premolar. The gingiva was inflamed with a grade 1 score for gingival bleeding. There was inadequate clinical crown height with a crown-to-root ratio of 1:2.



A crown lengthening procedure was planned for the tooth followed by re-restoration with a post and core procedure. The rehabilitation of the edentulous site was planned with endosseous implants. However, before

implant placement, we noticed an inadequacy of the attached gingiva in both the tooth's buccal aspect and the edentulous region where a dental implant was to be placed to replace the missing teeth. The patient was

informed and educated about the problem and written consent was obtained. The patient was also informed about the use of FGG for gingival augmentation for the edentulous site, to which the patient denied the procurement of a free gingival graft from the palate. Since the gingivectomy tissue is usually discarded, we planned to use the same tissue excised for crown lengthening on the lingual side for gingival augmentation. However, instead of excising the tissue completely and using it as a gingival unit, we planned to transpose the tissue as a pedicle to maintain the blood supply from one end and adapt it onto the de-epithelized bed onto the edentulous site. The surgical plan involved increasing the width of the attached gingiva while simultaneously increasing the crown height. This was achieved with an apically positioned flap on the buccal aspect and an external bevel gingivectomy on the lingual aspect of the tooth.

Surgical Procedure

The procedure was performed under local anesthesia (infiltration) with 2% lignocaine hydrochloride with 1:80,000 adrenaline. A crevicular incision using a No. 15c Bard Parker blade was made on the buccal aspect of the tooth. A mesial vertical releasing incision was given. An external bevel incision was given a 15C blade on the lingual side, 3 mm away from the lingual marginal gingiva

from the mesial to the distal end of the tooth. The distal end of the incision continued as a distal vertical releasing incision on the buccal aspect. A full-thickness mucoperiosteal flap was reflected on the buccal aspect using a periosteal elevator and osseous reduction of the marginal bone was done with a small round bur under copious irrigation. The excised tissue from the lingual side with the distal end still attached to the buccal flap was rotated and transposed onto the buccal side as a wing of the buccal flap. The edentulous area, distal to 34, was de-epithelialized using a surgical blade. The partially excised gingivectomy tissue was transposed on the de-epithelialized bed (Figure 1 and Figure 2). The flap was sutured apically on the buccal aspect using an interrupted suturing technique (3-0 sutures, Ethicon Mersilk, Johnson and Johnson, USA) and winged gingival tissue was sutured distally to 34 onto the de-epithelialized bed as one unit. A periodontal dressing was placed (CoePak, GC American INC, USA), and a postoperative analgesic (Ibuprofen 400 mg thrice a day) for the two days was advised. The patient was instructed not to brush in the surgical area for a week and was advised to rinse with warm saline water 2-3 times a day for a week. The patient was asked to inform in case of excessive pain, bleeding, or swelling. The patient was recalled after 15 days for the removal of sutures.

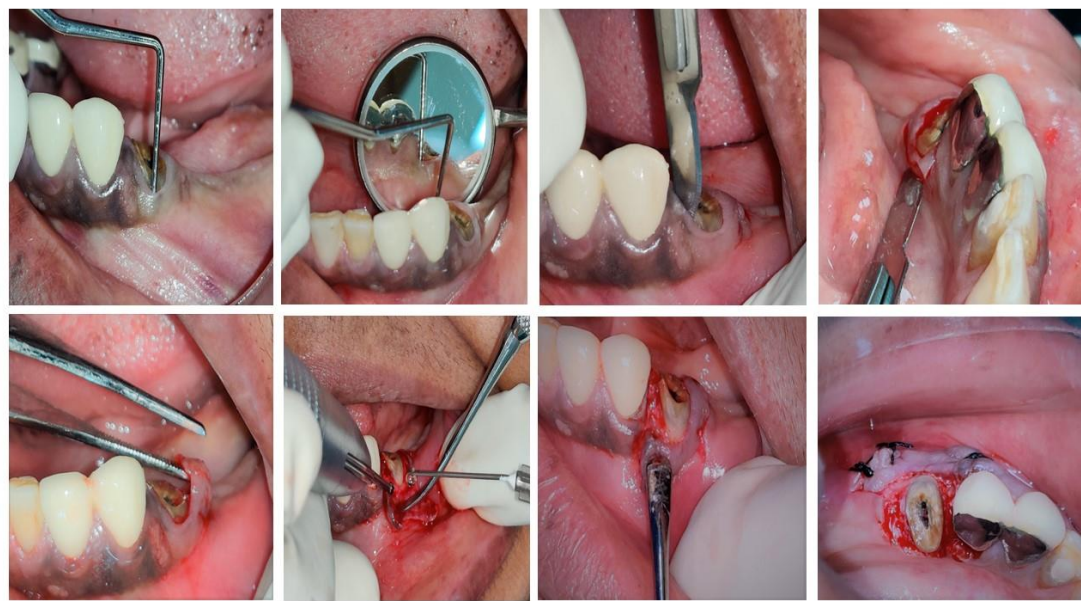


Figure 2: Clinical pictures explaining the steps of the surgical procedure where the partially excised gingivectomy tissues are transposed onto the buccal aspect for gingival augmentation:

Fig 2A: Pre-operative images showing the inadequate crown height of the left mandibular premolar along with the edentulous area with inadequate attached gingiva on the buccal side.

Fig 2B: Pre-operative images showing the inadequate crown height of the left mandibular premolar along with the edentulous area with inadequate attached gingiva on the buccal side.

Fig 2C: Sulcular incision given with 15C blade on the buccal side

Fig 2D: External bevel incision on the lingual side

Fig 2E: Lingual tissue was reflected and transposed to the buccal side

Fig 2F: Osseous re-contouring done with a round bur

Fig 2G: Apical repositioning of the flap and with lateral position of transposition of the gingival tissue obtained from the lingual side

Fig 2H: Flap approximated with interrupted suturing using 3-0 silk suture

Results

After 15 days, the pedicled gingival tissue extension was successfully taken up by the recipient bed without any signs of gingival inflammation or necrosis [Figure 2 and Figure 3]. An increase in the width of the keratinized gingiva was noted at base 34 and the edentulous area. Reevaluation at 15 days, 6,

and 12 months revealed excellent blending and firm attachment of the pigmented tissues with an increase of 2-3 mm in width of the attached gingiva [Figure 3]. No postoperative complications were reported at the surgical site immediately after the surgery and even at 12 months follow-up good healing and plaque control was observed.

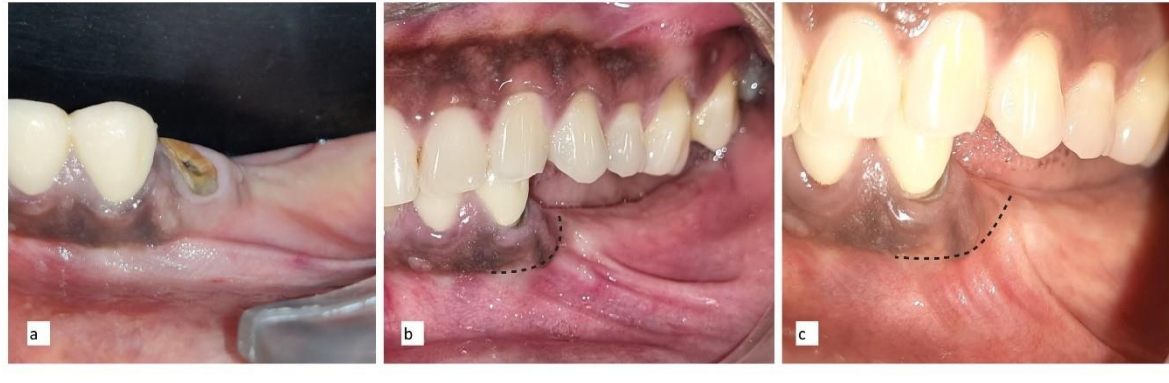

Figure 3: Clinical images showing the increase in the width of the attached gingiva

Fig 3A: Preoperative clinical image at baseline

Fig 3B: Post-operative clinical image at 6 months

Fig 3C: Post-operative clinical image at 12 months

Discussion

The presence of adequate attached gingiva around the implant and tooth prosthesis is vital and should be evaluated before any prosthetic rehabilitation. Although FGG is considered the gold standard for gingival augmentation, many times patients deny procurement of graft from the palate, and seek simpler and non-invasive options. The use of gingivectomy tissues as gingival graft has been documented as a viable alternative to free gingival graft for gingival augmentation. Jenabian et al (2016) compared the efficacy of the gingival unit graft compared to FGG and found that the gingival unit graft produced higher satisfaction aesthetically, higher healing index ($P < 0.001$), higher root coverage percentage at one month after surgery ($P=0.011$) and greater reduction of recession width three months after surgery ($P=0.007$). However, the reduction in vertical height of the recession was not significantly greater with gingival unit graft compared to FGG.¹⁷ The use of gingival unit graft has higher patient acceptance and less surgical demand compared to FGG.

This modification is similar to the gingival unit graft, where a gingival tissue will be excised and discarded for crown lengthening or aesthetic reasons, instead of discarding the excised tissue, one can utilize it for gingival augmentation in the same patient. This technique was designed based on the concept of utilizing the gingival unit, with the additional advantage of maintaining the blood supply by keeping one part of the excised gingivectomy tissue and transposing it to an adjacent site. Unlike gingival tissue, transposing the partially excised

gingivectomy tissue as a pedicle graft provides faster healing as the blood supply to the donor tissue is maintained. This technique can be attempted for shallow single-tooth recession with interdental spacing, where the excised gingivectomy tissue from the lingual side can be transposed to the buccal side and sutured as graft. This would reduce the post-operative discomfort of the patient and steer away from the complications of increased risk of bleeding as seen in the FGG. It can also be performed for coverage of implant thread by transposing the gingival tissue from the adjacent tooth from the lingual to the buccal aspect. However, this technique can only be used adjacent to a natural tooth that has adequate keratinized tissue around it, and when interdental space for transferring the donor tissue from the lingual side to the buccal side (wide embrasures, spacing between the teeth, edentulous areas) is optimal. The choice to excise partial or full thickness depends on the gingiva phenotype and the lingual tissues' thickness.

Conclusions

The present technique was effective in augmenting keratinized tissue at an edentulous site planned for an implant. The augmented gingival tissue was healthy, and the width was maintained even after one year. However, one should note that the success of this technique does not confirm its effectiveness as future studies should explore and compare the efficacy of this technique compared to FGG via performing prospective clinical studies with long-term follow-ups.

Conflict of Interest

No potential conflict of interest to report

Funding

Nil.

Patient consent

Verbal and written signed consent was taken before the surgery/ rehabilitation.

References

- Newman MG, Takei HH, Klokkevold PR, Carranza FA. Newman and Carranza's clinical periodontology / [edited by] Michael G. Newman, Henry H. Takei, Perry R. Klokkevold, Fermin A Carranza. 2019; 1–994.
- Ainamo J, Löe H. Anatomical characteristics of gingiva. A clinical and microscopic study of the free and attached gingiva. *J Periodontol* 1966; **37**: 5–13.
- Cortellini P, Bissada NF. Mucogingival conditions in the natural dentition: Narrative review, case definitions, and diagnostic considerations. *J Periodontol* 2018; **89** Suppl 1: S204–S213.
- Kim DM, Neiva R. Periodontal soft tissue non-root coverage procedures: a systematic review from the AAP Regeneration Workshop. *J Periodontol* 2015; **86**: S56–S72.
- Kim DM, Bassir SH, Nguyen TT. Effect of gingival phenotype on the maintenance of periodontal health: An American Academy of Periodontology best evidence review. *J Periodontol* 2020; **91**: 311–338.
- Araujo MG, Lindhe J. Peri-implant health. *J Clin Periodontol* 2018; **45** Suppl 20: S230–S236.
- Mehta P, Peng LL. The width of the attached gingiva—Much ado about nothing? *J Dent* 2010; **38**: 517–525.
- Roccuzzo M, Grasso G, Dalmaso P. Keratinized mucosa around implants in the partially edentulous posterior mandible: 10-year results of a prospective comparative study. *Clin Oral Implants Res* 2016; **27**: 491–496.
- Schrott AR, Jimenez M, Hwang JW, Fiorellini J, Weber HP. Five- year evaluation of the influence of keratinized mucosa on peri-implant soft-tissue health and stability around implants supporting full-arch mandibular fixed prostheses. *Clin Oral Implants Res* 2009; **20**: 1170–1177.
- Kim BS, Kim YK, Yun PY, Yi YJ, Lee HJ, Kim SG et al. Evaluation of peri-implant tissue response according to the presence of keratinized mucosa. *Oral Surg Oral Med Oral Pathol Oral Radiol Endod* 2009; **107**. doi:10.1016/J.TRIPLEO.2008.12.010.
- Thoma DS, Naenni N, Figuero E, Hämmerle CHF, Schwarz F, Jung RE et al. Effects of soft tissue augmentation procedures on peri- implant health or disease: A systematic review and meta-analysis. *Clin Oral Implants Res* 2018; **29** Suppl 15: 32–49.
- Thoma DS, Lim HC, Paeng KW, Kim MJ, Jung RE, Hämmerle CHF et al. Augmentation of keratinized tissue at tooth and implant sites by using autogenous grafts and collagen-based soft-tissue substitutes. *J Clin Periodontol* 2020; **47**: 64–71.
- Heitz-Mayfield LJA, Salvi GE. Peri-implant mucositis. *J Clin Periodontol* 2018; **45** Suppl 20: S237–S245.
- Thoma DS, Benić GI, Zwahlen M, Hämmerle CHF, Jung RE. A systematic review assessing soft tissue augmentation techniques. *Clin Oral Implants Res* 2009; **20**: 146–165.
- Zucchelli G, Tavelli L, McGuire MK, Rasperini G, Feinberg SE, Wang HL et al. Autogenous soft tissue grafting for periodontal and peri- implant plastic surgical reconstruction. *J Periodontol* 2020; **91**: 9–16.
- de Resende DRB, Greggi SLA, Siqueira AF, Benfatti CAM, Damante CA, Raghianti Zangrando MS. Acellular dermal matrix allograft versus free gingival graft: a histological evaluation and split-mouth randomized clinical trial. *Clin Oral Investig* 2019; **23**: 539–550.
- Jenabian N, Yazdanpanah Bahabadi M, Bijani A, Rahimi Rad M, Yazdanpanah Bahabadi M. Gingival Unit Graft versus Free Gingival Graft for Treatment of Gingival Recession: A Randomized Controlled Clinical Trial. *Front Dent* 2016; **13**: 184–192.