



The Quantitative Method for Following Radiologic Healing in Endodontic Retreatment; 1-Year Follow-up Study and Retrospective Analysis

Serkan Yilmaz^{1-a}, Salih Duzgun^{2-b*}

¹ Specialist of Dentomaxillofacial Radiology, Department of Dentomaxillofacial Radiology, Ministry of Health, Mersin Oral and Dental Health Hospital, Mersin, Türkiye

² Department of Endodontics, Faculty of Dentistry, Erciyes University, Kayseri, Türkiye

*Corresponding author

Research Article

History

Received: 20/02/2023

Accepted: 12/12/2023

ABSTRACT

Objectives: This study aimed to quantitatively evaluate the changes in the internal bone structure at the periapical bone regions after retreatment in endodontics using fractal analysis method on periapical radiographs.

Materials and Methods: In this retrospective study, 29 single-rooted, asymptomatic, single-visit retreatment teeth with apical lesion were included. All teeth included in the study were selected from the maxilla anterior region. Periapical radiograph (T0) was taken for baseline diagnosis at the start of retreatment. Second periapical follow-up radiograph (T1) of the patients was taken at the end of 1 year. The first evaluation phase of the 1-year results of endodontic retreatment is based on the periapical index (PAI). Fractal dimension (FD) was calculated by box-counting method. Comparing T0 and T1 FDs was done using the paired-sample t-test. To compare FD changes between the gender, the independent samples t-test was used. The significance level was set to 0.05.

Results: PAI scores were found to be statistically significantly decreased in T1 radiographs compared to T0 ($p<0.001$). The mean FD value increased statistically significantly in T1 radiographs compared to T0 radiographs ($p<0.001$). No significant difference was found in the T0 and T1 radiographs of FDs in gender comparison ($p>0.05$).

Conclusion: At the end of the 1-year follow-up, FD increased in the periapical lesion area, which is interpreted as the healing of the lesions. Fractal analysis is recommended as a method that will benefit clinicians in the follow-up of retreatment recovery.

Keywords: Fractals, Retreatment, Diagnostic imaging, Periapical Periodontitis, Radiography

Endodontik Yeniden Tedavilerde Radyolojik İyileşmenin Takibi İçin Kantitatif Yöntem; 1-Yıllık Takip Çalışması

Süreç

Geliş: 20/02/2023

Kabul: 12/12/2023

ÖZ

Amaç: Bu çalışmada endodontide retreatment sonrası periapikal kemik bölgelerinde internal kemik yapısında meydana gelen değişikliklerin fraktal analiz yöntemi kullanılarak periapikal radyografiler üzerinde kantitatif olarak değerlendirilmesi amaçlanmıştır.

Gereç ve Yöntemler: Çalışmaya apikal lezyonu olan 29 adet tek köklü, asemptomatik, tek seans retreatment yapılan dişler dahil edildi. Çalışmaya dahil edilen tüm dişler maksilla anterior bölgesinden seçilmiştir. Retreatment başlangıcında temel tanı için periapikal radyografi (T0) çekildi. Hastaların 1. yıl sonunda ikinci periapikal kontrol grafileri (T1) çekildi. Endodontik retreatmentin 1 yıllık sonuçlarının ilk değerlendirme aşaması periapikal indekse (PAI) dayalıdır. Fraktal boyut (FB), kutu sayma yöntemiyle hesaplandı. The paired-sample t-testi T0 ve T1 FB'leri karşılaştırmak için kullanıldı. Cinsiyetler arasındaki FD değişikliklerini karşılaştırmak için bağımsız örneklem t testi kullanıldı. Anlamlılık düzeyi 0.05 olarak kabul edildi.

Bulgular: PAI skorları T1 grafilerde T0'a göre istatistiksel olarak anlamlı derecede düşük bulundu ($p<0.001$). Ortalama FB değeri T1 grafilerde T0 grafilere göre istatistiksel olarak anlamlı artış gösterdi ($p<0.001$). FB'lerin T0 ve T1 grafilerinde cinsiyet karşılaştırmasında anlamlı fark bulunmadı ($p>0,05$).

Sonuç: 1 yıllık takibin sonunda periapikal lezyon bölgesinde FB artışı lezyonların iyileşmesi olarak yorumlanmaktadır. Fraktal analiz, retreatment sonrası iyileşmenin takibinde klinisyenlere fayda sağlayacak bir yöntem olarak önerilmektedir.

Anahtar Kelimeler: Benzer elemanların oluşturduğu şekiller, Yeniden tedavi, Tanısal görüntüleme, Periapikal Apse, Radyografi

License



This work is licensed under
Creative Commons Attribution 4.0
International License

^a dtsalihduzgun@gmail.com

^b <https://orcid.org/0000-0002-0868-3390>

^b serkanyilmaza@gmail.com

^b <https://orcid.org/0000-0001-7149-0324>

How to Cite: Yilmaz S, Düzgün S. (2023) The Quantitative Method for Following Radiologic Healing in Endodontic Retreatment; 1-Year Follow-up Study and Retrospective Analysis, Cumhuriyet Dental Journal, 26(4):367-373.

Introduction

The main purpose of root canal treatment is to clean and shape the root canal system and fill the canal in three dimensions to prevent re-infection of the tooth.¹ Although the rate of success is high after the first root canal treatment, failures may occur over time after the treatment.² The main causes of failure are poorly formed canals, incomplete removal of infected pulp, persistent infections in the dentinal tubules or complex irregularities of the root canal system, and inadequate irrigation.^{1,3} Therefore, non-surgical root canal treatment applications are performed with a goal of making the tooth functional again. The main purpose of retreatment is the proper cleaning, reshaping, and refilling of the root canal system and the complete removal of filling materials, residues, and microorganisms from the first treatment.⁴ It is reported to be cost-effective and provides satisfactory results.⁵

During endodontic treatments, clinicians routinely use periapical radiographs because of advantages such as ease of use, detail and resolution, and low radiation dose.⁶ Clinicians often prefer periapical radiographs, especially for diagnosis, treatment, and postoperative follow-up. For most endodontic treatments, 1-year is considered as a sufficient time for a follow-up.⁶ Various radiographic indices are used to evaluate the development of periapical tissues on radiographs following root canal treatment.^{7,8} The periapical index (PAI) is one of the commonly used radiographic indices in healing follow-up; however, the acquired data remain subjective.^{7,8} Fractal analysis (FA), a new technique that has just come into use, calculates the complexity of the structure in the region of interest (ROI) and converts it into a numerical value. As a result, FA stands out as a method that allows for a quantitative evaluation.^{9,10} FA has also been employed as a bone density analysis tool and is now widely used because of how simple and accessible it is.^{11,12} It has been claimed that an increase in a structure's fractal dimension (FD) corresponds to an increase in the structure's complexity. Whereas low FD structures have a simpler internal design, high FD structures are more complex.^{9,10} The intricacy of the trabecular structure as a result of angiogenesis and bone remodeling is the explanation for increased FD.¹³ In addition, it is reported that FA can be used in the follow-up of patients after the treatment.^{10,14}

To the best of the author's knowledge, there is no study in the literature comparing the change in fractal size with non-surgical retreatment of single-root and canal teeth in the anterior maxilla and a 1-year follow-up. In this study, the authors aimed to quantitatively evaluate the changes in the internal bone structure in the periapical bone regions after retreatment in endodontics by fractal analysis method on periapical radiographs. The null hypothesis of the study is that there is no statistically significant difference between the FD of the end of the retreatment and the FD of the follow-up one year later.

Materials and Methods

Sample selection

This study was designed retrospectively. Ethical approval was obtained from the Local Ethics Committee (2022/710). The study protocol was carried out in accordance with the principles of the Declaration of Helsinki. The sample size was determined via power analyses of previous studies data. According to the power analysis (G*Power, ver. 3.1.9.2, Franz Faul; Universitat Kiel, Germany), a total sample size of 29 is required when $\alpha = 0.05$, and the effect size is 0.45, which would yield a power of 0.80.¹⁵

Periapical radiographs (T0) and 1-year follow-up radiographs (T1) taken immediately after retreatment of 29 individuals who were admitted to the endodontic clinic between 2020 and 2021 with indications for retreatment were used.

Inclusion criteria for the study;

- i) The individual does not have any systemic disease affecting bone metabolism,
- ii) The tooth with an indication for retreatment is a single root and single canal tooth located in the anterior maxillary region,
- iii) Asymptomatic of the involved tooth and radiographically determined as PAI score 3 or 4,
- iv) Absence of missing teeth,

Exclusion criteria from the study;

- i) The use of drugs that affect the individual's bisphosphonate-type bone metabolism,
- ii) Symptomatic tooth with an indication for retreatment,
- iii) Those who have disclosed having neurological and psychological disorders, alcoholism, and drug addiction diseases,

Retreatment Procedure

All retreatment procedure was completed in one visit by the same endodontist (S.D.). The tooth was isolated with a rubber dam after being anesthetized with Ultracaine® D-S (Sanofi Aventis, Levent, Istanbul). A high-speed handpiece was used to prepare an endodontic access using a round diamond bur No. 2 and an Endo-Z bur (Dentsply Maillefer, Ballaigues, Switzerland). The D1, D2, and D3 retreatment instruments (Dentsply Maillefer, Ballaigues, Switzerland) were used, with a 2-Ncm torque and 500-rpm speed, to remove primary root canal fillings. In a crown-down motion, the implements were used to brush against the canal sides. The working length was determined with an apex finder (ProPex Pixi, Dentsply Maillefer) and verified by radiography after all root filling had been removed. ProTaper rotary files (Dentsply Maillefer, Ballaigues, Switzerland) were then used to form the root canals up to an F5 (size 50) master apical file size. Using a side vented NaviTip irrigation needle, the canals were irrigated with 2 mL 2.5% sodium hypochlorite (NaOCl) between each file size (Ultradent, South Jordan, UT). Following the preparation, the canal was irrigated with 2 mL of 17% EDTA for 1 minute and then irrigated

with 2 mL of distilled water. Root canals were dried with paper points and obturated with gutta-percha (Dentsply Sirona) and resin-based sealer utilizing the cold lateral compaction technique (AH Plus, Dentsply Sirona). Resin composite was used to repair the coronal access cavity (3M ESPE, St Paul, MN, USA).

Radiographic Procedure

All periapical radiographs from the anterior maxillary region were obtained using the same device (Kodak 2100 Intraoral X-Ray System (Kodak, New York, USA)) with the same exposure parameters (60 kV, 7 mA, and 0.32 s radiation time). Also, size 2 (31×41 mm²) same phosphor plate is used. For maxillary anterior teeth, projection geometry was standardized with a film-retaining appliance, and images were taken in parallel technique in the same way. Latent images on phosphor plates were scanned and digitized. (Express; Instrumentarium, Tuusula, Finland). Images are saved as tagged image file format (TIFF).

1-Year Follow-up Evaluation

The first evaluation phase of the 1-year results of endodontic retreatment is based on the PAI.¹⁶ PAI is a 5-scores evaluation system. The PAI score for each subject was made according to the following definitions:

PAI 1: Ligament: Narrow and uniform width of the ligament space./Lamina dura: Radiopaque border uniform and regular.

PAI 2: Ligament: Slight increase of the width of the ligament space in and at foramen./Lamina dura: Border almost continuous.

PAI 3: Ligament: Slightly larger more irregular widening of the ligament space at foramen and/or around excess canal filling related to the demineralization process./Lamina dura: Loss of continuity of the bone border and disappearance at the foramen

PAI 4: Ligament: Well defined balloon-like radiolucency around apex and/or excess canal filling./ Lamina dura: Complete disappearance of the bone border.

PAI 5: Ligament: Shell like configuration around the radiolucency with extensions toward the radiolucent area around apex and/or excess canal filling. / Lamina dura: Complete disappearance of the bone border.

An experienced endodontist (S.D.) and dentomaxillofacial radiologist (S.Y.) evaluated the radiographs separately as T0 and T1 according to the PAI scoring system. Similar to earlier research, PAI scores were categorized as "healed" (PAI < 3) or "not healed" (PAI ≥ 3) at the baseline or 1-year follow-up.^{15,17,18}

Fractal Analysis

Images were obtained using a Dell Precision T5400 workstation with a 19-inch 1920 x 1080 resolution screen (Dell, Round Rock, TX, USA) (Dell E190S, China). A blinded dentomaxillofacial radiologist (S.Y.) performed fractal measurements after identifying ROIs from the subjects' periapical radiographs. The 64-bit Java-based open-source program Image J, version 1.53 was used to evaluate hard tissue (National Institutes of Health, Bethesda, Maryland,

USA). For standardization, all periapical radiographs were adjusted to have a width and height of 878x1144 pixels. ROI was selected from maxillary anterior teeth with apical lesions as in Figure 1 for baseline and 1-year follow-up radiographs. A square-shaped ROI of 30x30 pixels was placed in the geometric center of the apical lesion. The ROI was placed 1 mm more apical than the root of the tooth and not in contact with any anatomical structure such as the lamina dura. FD was performed using the customized method designed by White and Rudolph using the box-counting method¹⁹. Each image has been cropped and duplicated after the selection of ROI. This process has eliminated the brightness variance brought on by overlapping soft tissues and different bone densities. The outcome image has been taken away from the starting image. Binary was created by thresholding on a brightness value of 128 and adding a grey value of 128. After being eroded and dilated, the image was inverted. The image was skeletonized towards the end (Figure 2). The FD of the skeletonized image was calculated by using the box-counting method. The intra-observer reliability was assessed using 15 radiographs that were chosen at random. Two weeks following the initial assessment, the same dentomaxillofacial radiologist underwent a second examination for the intra-observer reliability while keeping them blind to the initial measurements.

Statistical Analysis

Software called SPSS v.23 was used to do the statistical analysis (IBM Statistical Package for Social Sciences, version 23.0; SPSS Inc., Chicago, Illinois, USA). Mean and standard deviation were used to summarize continuous variables. Frequencies and percentages were used to display categorical variables. The inter-observer Cohen's kappa coefficient with a 95% confidence interval was calculated for the PAI scores. Values 0 were defined as no agreement by Landis and Koch, whereas 0-0.20, 0.21-0.40, 0.41-0.60, 0.61-0.80, and 0.81-1 were classified as slight, fair, moderate, substantial, and virtually perfect agreement, respectively.²⁰ The ICC value was used to assess the accuracy of repeated intra-observer fractal dimension assessments. Values less than 0.5, between 0.5 and 0.75, between 0.75 and 0.9, and greater than 0.90 are indicative of poor, moderate, good, and exceptional dependability, respectively, according to the 95% confidence range of the ICC estimate.²¹ Shapiro-Wilk and Kolmogorov-Smirnov tests were used to figure out how the data were distributed. In radiograph ROI changes and independent samples t-tests, gender differences were assessed. Comparing T0 and T1 FDs was done using the paired-sample t-test. The PAI score changes were compared using the Wilcoxon test. The threshold for significance was set at 0.05.

Results

The demographic information about the patients is shown in Table 1. The mean age of the individuals by gender was 42.1±11.9 for males and 36.3±10.7 for females. PAI scores were found to be statistically significantly decreased in T1 radiographs compared to T0

radiographs ($p < 0.001$). On T0 radiographs, a PAI score of 4 was observed in 15 teeth and a PAI of 3 in 14 teeth. PAI scores in all retreatment teeth show a pattern of healing (PAI 1 and PAI 2) at 1-year follow-up (Figure 3). On T1 radiographs, a score of PAI 2 was observed in 8 teeth, and a score of PAI 1 in 21 teeth. The kappa coefficient used for interobserver reliability during PAI scoring was 0.927 (almost perfect). The mean FD value increased statistically significantly in T1 radiographs compared to T0 radiographs ($p < 0.001$) (Table 2). No significant difference was found in the T0 ($p = 0.906$) and T1 ($p = 0.478$) radiographs of FDs in gender comparison. As a result of repeated in-observer measurements for FD, the ICC ranged from 0.914 to 0.972 with excellent reliability.

Discussion

Fractal analysis is a method that quantifies the complexity of bone trabeculation. An increase in FD indicates increased complexity, while a lower FD value indicates less trabeculation in the region of interest.²² It is reported in the literature that FD decreases when bone density decreases and FD increases when bone density and trabeculation increase.^{8-10,23} However, in order to accurately evaluate the change in FD, it should be supported by other findings such as clinical and radiographic improvement. In similar studies, repeated radiological evaluations using full-scale PAI have been shown to have an important long-term prognostic value in periapical disease follow-up.⁸ Therefore, in this study, periapical conditions were evaluated with PAI to determine whether the change in FD values after retreatment was due to the newly formed trabecular pattern or decalcification. There was a significant decrease in PAI scores after retreatment. Therefore, the reason for the significant increase in the FD value after retreatment was due to the increased trabeculation due to recovery.

According to the PAI system, which is the commonly used index in the literature in the analysis of radiographic findings, PAI 1 and 2 scores are reported as healing in most of the studies.^{8,15-17} In this study, the same scores were taken as a reference. A healing pattern (PAI 1 and PAI 2 scores) was observed at the end of 1 year in all 29 teeth included in this study. The success rate of endodontic retreatment ranges from 40% to 100%.²⁴ Although this study is compatible with these data, we think that the reason for the healing activity in all teeth is that only teeth with PAI 3 and PAI 4 scores were included in the study. The appearance of clinically symptomatic teeth in PAI 5 individuals was a reason for exclusion. In this study, the authors aimed to evaluate how fractal analysis would show results as a quantitative method for apical recovery. Therefore, the authors selected teeth with indications for retreatment from close classes based on observation, which are relatively more difficult to diagnose and follow-up healing. In other studies, the authors think that the healing score could not be reached within 1 year after the retreatment of PAI 5 teeth. In addition, in other studies,

retreatment was applied to teeth with two roots and more than one canal.^{15,17} In this study, retreatment was applied only to maxillary anterior single root and single canal teeth. The higher bone healing potential in the maxilla than in the mandible is another reason for the higher healing rate of the teeth in this study. In addition, the absence of a study in which healing was followed by fractal analysis with a similar retreatment in the maxilla reveals the originality of this study and its difference from other studies.

It has been reported that fractal analysis results are affected by the location and size of the ROI.⁸ In order not to be affected by this situation, ROI was placed in the same size and in the same location (1 mm away from the tooth apex to the lesion center) on T0 and T1 radiographs. In addition, the ROI was chosen not to include surrounding anatomical structures such as tooth roots and lamina dura.⁹ Thus, changes occurring only in the lesion area were evaluated. In addition, T0 and T1 radiographs should be taken with similar projection angles and image quality.¹⁵ Therefore, when taking periapical radiographs, the conditions that would affect FD in follow-up radiographs were eliminated by taking images with the same devices and phosphor plates in the same exposure parameters, with the parallel technique film holding apparatus and patient positioning the same. The parallel technique is primarily recommended for endodontic periapical radiographs as it allows projections with minimal geometric distortion and has a high level of repeatability which is useful for comparison with other radiographs throughout a procedure.⁶ Periapical trabecular pattern changes can be determined by using fractal analysis in the early healing period in endodontic treatments and developments can be evaluated with numerical data.⁸ Compared to other quantitative methods such as subtraction radiography, fractal analysis is a more objective and less restrictive method.¹⁰ In addition, it reduces possible inter-investigator variation.²⁴ For this reason, as in many studies, fractal analysis was used in this study to reduce the disadvantages of traditional evaluation methods.^{22,24}

In previous studies, researchers reported that FD can be used to beneficially monitor healing and reveal structural changes in trabecular bone after root canal treatment.²⁴ In addition, the investigators noted that FD values increased significantly around the root apex and adjacent to the apical lesion, respectively, after 1 year following the root canal treatment for cases that eventually healed completely.²⁴ In similar studies, it has been reported that FD increases significantly in follow-up radiographs in teeth with lesions that underwent root canal treatment or retreatment.^{8,10} In this study, a statistically significant difference emerged in the baseline and 1-year follow-up radiographs of FD. The mean FD value of the 1-year follow-up radiographs was higher than the FD value of the baseline radiographs. This shows that with the increase in FD, the re-trabeculation seen in the apical region and the healing in the complexity of the region are provided.¹⁰ In similar studies, the authors reported that FD increased in one-year follow-up in single-

visit and multi-visit retreatment. In these studies, follow-up results of retreatment of posterior mandibular teeth were revealed.^{15,17} In the case of lesions compatible with apical periodontitis in both roots, the root with a high PAI score was included in the study.^{15,17} It is controversial whether different factors affect the healing process, such as the fusion of apical lesions, the fact that the roots have more than one canal, and the inclusion of symptomatic and asymptomatic teeth in the study. Therefore, in this study, retreatment applied exclusively on anterior maxillary single-rooted and single-canal teeth were included. Also, the authors consider that standardization and limiting environmental factors will create higher accuracy of results. This study has results consistent with other similar follow-up FD studies in the literature. In this study, there was no significant gender difference between T0 and T1 follow-up radiographs of FD values. Similarly, studies in the literature have shown that FD does not differ by gender.^{8,15,17} However, there are also studies reporting that the recovery following root canal treatment is lower in male than in female, and on the contrary, a higher success rate in male.²⁵ Differences in these results can be explained by differences in population, age range, evaluation method, follow-up time, lesion diameter, and tooth group. According to results, the null hypothesis was rejected.

Conclusion

At the end of the 1-year follow-up, FD increased in the periapical lesion area, which is interpreted as the healing of the lesions. It is reported that fractal analysis quantitatively reveals the changes in the trabeculations of the damaged periapical bone before retreatment. Fractal analysis is recommended as a method that will support clinicians in the follow-up of retreatment recovery.

Acknowledgments

Not applicable.

Funding

This research did not receive any specific grant from funding agencies in the public, commercial, or not-for-profit sectors.

Conflict of interest

The authors declare no conflict of interest.

References

1. Torabinejad M, Corr R, Handysides R, Shabahang S. Outcomes of nonsurgical retreatment and endodontic surgery: a systematic review. *J Endod.* 2009; 35: 930-937. <https://doi.org/10.1016/j.joen.2009.04.023>
2. de Chevigny C, Dao TT, Basrani BR. et al. Treatment outcome in endodontics: The Toronto study-phase 4: initial treatment. *J Endod* 2008; 34: 258-263. <https://doi.org/10.1016/j.joen.2007.10.017>
3. Peters OA, Barbakow F, Peters CI. An analysis of endodontic treatment with three nickel-titanium rotary root canal preparation techniques. *Int Endod J* 2004; 37: 849-859. <https://doi.org/10.1111/j.1365-2591.2004.00882.x>
4. Crozeta BM, Lopes FC, Menezes Silva R, Silva-Sousa YTC, Moretti LF, Sousa-Neto MD. Retreatability of BC Sealer and AH Plus root canal sealers using new supplementary instrumentation protocol during non-surgical endodontic retreatment. *Clin Oral Investig* 2021; 25: 891-899. <https://doi.org/10.1007/s00784-020-03376-4>
5. De-Deus G, Belladonna F, Zuolo A. et al. XP-endo Finisher R instrument optimizes the removal of root filling remnants in oval-shaped canals. *Int Endod J* 2019; 52: 899-907. <https://doi.org/10.1111/iej.13077>
6. Setzer FC, Lee S-M. Radiology in Endodontics. *Dent Clin N Am* 2021; 65: 475-486. <https://doi.org/10.1016/j.cden.2021.02.004>
7. Estrela C, Bueno MR, Azevedo BC, Azevedo JR, Pécora JD. A new periapical index based on cone beam computed tomography. *J Endod* 2008; 34: 1325-1331. <https://doi.org/10.1016/j.joen.2008.08.013>
8. Uğur Aydın Z, Ocak M, Bayrak S, Göller Bulut D, Orhan K. The effect of type 2 diabetes mellitus on changes in the fractal dimension of periapical lesion in teeth after root canal treatment: a fractal analysis study. *Int Endod J* 2021; 54: 181-189. <https://doi.org/10.1111/iej.13409>
9. Amuk M, Gul Amuk N, Yılmaz S. Treatment and posttreatment effects of Herbst appliance therapy on trabecular structure of the mandible using fractal dimension analysis. *Eur J Orthod* 2022; 44: 125-133. <https://doi.org/10.1093/ejo/cjab048>
10. Ozturk G, Dogan S, Gumus H, Soylu E, Sezer AB, Yılmaz S. Consequences of Decompression Treatment with a Special-Made Appliance of Nonsyndromic Odontogenic Cysts in Children. *J Oral Maxillofac Surg* 2022; 80: 1223-1237 <https://doi.org/10.1016/j.joms.2022.03.013>
11. Demiralp KÖ, Kurşun-Çakmak EŞ, Bayrak S, Akbulut N, Atakan C, Orhan K. Trabecular structure designation using fractal analysis technique on panoramic radiographs of patients with bisphosphonate intake: a preliminary study. *Oral Radiol* 2019; 35: 23-28. <https://doi.org/10.1007/s11282-018-0321-4>
12. Bollen A, Taguchi A, Hujuel P, Hollender L. Fractal dimension on dental radiographs. *Dentomaxillofac Radiol* 2001; 30: 270-275. <https://doi.org/10.1038/sj/dmfr/4600630>
13. Kaba YN, Öner Nİ, Amuk M, Bilge S, Soylu E, Demirbaş AE. Evaluation of trabecular bone healing using fractal dimension analysis after augmentation of alveolar crests with autogenous bone grafts: a preliminary study. *Oral Radiol* 2022; 38: 139-146. <https://doi.org/10.1007/s11282-021-00536-4>
14. Eninanç İ, Yeler DY, Çınar Z. Investigation of mandibular fractal dimension on digital panoramic radiographs in bruxist individuals. *Oral Surg Oral Med Oral Pathol Oral Radiol* 2021; 131: 600-609. <https://doi.org/10.1016/j.oooo.2021.01.017>
15. Tosun S, Karataslioglu E, Tulgar MM, Derindag G. Retrospective fractal analyses of one-year follow-up data obtained after single-visit nonsurgical endodontic retreatment on periapical radiographs. *Clin Oral Investig* 2021; 25: 6465-6472. <https://doi.org/10.1007/s00784-021-04079-0>
16. Ørstavik D, Kerekes K, Eriksen HM. The periapical index: a scoring system for radiographic assessment of apical periodontitis. *Dent Traumatol* 1986; 2: 20-34. <https://doi.org/10.1111/j.1600-9657.1986.tb00119.x>
17. Tosun S, Karataslioglu E, Tulgar MM, Derindag G. Fractal analysis and periapical index evaluation of multivisit nonsurgical endodontic retreatment: A retrospective study. *Oral Surg Oral Med Oral Pathol Oral Radiol* 2022; 133: 245-251. <https://doi.org/10.1016/j.oooo.2021.08.016>
18. Friedman S, Abitbol S, Lawrence HP. Treatment outcome in endodontics: The Toronto Study. Phase 1: initial treatment. *J*

Endod 2003; 29: 787-793. <https://doi.org/10.1097/00004770-200312000-00001>

19. White SC, Rudolph DJ. Alterations of the trabecular pattern of the jaws in patients with osteoporosis. Oral Surg Oral Med Oral Pathol Oral Radiol Endod 1999; 88: 628-635. [https://doi.org/10.1016/S1079-2104\(99\)70097-1](https://doi.org/10.1016/S1079-2104(99)70097-1)

20. Landis JR, Koch GG. The measurement of observer agreement for categorical data. Biometrics 1977: 159-174. <https://doi.org/10.2307/2529310>

21. Koo TK, Li MY. A guideline of selecting and reporting intraclass correlation coefficients for reliability research. J Chiropr Med 2016; 15: 155-163. <https://doi.org/10.1016/j.jcm.2016.02.012>

22. Kurşun-Çakmak EŞ, Bayrak S. Comparison of fractal dimension analysis and panoramic-based radiomorphometric

indices in the assessment of mandibular bone changes in patients with type 1 and type 2 diabetes mellitus. Oral Surg Oral Med Oral Pathol Oral Radiol 2018; 126: 184-191. <https://doi.org/10.1016/j.oooo.2018.04.010>

23. Aktuna Belgin C, Serindere G. Evaluation of trabecular bone changes in patients with periodontitis using fractal analysis: A periapical radiography study. J Periodontol 2020; 91: 933-937. <https://doi.org/10.1002/JPER.19-0452>

24. Huang C, Chen J, Chang Y, Jeng J, Chen C. A fractal dimensional approach to successful evaluation of apical healing. Int Endod J 2013; 46: 523-529. <https://doi.org/10.1111/iej.12020>

25. Swartz DB, Skidmore A, Griffin Jr J. Twenty years of endodontic success and failure. J Endod 1983; 9: 198-202. [https://doi.org/10.1016/S0099-2399\(83\)80092-2](https://doi.org/10.1016/S0099-2399(83)80092-2)

Table 1: Demographic Data

Variable	Frequency	Percent	Mean ± SD
Age (years)			39.2 ± 11.3
Patient (n)	29	100	
Gender (m/f)	11/18	37.9/62.1	

Table 2: Changes in T0 and T1 radiographs in FD after endodontic retreatment

Factor	Male (n = 11)	Female (n = 18)	p value	Total (n = 29)
T0 FD value	1.201	1.205	0.906	1.204
T1 FD value	1.288	1.307	0.478	1.300
p value	0.001*	0.001*		0.001*

T0: Baseline Radiograph; T1: 1 Year Follow-up Radiograph; *p<0.05

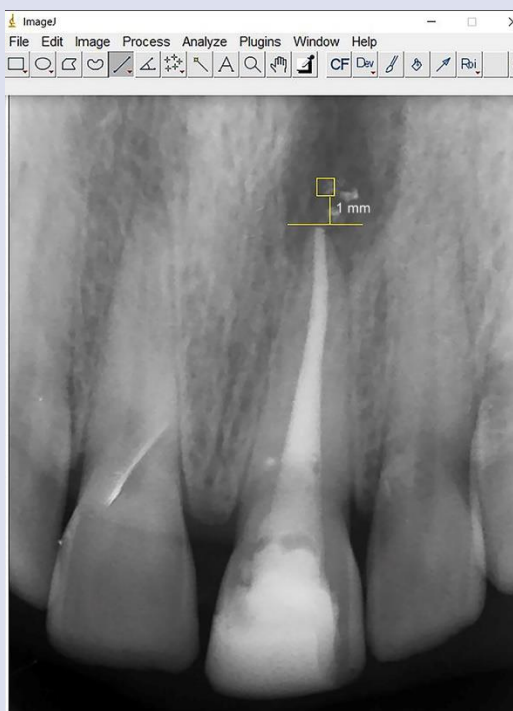

Figure 1: A square-shaped ROI of 30x30 pixels was placed in the geometric center of the apical lesion and 1 mm more apical than the root of the tooth.




Figure 2: The process of fractal analysis, (A) cropped ROI, (B) blurred image of duplicated ROI, (C) subtraction of blurred image from the original image, (D) grey value of 128 to each pixel was added, (E) threshold, (F) binary, (G) erode, (H) dilate, (I) invert, and (J) skeletonize.

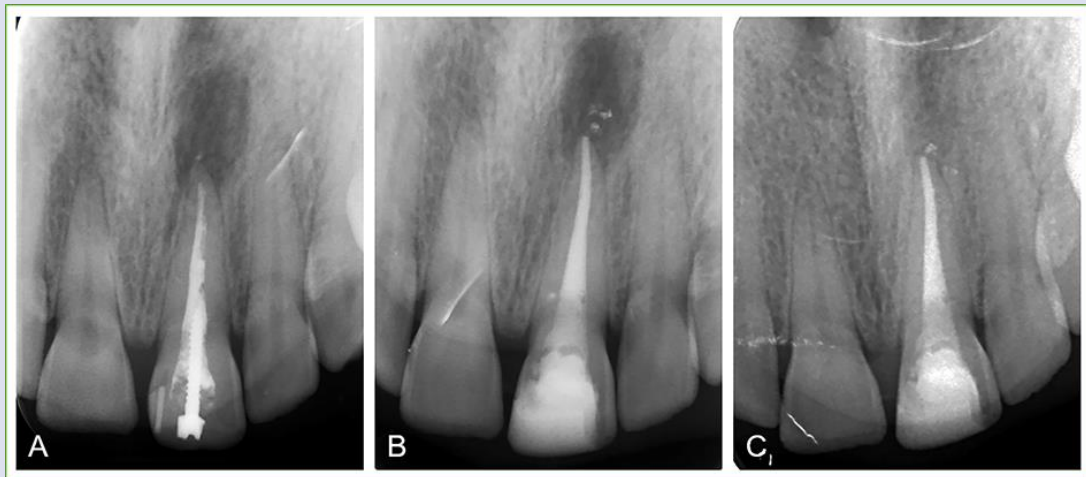


Figure 3: Radiographic evaluation of a case. (A) diagnostic periapical radiograph, PAI 4 (B) periapical radiography taken immediately after retreatment, PAI 4 (C) 1-year follow-up periapical radiograph, PAI 1.