



## Rehabilitation of Aramany Classification I Defect on a Completely Edentulous Patient: A Clinical Case Report

PI Ranganayakidevi S Palaniappan<sup>1,a</sup>

<sup>1</sup> Department of Restorative Dentistry, Faculty of Dentistry, University Malaya, Malaysia.

### Case Report

#### History

Received: 05/06/2021  
Accepted: 27/09/2022

### ABSTRACT

This clinical case report describes a prosthetic rehabilitation for a patient who had partial maxillectomy surgery following the diagnosis of maxillary squamous cell carcinoma in 1991. She was also previously diagnosed with parotid gland pathology on the right and required complete removal of gland along with facial nerve. Her previous prosthesis is 18 years old and claims it not as retentive as before. Intraorally there was a large oval shaped defect on the right side of the maxilla sparing the left alveolus. Defect extends more than 2/3rd of the palatal area with communication to the nasal floor. Presence of buccal frenal pull on the right side on the upper and lower jaws due to the wound contracture on that side of the face. The extraoral facial asymmetry and weakness of facial muscles in this patient may lead to improper denture border seal of the prosthesis. Patient was provided with maxillary acrylic obturator and mandibular acrylic complete denture as a definitive treatment with careful denture extension planning. She was reviewed multiple times till prosthesis stability intraorally was achieved. This improved the prognosis for this patient. The only option for retaining prosthesis in this case, without implants, is optimum engagement of the available soft-tissue undercuts found within the defect space and the non-affected side.

**Keywords:** Completely Edentulous, Obturator, Facial Nerve, Prognosis, Case Report.

## Tam Dişsiz Bir Hastada Aramany Sınıflandırma I Defektinin Rehabilitasyonu: Klinik Bir Vaka Sunumu

### Süreç

Geliş: 05/06/2021  
Kabul: 27/09/2022

### Öz

Bu klinik vaka raporu, 1991 yılında maksiller skuamöz hücreli karsinom tanısı ile parsiyel maksillektomi ameliyatı olan bir hastanın protetik rehabilitasyonunu anlatmaktadır. Daha önce sağda parotis bezi patolojisi teşhisi konmuş ve fasiyal sinir ile birlikte bezin tamamen çıkarılmasını gerektirmiştir. Önceki protezi 18 yaşında ve eskisi kadar kalıcı olmadığını iddia ediyor. Ağız içinde sol alveolü koruyan maksillanın sağ tarafında oval şekilli büyük bir defekt vardı. Defekt, nazal tabanla iletişim ile damak bölgesinin 2/3'ünden fazlasına uzanır. Yüzün o tarafındaki yara kontraktürü nedeniyle üst ve alt çenelerde sağ tarafta bukkal frenal çekme varlığı. Bu hastada ağız dışı yüz asimetrisi ve yüz kaslarının zayıflığı, protezin uygunsuz protez kenar sızdırmazlığına neden olabilir. Hastaya dikkatli protez uzatma planlaması ile kesin tedavi olarak maksiller akrilik obtüratör ve mandibular akrilik tam protez verildi. Ağız içinde protez stabilitesi sağlanana kadar defalarca gözden geçirildi. Bu, bu hasta için prognozu iyileştirdi. Bu durumda implant olmadan protezi sabitlemek için tek seçenek, defekt alanı ve etkilenmeyen taraf içinde bulunan mevcut yumuşak doku alt kesiklerinin optimum şekilde bağlanmasıdır.

**Anahtar Kelimeler:** Tamamen Dişsiz, Obturator, Yüz Siniri, Prognoz, Olgu Sunumu.

### License



This work is licensed under  
Creative Commons Attribution 4.0  
International License

<sup>a</sup> [ranganayaki@msn.com](mailto:ranganayaki@msn.com)

<sup>id</sup> <https://orcid.org/0000-0002-3031-5287>

**How to Cite:** Palaniappan PRS. (2022) Rehabilitation of Aramany Classification I Defect on a Completely Edentulous Patient: A Clinical Case Report, Cumhuriyet Dental Journal, 25(3): 285-289.

## Introduction

Functional rehabilitation for a totally edentulous patient with a maxillary palatal defect may be a clinical challenge. Additionally, to understanding the basics of fabricating a functional complete denture, the dentist also must understand the physiology to modify the extension and design of the prosthesis. Only then, it can fulfil all the specified oral functions and improve the prognosis of the treatment provided.

Surgical consequences of the tumour removal will end in the patient having hypernasal speech, fluid leakage into the nasal cavity, impaired masticatory function, facial asymmetry and cosmetic deformity. Management of the patient becomes slightly harder if the patient also has seventh cranial nerve removal. In such cases, patients may present with striated muscle paralysis, weakness or twitching of the face on the affected side. In this case, the patient had maxillary squamous cell carcinoma and salivary gland pathology. Following this, she had partial maxillectomy and complete removal of the salivary gland together with the cranial nerve. This caused the patient to possess muscle weakness on the concerned side. Since the resection was done in the anterior midline region, this patient is assessed as Aramany Class 1.

Surgical reconstruction in comparison to obturator prosthesis being provided has shown to provide a more robust quality of life and performance to the patient.<sup>1</sup> Patients who undergo surgical management often undergo postoperative complications such as graft rejection, repeated surgeries, and psychological impact.<sup>2</sup> As an alternate, simple prosthetic management is an option. Management of this patient was done conventionally without any auxiliary retentive components like dental implants or surgical procedure. It demonstrates

that with a correct extension of the prosthesis, retention are often well achieved. The prosthesis used to rehabilitate the maxillary defects are generally remarked as an 'obturator'.<sup>3</sup>

## Case Report

A 78-year-old Chinese female was referred to the Prosthetic Clinic of the University of Malaya. She complains of a loose maxillary denture. The patient was diagnosed with maxillary squamous cell carcinoma in 1991 at Hospital Kuala Lumpur, Malaysia. There was partial maxillectomy surgery performed then and was provided with a maxillary obturator. She does not have a lower prosthesis. Currently, the maxillary obturator is not as retentive as before. Her prosthesis is 18 years old with under extended borders and worn off denture teeth. Since she does not have a lower denture, the patient is unable to eat well. Due to this, she frequently has indigestions and loss of weight. There is a previous history of some parotid gland pathology on the right side for an unknown reason. The entire gland was removed along with the facial nerve. This resulted in the eye on the affected side being unable to blink, thus patient uses, moisturizing eye drops.

Extraoral (Figure 1), there was severe wound contraction on the right side of the face that caused the facial asymmetry. The patient also presented with depressed and unsupported upper and lower lips. There was overclosure of the lower to the right side at rest when not wearing the prosthesis. Deviation when opening and closing of mouth was noted. The patient had a convex facial profile. She was unable to blink her right eye and also presented with hypoesthesia over the right infra-orbital, nasal and upper lip region.

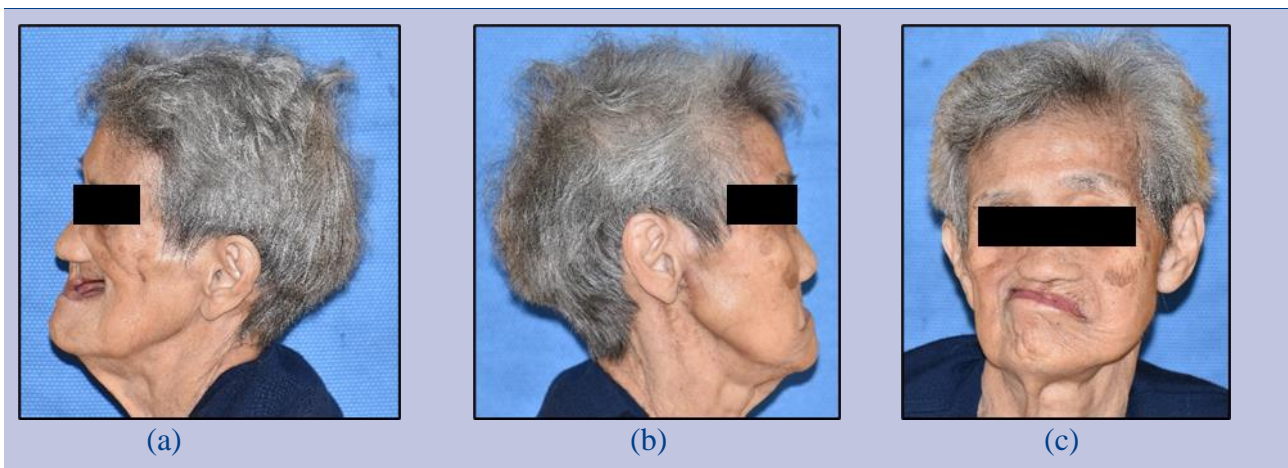


Figure 1. Extraoral pictures of patient without prosthesis: Right lateral view (a), Frontal view (b), Left lateral view (c).

Intraorally (Figure 2), a large oval-shaped defect on the right side of the maxilla sparing the left alveolus. Defect extends more than 2/3rd of the palatal area with communication to the nasal floor. Presence of buccal frenal pull on the right side due to the extraoral wound contracture on that side of the face. Well defined alveolar ridge and retromolar region on the left side. Completely edentulous

maxilla and mandible. Diagnosis for this patient is (i) Maxilla: Aramany Class I defect with completely edentulous arch, (ii) Mandible: Completely edentulous arch.

The aim of the treatment for this patient is (i) Function, (ii) Mastication, (iii) Aesthetic, and (iv) Speech. Thus, maxillary acrylic hollow bulb obturator opposing mandibular removable acrylic complete denture was

planned. She preferred simple, treatment with lesser appointments and the most conventional treatment. The patient was fully informed about the treatment and written consent was taken before treatment procedures.

Preliminary model prepared for maxilla and mandible prepared using a stock tray. Before the impression, the maxillary defect was covered with gauze. The impression compound was used and washed with irreversible hydrocolloid (Kromopan, Lascod, Illinois, USA) (Figure 3). The impressions were poured with type III dental stone (Elite Rock, Zhermack SpA, Via Bovazecchino, Badia Polesine, Italy) to produce casts.

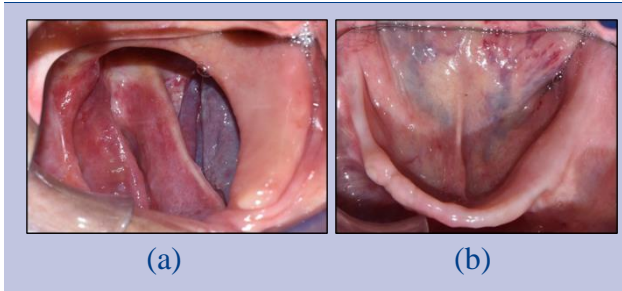


Figure 2. Intraoral view (a) maxilla, (b) mandible.




Figure 3. Maxillary (a) and mandibular (b) primary impression.

Custom tray fabricated for maxilla and mandible with one-layer wax spacer and light-cured base plate material. The extension of the tray was checked intraorally and adjusted accordingly. The defect on the maxilla was again covered with gauze and attached to dental floss before secondary impression making. Border moulding with greenstick compound (Peri Compound GC) for the maxilla and mandible including the defective side (Figure 4). Regular body silicone material (Imprint™ 3 VPS Impression Material) was used for impression making. Impressions were poured with type III dental stone (Elite Rock, Zhermack SpA, Via Bovazecchino, Badia Polesine, Italy) to produce secondary casts (Figure 5). The maxillary and mandibular records were registered and transferred onto the semi-adjustable articulator (Protar ev0 5, Kavo, Illinois, USA).

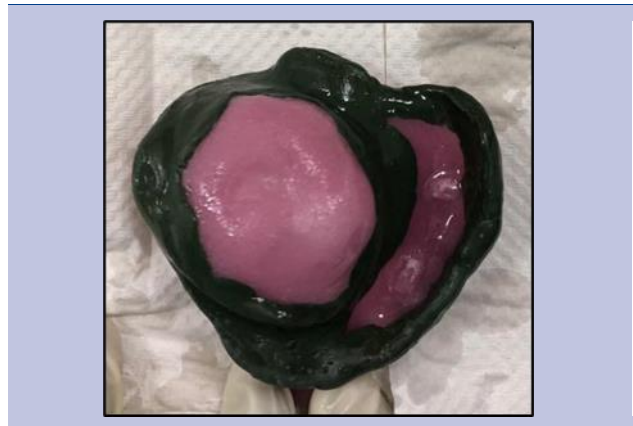

Figure 4. Maxillary (a) and mandibular (b) primary impression.




Figure 5. Maxillary (a) and mandibular (b) secondary cast.

Following the clinical trial fitting appointment, the proceeding step for processing the prosthesis was done. The maxillary obturator prosthesis was processed as a closed hollow bulb. The palatal part of the prosthesis cut was cut open (Figure 6). Later the sulcus and teeth portion were waxed-up and secured. At the defect site; the fitting surface was waxed up. The cover lid at the palate was also waxed-up separately following the piece that was cut out previously. Both the separate parts were processed individually and later the bulb and lid portions were joined using the auto-polymerizing resin. The mandibular prosthesis was fabricated with the conventional denture processing method.

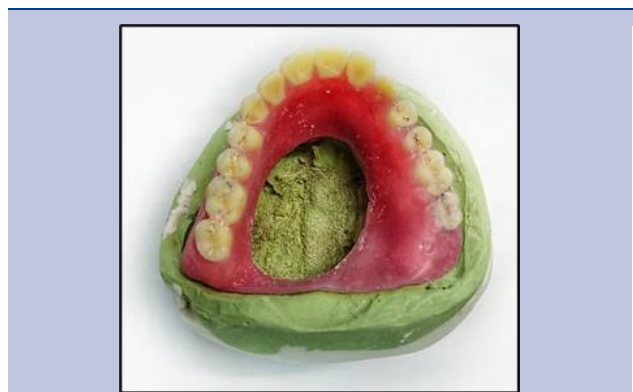

Figure 6. The palatal portion of the prosthesis is cut open before wax-up of the bulb portion.

In the consecutive appointment, a prosthesis was issued to the patient. The fitting surfaces of the prosthesis were checked with a fit checker and were adjusted accordingly. Occlusion and posterior extension were verified (Figure 7,8). The frenal full on the right mandibular area was causing the prosthesis to be lifted. The extension was checked multiple times till the prosthesis was stable. Before leaving, the patient was given postinsertion instructions for the prosthesis. The patient was reviewed 1-week post-insertion. During the review, the patient was asked to drink with the prosthesis

intraorally to access any leakage of fluid. Phonetics and occlusion were also reassessed multiple times. Oral hygiene instructions were reinforced to the patient. The patient's voice was clearer and more understandable. Facial profile of the patient improved to straight.

The prognosis of the treatment provided is considered good. The patient was happy with the treatment outcome; oral hygiene was good. Since the maxillary and mandibular prostheses were stable and retentive, the patient could use the prosthesis well.

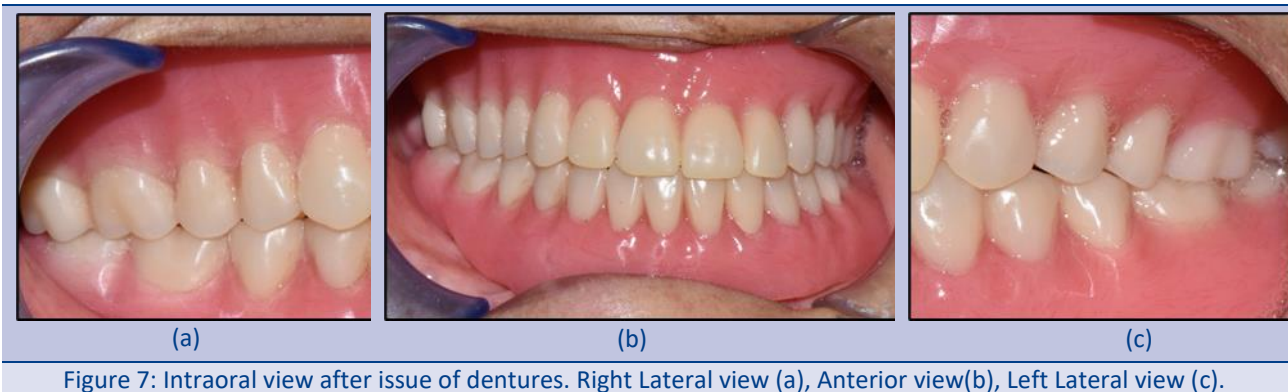


Figure 7: Intraoral view after issue of dentures. Right Lateral view (a), Anterior view (b), Left Lateral view (c).

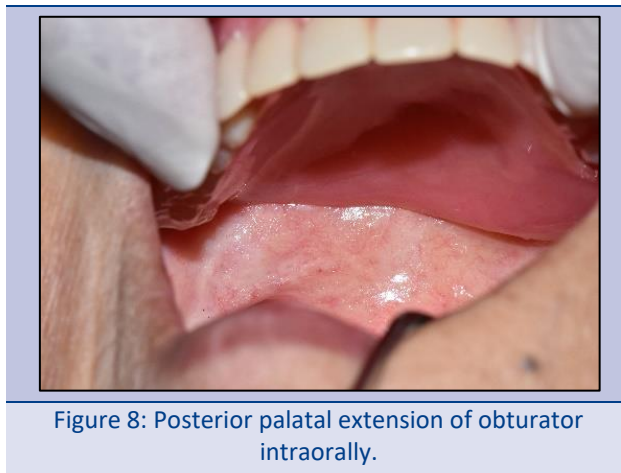


Figure 8: Posterior palatal extension of obturator intraorally.

**Discussion**

Successful denture therapy for a completely edentulous patient is influenced by the biomechanical phenomena of retention, stability and support.<sup>4</sup> In this case, the stability and support of the maxillary obturator are compromised because of the defect which is at the primary stress-bearing area; the hard palate. Both within the maxilla and also the mandible, there's a buccal frenal pull that disrupts the peripheral seal. Overclosure and wound contraction on the affected side causes the denture to lift easily. This compromises the retention of the prosthesis. Thus, external denture contours were critical.<sup>5</sup> Conversely, poorly designed prostheses that don't accommodate anticipated muscular function may yield compromised denture stability and reduced retention.

Adjustment of the denture flanges that are over-extended is mandatory. The patients' hypesthesia, may lead to ulcers but might not present any pain in the slightest degree. Visualizing the denture extension into the

sulcus are often difficult clinically. Pressure indicating paste is used during the review. After drying the denture border within the area being evaluated, the paste was placed and so carefully seated intraorally. Once seated, the denture was held border moulding movements were performed. Overextended borders had the materials removed. These areas were marked and so trimmed with a carbide bur. Finally smoothed and polished before giving it to the patient.

After adjustments to the denture fitting surfaces to be more stable, the patient can manage the prosthesis well despite the lack of any retentive components and also the large defect site. Since this patient is an obturator wearer for over 18 years, she knows well the way to manage the prosthesis. The patient's ability to manage dentures involves a learning process that, initially, could be a conscious endeavour. As a result of repetition, new reflex arcs are founded within the central systema nervosum and also the conscious effort has been replaced by a

subconscious behaviour pattern. Constant repetition of impulses lowers the synaptic resistance and facilitates the formation of conditioned reflexes. At the identical time, however, it must be realised that the synaptic resistance are increased within the absence of those repeated stimuli.<sup>6</sup>

This obturator prosthesis incorporates a hollow bulb that's light but bulky. Besides fully engaging the undercuts within the defect with the bulb within the prosthesis, the treatment outcome is restricted because of the path of insertion that becomes complicated. A vital point to notice is that the weight of the prosthesis will cause loss of restraint and also to the propelling forces intraorally.<sup>7</sup> the employment of endosseous dental implants will further improve the prognosis for completely edentulous patients. Individuals wearing implant-assisted prostheses typically report improved oral comfort and function in comparison to conventional, mucosa-supported prostheses.<sup>8</sup> Using Zygomatic Implant in the edentulous maxillary defect was found more advantageous, in terms of compression and tensile stress and retention, when compared with conventional dental Implant.<sup>9</sup>

Except when contraindicated due to financial or surgical considerations, implant-assisted overdentures are usually the treatment of choice. During this case, although the patient understands the advantages of implant-supported prosthesis she isn't interested and only prefers a non-invasive conventional treatment.

## Conclusions

With careful planning of denture extensions is executed; along with good impression making and proper fitting of dentures within the anatomical limits, an overall satisfactory treatment outcome can be achieved. A good knowledge understanding of the patients' needs would enable the successful rehabilitation and a comprehensive management.

## Acknowledgement

This study has not been supported by any funding. This case was done as part of the Masters in Clinical Dentistry

Programme offered by the University of Malaya as a requirement. The contribution of the clinical supervisor, Senior Lecturer Dr Siti Fauzza Binti Ahmad, Department of Restorative Dentistry, University Malaya is highly appreciated. The author declares that there is no conflict of interest. Written and informed consent had been taken from the patient for publication.

## References

1. Aladashi OQ, Shindy MI, Noaman SA, Alqutaibi AY, Refahee SM. Effect of submental flap reconstruction versus obturator rehabilitation after maxillectomy on quality of life: a randomized clinical trial. *International Journal of Oral and Maxillofacial Surgery*. 2021 Sep 1;50(9):1156-1160.
2. Mishra A, Mohamed K, Kumar P, Jayagandhi SK. Prosthetic Rehabilitation of Maxillectomy Defects, with Single-Piece Open-Hollow Bulb Definitive Obturator. *Journal of Evolution of Medical and Dental Sciences*. 2021 Apr 19;10(16):1169-1174.
3. Fadhil SM, Mumcu E. Rehabilitation of a patient with palatal defect-A case report. *Journal of Surgery and Surgical Research*. 2019 Nov 23;5(2):093-096.
4. Jacobson TE, Krol AJ. A contemporary review of the factors involved in complete denture retention, stability, and support. Part I: retention. *The Journal of prosthetic dentistry*. 1983 Jan 1;49(1):5-15.
5. Cagna DR, Massad JJ, Schiesser FJ. The neutral zone revisited: from historical concepts to modern application. *The Journal of prosthetic dentistry*. 2009 Jun 1;101(6):405-412.
6. Pandey A. Factors Related to Patient Expectation and Satisfaction among New and Existing Denture wearers with Complete Denture therapy. *Journal of Nepalese Prosthodontic Society*. 2020 Jul 1;3(2):86-91.
7. Bholra RD, Pisulkar SG, Godbole SA, Purohit HS, Borle AB. Maxillofacial Prosthesis for Combined Intra and Extra-Oral Defect--A Case Report. *Journal of Evolution of Medical and Dental Sciences*. 2021 Feb 22;10(8):550-555.
8. Gowda ME, Mohan MS, Verma K, Roy ID. Implant rehabilitation of partial maxillectomy edentulous patient. *Contemporary clinical dentistry*. 2013 Jul;4(3):393.
9. Mousa MA, Abdullah JY, Jamayet NB, Alam MK, Husein A. Biomechanical stress in obturator prostheses: a systematic review of finite element studies. *BioMed research international*. 2021 Aug 17;2021.